

Colon Cancer in Pregnancy

Alex Minter, MD, Rohit Malik, MD, Leslie Ledbetter, RN, Thomas S. Winokur, MD, Mary T. Hawn, MD, and M. Wasif Saif, MD

Introduction

Colorectal cancer in pregnancy is rare, with a reported incidence of 0.002%.¹ Approximately 275 cases of colon cancer associated with pregnancy have been reported in the literature.² A review of 205 of these cases performed by Bernstein et al³ demonstrated that 85% of these cancers were located below the peritoneal reflection. The symptoms of colorectal cancer include nausea, vomiting, abdominal pain, altered bowel movements, and rectal bleeding. Since these symptoms are commonly found in the pregnant population as a whole, physicians and patients usually attribute them to the usual manifestations of pregnancy without an appropriate evaluation. The delay in initiating the workup for the symptoms related to colorectal cancer is a major contributing factor to the poor prognosis associated with this disease.⁴ We present another case of colorectal cancer located below the peritoneal reflection that was diagnosed at an advanced stage.

Case Report

A 28-year-old woman complained of intermittent rectal bleeding that persisted throughout her pregnancy. She also experienced some lower abdominal pain and constipation. She was initially evaluated by her primary physician, who attributed the symptoms to hemorrhoids. Due to the persistent bleeding, she sought a second opinion from a gastroenterologist who performed a flexible sigmoidoscopy. The endoscopic evaluation revealed an ulcerated mass located 12 cm from the anus, and the biopsy confirmed a moderately differentiated adenocarcinoma (Fig 1). The patient had a 16th-week intrauterine pregnancy at that time and was subsequently referred to the oncology clinic for further management. There was no

family history of colorectal, endometrial, breast, or ovarian cancers. The physical examination at that time was unremarkable except for normal signs of pregnancy and pallor. The patient was anemic at the time of presentation, with a hemoglobin level of 9.7 g/dL and a hematocrit measure of 28%. Other laboratory data, which included liver function tests, carcinoembryonic antigen (CEA) assessment, and a basic chemistry panel, were within normal limits. An abdominal ultrasound revealed a 1-cm hypoechoic lesion in the liver that was consistent with a cyst. She was immediately evaluated by an oncologic surgeon who thought that her pregnancy would make surgery more technically difficult and that her ability to receive prompt adjuvant therapy would be compromised. Another concern was whether this was a distal or mid sigmoid lesion. In discussions with a radiologist, it was decided that if it was a sigmoid lesion and her uterus was mobile, we would be able to reflect it and expose the sigmoid colon for resection. If it was not a sigmoid lesion or if the uterus was immobile, two procedures would be necessary: first termination of the pregnancy and then tumor resection.

To help determine the exact location of the tumor, a computed tomography (CT) scan was performed by reducing the dose of radiation and using rectal contrast. This demonstrated a lesion at the rectosigmoid junction

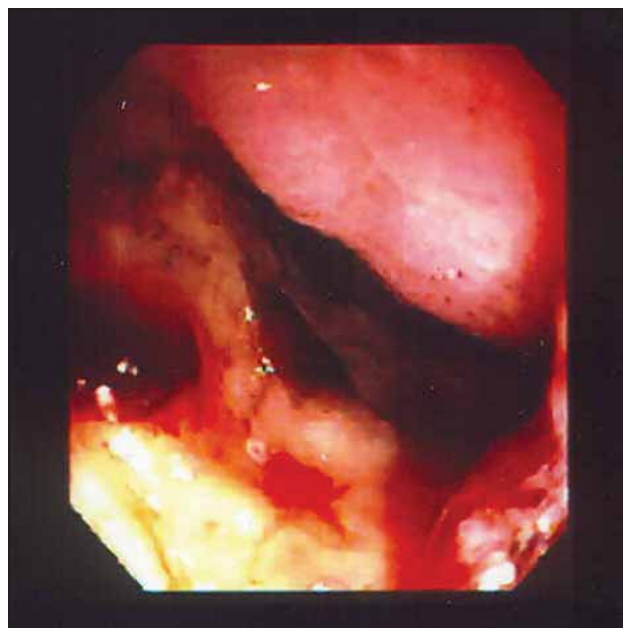


Fig 1. — The endoscopic evaluation of our patient revealed an ulcerated mass located 12 cm from the anus, and the biopsy confirmed a moderately differentiated adenocarcinoma.

From the University of Alabama at Birmingham (AM, LL, TSW, MTH, MWS), and the Medical Center East, Trussville, Alabama (RM).

Submitted April 5, 2004; updated February 4, 2005; accepted February 8, 2005.

Address correspondence to M. Wasif Saif, MD, 223 Wallace Tumor Institute, 1530 3rd Avenue South, Birmingham, AL 35294-3300. E-mail: wasif.saif@ccc.uab.edu

No significant relationship exists between the authors and the companies/organizations whose products or services may be referenced in this article.

Abbreviations used in this paper: CEA = carcinoembryonic antigen, CT = computed tomography, HNPCC = hereditary nonpolyposis colon cancer, MSI = microsatellite instability.

with adjacent lymphadenopathy and two 1-cm cysts in the liver. No additional evidence of metastatic disease was found. The cancer was just posterior to the cervix and clearly in the midline position. Due to these findings, termination of her pregnancy was recommended.

In addition, CT scan revealed significant nodal disease that was suspicious for tumor involvement. This identified her disease as stage III, and the decision was made to use adjuvant chemotherapy and, depending on the relationship to the rectal sigmoid junction, adjuvant radiation therapy. As she was only 16 weeks pregnant at the time, delaying her adjuvant therapy by another 4 months while she carried her child until a viable stage would lead to further progression of cancer. In consultation with an obstetrician, an oncologic surgeon, and a medical oncologist, she elected to terminate the pregnancy. She underwent a low anterior resection with coloproctostomy by an oncologic surgeon approximately 2½ weeks after terminating the pregnancy. This allowed her uterus to return to a normal size and the pelvic venous congestion related to pregnan-

cy to decrease. Macroscopic examination revealed an annular firm, solid, tan to red-brown lesion (6.6 × 5.5 cm) with a raised border and a larger area of central ulceration. The lesion was located 2.6 cm from the distal rectal margin and 13.5 cm from the proximal colonic margin. Extension through the bowel wall and into the pericolonic fat was noted. The microscopic examination revealed a moderately differentiated adenocarcinoma extending entirely through the bowel wall into the pericolonic fat. Five of the nine lymph nodes removed during surgery were positive for metastatic disease. Tumor cells were estrogen receptor-negative (ER-) and progesterone receptor-negative (PgR-) (Fig 2). Cox-2 expression by immunohistochemistry staining was positive. Her disease was classified as a stage III/Dukes C (T3, N2, M0). She received adjuvant chemotherapy 2 weeks after surgery, consisting of two cycles of the Mayo regimen (5-fluorouracil 425 mg/m² per day and leucovorin 20 mg/m² per day on days 1-5 of a 28-day cycle) followed by 28 days of continuous infusion of 5-fluorouracil 225 mg/m² per day with concurrent pelvic radiotherapy (25 fraction at 1.8 Gy, total dose of 50.4 Gy), and then two additional cycles of the Mayo regimen. The patient tolerated the therapy well with minimal hematologic and nonhematologic toxicities. She remained in remission for 11 months. A follow-up CT scan at a 3-month follow-up showed new left para-aortic lymph node at the level of renal vein (1.2 × 1.4 cm). Positron emission tomography scan confirmed the malignancy, and chemotherapy consisting of an oxaliplatin-based regimen (XELOX and bevacizumab) was administered. Following four cycles, she achieved a complete response. She received four more cycles after that. Currently, she is taking bevacizumab alone and remains in remission.

The patient was referred to the Cancer Genetics Clinic for consultation. They believed that hereditary non-polyposis colon cancer (HNPCC) could be considered because of the patient's young age at diagnosis. However, the family history was not striking. The family did not meet Amsterdam II criteria for HNPCC. The patient met Bethesda criteria for microsatellite instability (MSI) testing because of her young age at diagnosis. The tumor would first be examined for MSI. If the MSI testing was positive, the genetic testing of the three genes associated with HNPCC would proceed. Once a mutation was identified in the family, other family members could consider predictive testing.

Discussion

In women of childbearing age, cancer represents one of the major causes of death.⁵ The incidence rate of cancer in pregnancy reported in the literature ranges from 0.07% to 0.1%.⁶ The incidence rate of colorectal cancer in pregnancy is 0.002%.¹ The most common malignancies in pregnancy include lymphoma, leukemia, melanoma, carci-

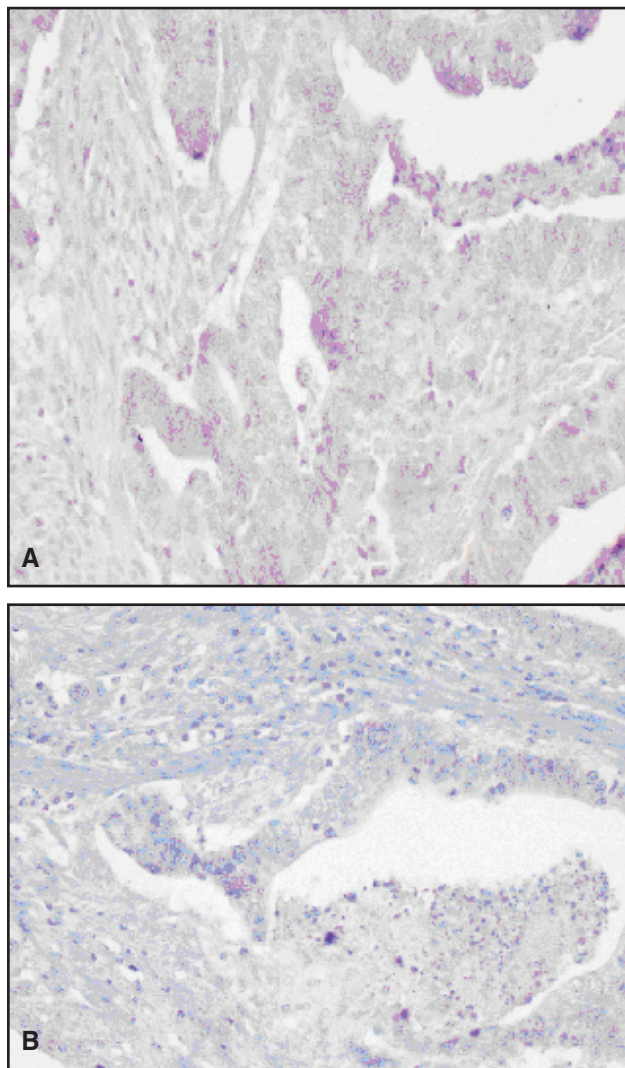


Fig 2. — Tumor cells in our patient were estrogen receptor-negative (A) and progesterone receptor-negative (B).

noma of the breast, and cervical, ovarian, thyroid, and colorectal cancer.⁷ A mean age of 31 years (range 16 to 48) was reported in a review of 42 pregnant patients with colon cancer.³

Colorectal cancer in pregnancy represents a serious threat to both the mother and the fetus. Woods et al⁸ reported that only 25 of 32 pregnancies in women with colorectal tumors resulted in healthy, live-born infants. Prematurity, intrauterine death, stillbirth, and termination were all contributors to death in these infants.

Common presenting signs and symptoms of colon cancer include abdominal pain, anemia, nausea, vomiting, and rectal bleeding. Because these signs and symptoms are also frequently found in pregnancy, physicians and patients often attribute them to the usual complications of pregnancy.⁶ The diagnostic challenge for clinicians is distinguishing pregnancy symptoms from the warning signs of colorectal cancer (Table 1).² Clinicians must be aware of these potential warning signs and symptoms in order to make the diagnosis at an early stage of disease. Rectal bleeding is particularly ominous sign and should never be attributed solely to pregnancy without a proper evaluation. Delays in diagnosis lead to advanced stages of cancer and may contribute to the poor prognosis associated with this disease. A review of 39 cases by Bernstein et al⁵ demonstrated that all of the patients with colorectal cancer in pregnancy presented with Dukes class B or greater disease. The breakdown per stage was Dukes class A, 0 (0%), Dukes class B, 16 (41%), Dukes class C, 17 (44%), and Dukes class D, 6 (15%).

Colorectal cancer occurs rarely in young patients, and as a result, this patient population is more likely to have strong predisposing factors compared to the general population of patients with colon cancer.⁹ Such predisposing factors for colon cancer include hereditary nonpolyposis colorectal cancer (Lynch syndrome), familial adenomatous polyposis, Gardner's syndrome, Peutz-Jeghers syndrome, and long-standing inflammatory bowel disease. However, these increased risk groups represent only a small portion of colorectal cancers diagnosed in pregnancy.² A review

of 19 pregnant patients by Girard et al¹ demonstrated that 4 of 19 patients had one of these strong predisposing factors for colon cancer.

The carcinogenesis of colorectal cancer is not fully understood. The hypothesis that ER and PgR may be involved in the pathogenesis of colorectal cancer during pregnancy has been studied. Several studies have reported the presence of ERs in colon cancer.¹⁰⁻¹² It has been suggested that as many as 20% to 54% of colon tumors have ERs.¹³ Studies have also demonstrated the presence of PgRs in colon cancer.¹⁴ A study by Geelhoed et al¹⁵ reported that 42.8% of colon tumors were PgR+. These findings suggest that increased levels of estrogen and progesterone found in pregnant women could stimulate the growth of colorectal cancers that have these receptors. Stimulation of these receptors could also help to explain the advanced stages found in the majority of patients at the time of diagnosis. However, it is important to note that the data to support the role of these receptors in the pathogenesis of colorectal cancer are scarce and that conflicting data exist in the literature regarding ERs and PgRs in colorectal cancer. In a recent study by Slattery et al,¹⁵ only one PgR+ tumor and no ER+ tumors were found in an analysis of 156 women diagnosed with colorectal cancer. The tumor described in our case was analyzed and was ER- and PgR-.

The role of Cox-2 enzymes in colorectal cancer and pregnancy has also been studied. Lim et al¹⁶ investigated the role of enzymes in the early stages of pregnancy and found it to be vital for each stage of pregnancy. Cox-2 products appear to be essential for the early sequences of pregnancy, including ovulation, fertilization, implantation, and decidualisation.¹⁷ The early events of pregnancy and the pathogenesis of tumor spread have important similarities: both events require cells to migrate from the site of origin to another site at which these cells must establish new vasculature to grow and mature.¹⁷ Cox-2 enzymes are found in high levels in many colorectal tumors cells.¹⁸ Studies have also demonstrated that Cox-2 inhibitors such as aspirin can alter the course of colon cancer.¹⁹ Increased

Table 1. — Commonly Confused Signs, Symptoms, and Laboratory Results Between Pregnancy and Colorectal Cancer

Signs, Symptoms, Laboratory Results	Normal Pregnant Patient	Pregnant Patient With Colorectal Cancer
Weight loss	In general, weight gain, but women can experience weight loss in 1st trimester	Pregnancy can obscure weight loss secondary to cancer, primarily in 2nd and 3rd trimesters
Rectal bleeding	Common in pregnancy secondary to high incidence of hemorrhoids	Often attributed to hemorrhoids without pursuing appropriate workup
Nausea and vomiting	Common in pregnancy, particularly during 1st trimester	Often attributed to pregnancy, delaying workup
Constipation	Common in pregnancy	Often attributed to pregnancy, delaying workup
Abdominal mass	Natural process in pregnancy	Potential palpable masses secondary to colon cancer often missed secondary to changes of pregnancy
Anemia	Physiologic finding in pregnancy	Anemia of pregnancy masks blood loss from cancer

Reprinted from *Gastroenterology Clinics of North America*, Vol 27: 225-256. Cappell MS, Colon cancer during pregnancy: the gastroenterologist's perspective. Copyright 1998 with permission from Elsevier.

levels of Cox-2 enzymes in pregnant patients could play a role in the pathogenesis and prognosis of colorectal cancer in pregnancy. However, no studies have been performed to date to explore this potential relationship. Cox-2 was positive in our patient by immunohistochemical testing of the tumor specimen.

The diagnostic evaluation of a patient with colorectal cancer involves three major components: endoscopy with biopsy, serum CEA, and abdominal imaging (Table 2).^{2,20} Colonoscopy is performed in nonpregnant patients in order to make the pathologic diagnosis of colorectal cancer. Possible adverse consequences of performing endoscopy in pregnant patients include fetal exposure to potential teratogenic medications, placental abruption from mechanical pressure applied to the uterus, and fetal injury secondary to maternal hypoxia or hypotension during the procedure.^{21,22} Colonoscopy in pregnancy is a relative contraindication, and the patient should be fully informed of the possible maternal and fetal risks.³ Measures used to improve the safety of endoscopy in pregnant patients include gentle abdominal compression during colonic intubation and the use of meperidine rather than diazepam and midazolam because of its safer fetal profile.² Also, oxygen should be administered to the pregnant patient during endoscopy to decrease potential risks of hypoxia from sedation during endoscopy.²³ Fetal cardiac monitoring should be considered to detect potential distress to the fetus during the procedure.²⁴

Serum CEA is an important laboratory test used in the evaluation of pregnant and nonpregnant patients. CEA levels during pregnancy are usually normal but may be slightly elevated.²⁵ CEA levels obtained prior to surgery provide a baseline to monitor the response to treatment. CEA levels also have prognostic value since increased levels prior to surgery are associated with disseminated disease and increased recurrence rates.²⁶ However, CEA is not useful as a tool for screening due to the low sensitivity and specificity.²⁶

Abdominal CT imaging is contraindicated in pregnancy due to radiation teratogenicity, particularly in the first trimester.^{27,28} In nonpregnant patients, an abdominal CT scan can be useful in staging the cancer. Surgical management and prognosis are primarily determined by the extent of local disease and presence of hepatic metastases. An abdominal ultrasound is an alternative to abdominal CT imaging in pregnant patients; this is useful in evaluating the presence of hepatic metastasis and has a sensitivity of 75% for detecting macrometastatic lesions.^{29,30} Magnetic resonance imaging (MRI) appears to be safer than CT in pregnancy, although experience in using MRI is limited.³¹

The goals of treatment are to start therapy for the mother as early as possible and to deliver the baby as early as possible. The limiting factor in the delivery of the baby is lung maturity. Delivery of a viable infant can occur at 32 weeks of gestation if the lungs are properly stimulated to mature. Resection of the colorectal cancer at the time of delivery can be considered if a Caesarian section is performed. However, the resection can be postponed for several weeks to allow for the involution of the uterus and resolution of vascular engorgement of pregnancy.⁶

The complex treatment of colorectal cancer in pregnancy is based on the gestational age of the fetus, tumor stage, and need for emergent vs elective surgery. If the diagnosis occurs in the first half of pregnancy (at less than 20 weeks), significant tumor progression may occur if surgery is delayed until the fetus is viable; thus, the clinician should recommend termination of the pregnancy and proceed with resection of the tumor.⁶ If the diagnosis is made in the second half of pregnancy (more than 20 weeks), resection could be delayed until after the infant is delivered. Following the birth, the patient can be treated in the same manner as a nonpregnant patient.⁶ However, waiting until after the birth poses risks to the mother, and she should be fully informed of these risks prior to making the decision. These treatment guidelines apply to both colon and rectal cancers. Hysterectomy is indicated in rec-

Table 2. — Comparison of Laboratory Results, Images, and Therapies in Pregnant and Nonpregnant Patients

Test/Image/Treatment	Nonpregnant Patient	Pregnant Patient
Carcinoembryonic antigen level	Used as prognostic indicator and as a baseline to follow for recurrence after resection	Helpful for prognostic reasons and to detect recurrences; level not affected by pregnancy
Abdominal computed tomography scan	Standard for staging purposes	Contraindicated in pregnancy; ultrasound used instead
Colonoscopy	Essential in obtaining a pathologic diagnosis	Considered a relative contraindication in pregnancy, but endoscopy is essential in obtaining a pathologic diagnosis; patient should be informed of potential risks in pregnancy and consent obtained prior to performing
Adjuvant chemotherapy	Standard for Dukes C cancer	Not used in 1st trimester secondary to potential teratogenic effects of 5-fluorouracil; could consider in 2nd and 3rd trimester if chosen by patient
Adjuvant radiotherapy	Standard for Dukes B2 and C rectal cancer	Contraindicated during pregnancy; used postoperatively only after delivery or elective abortion

Reprinted from *Gastroenterology Clinics of North America*, Vol 27;225-256. Cappell MS, Colon cancer during pregnancy: the gastroenterologist's perspective. Copyright 1998 with permission from Elsevier.

tal cancer if the tumor has invaded the uterus or if the mother's expected length of survival will not allow the fetus to become viable.⁶

Ovarian metastatic disease from colorectal cancer poses another challenge to the treating physician. The incidence of ovarian metastases from colorectal tumors is higher in pregnant patients (25%) than in nonpregnant patients (3% to 8%).^{32,33} The survival of patients with metastasis involvement of the ovaries is poor, in the range of 3 to 12 months.³³ Prophylactic bilateral salpingo-oophorectomy simultaneous with colorectal surgery is recommended by some physicians.^{34,35} However, it is prudent to take into consideration the desire of the patient for future pregnancies. Also, bilateral salpingo-oophorectomy at the time of resection has been linked to an increased incidence of spontaneous abortion, especially if performed during the first trimester.⁴ Nesbitt et al⁴ recommend obtaining bilateral wedge biopsies of the ovaries during surgery for pathologic examination of the frozen sections with subsequent removal if the ovaries are involved.

Adjuvant radiotherapy has a major role in the treatment of Dukes B2 and C rectal cancers. Approximately half of rectal cancers with local extramural extension will recur locally after potential curative resection.³⁶ Radiotherapy was implemented to decrease the rate of local recurrence and to increase survival in patients with extramural extension.³⁷ Radiotherapy can be utilized only if the infant is delivered prior to initiation of radiotherapy. The fetus cannot be shielded from radiotherapy applied to the pelvic wall due to the anatomic relation of the uterus to the colon.⁷ Future fertility should be considered before proceeding with treatment because radiotherapy can cause permanent damage to ovaries and lead to infertility.³⁸ If a woman of childbearing age is considering radiotherapy, she must be informed of this possible outcome and consent must be documented.

The primary chemotherapeutic agent for the treatment of colorectal cancer is 5-fluorouracil (5-FU).³⁹ The use of adjuvant 5-FU administration has been demonstrated to increase the colorectal cancer survival rate by 5% to 10%.^{40,41} Previous studies have demonstrated that 5-FU-based chemotherapy improves survival in patient with Dukes class C cancer who have undergone a potentially curative resection.^{42,43} Thus, pregnant patients with Dukes C colorectal cancer should undergo adjuvant chemotherapy.

The major toxicities of 5-FU-based treatment regimens include gastrointestinal toxicities and alopecia.⁴⁴ The use of 5-FU during pregnancy can have harmful effects on the fetus. Mechanisms by which 5-FU may lead to fetal abnormalities include interrupting DNA synthesis and cell development through inhibition of embryonic thymidylate synthase.⁴⁵ Prior to 1988, there were no reports of subsequent live births after first trimester exposure to 5-FU.⁴⁶ Live births have been reported since that

time,² but the data on such exposure are limited. Chemotherapy is safer if given during the second and third trimesters, after organogenesis is complete.^{4,47} Women diagnosed with Dukes C colorectal cancer in early pregnancy (before 20 weeks' gestation) should consider elective abortion in order to pursue adjuvant therapy. Women diagnosed later in pregnancy can consider delaying adjuvant chemotherapy until after delivery of the infant. However, studies have shown that adjuvant chemotherapy provides significant survival advantage to patients with Dukes C disease when initiated within 5 weeks of resection.^{48,49} Thus, if the patient chooses this option, the physician must make every effort to minimize any delay in surgery by balancing of the needs of the mother with those of the unborn infant. The infant should be delivered at the earliest possible date at which viability is reached, usually around 32 weeks.

The role of newer chemotherapeutic agents such as irinotecan, capecitabine, and oxaliplatin still needs to be explored in this setting. Oxaliplatin and irinotecan are in the Food and Drug Administration's pregnancy category D (ie, they are harmful to an unborn baby). It is not known whether these drugs pass into breast milk.

Colon cancer is a common form of cancer; however, when a young person is affected or when numerous family members have been affected in multiple generations, a common germ-line mutation may exist in the family that predisposes individuals to certain forms of cancer. Given our patient's age at diagnosis (28 years), consideration of HNPCC at this time would have been prudent.⁵⁰ However, the family history was not particularly striking. HNPCC is responsible for 3% to 5% of all colon cancers.⁵¹ As already noted, numerous types of cancers and tumors can be associated with this syndrome. Mutations in one of several mismatch or pair genes are known to be responsible for HNPCC. The mismatch repair genes are responsible for correcting mistakes in the genetic code. HNPCC gene mutations are transmitted in an autosomal dominant pattern; therefore, individuals with a gene mutation have a 50% chance of passing the mutation to each of their children. Because multiple genes are involved and this syndrome is relatively rare, specific criteria should be met prior to proceeding with genetic testing. Our patient's family did not fulfill Amsterdam II criteria for HNPCC, but our patient did meet Bethesda Criteria for MSI testing because of her young age at diagnosis.⁵¹ Initial genetic testing for HNPCC is a multistep process. The tumor is first examined for MSI. Microsatellites are portions of the genetic code that are prone to mutation if the mismatch or pair genes do not function properly. A tumor with a high degree of instability suggests a mutation in one of the mismatch or pair genes associated with HNPCC. If the MSI testing is positive, the genetic testing of the three genes associated with HNPCC will proceed. Once a mutation has been identified in the family, other family members can consider predictive testing.

Pregnant women with colorectal cancer generally have a poor prognosis. In a review of 42 patients with colorectal cancer above the peritoneal reflection, Chan et al⁵² noted that 23 (56%) of these patients died by the time the cases were reported in the literature. Most died within 1 year of being diagnosed, and the median survival for the group was less than 5 months. One patient survived for 3.5 years after bowel resection but had multiple recurrences. No patient with colorectal cancer in pregnancy reported in the literature has survived longer than 5 years.

Conclusions

Colorectal cancer in pregnancy presents a diagnostic and therapeutic challenge. Since the presenting signs of colorectal cancer are easily attributable to the usual symptoms of pregnancy, the diagnosis of colorectal cancer is often delayed until it has progressed to an advanced stage. To diagnose colon cancer earlier in pregnancy and thus improve prognosis in a patient with significant gastrointestinal complaints such as persistent rectal bleeding, a sigmoidoscopy, preferably without endoscopic medications, needs to be performed by a gastroenterologist. Colon cancers in pregnant patients are usually distal and within reach of the sigmoidoscope.

The decisions made in the care of a pregnant patient with colorectal cancer must take into account both the life of the unborn child and the survival of the mother. The treatment regimen requires a multidisciplinary approach involving experts in obstetrics, neonatology, gastrointestinal surgery, and medical oncology.

References

- Girard RM, Lamarche J, Baillot R. Carcinoma of the colon associated with pregnancy: report of a case. *Dis Colon Rectum*. 1981;24:473-475.
- Cappell MS. Colon cancer during pregnancy: the gastroenterologist's perspective. *Gastroenterol Clin North Am*. 1998;27:225-256.
- Bernstein MA, Madoff RD, Caushaj PF. Colon and rectal cancer in pregnancy. *Dis Colon Rectum*. 1993;36:172-178.
- Nesbitt JC, Moise KJ, Sawyers JL. Colorectal carcinoma in pregnancy. *Arch Surg*. 1985;120:636-640.
- Parker SL, Tong T, Bolden S, et al. Cancer statistics, 1997. *CA Cancer J Clin*. 1997;47:5-27. Erratum in: *CA Cancer J Clin*. 1997;47:68.
- Walsh C, Fazio VW. Cancer of the colon, rectum, and anus during pregnancy: the surgeon's perspective. *Gastroenterol Clin North Am*. 1998;27:257-267.
- Doll DC, Ringenberg QS, Yarbro JW. Management of cancer during pregnancy. *Arch Intern Med*. 1988;148:2058-2064.
- Woods JB, Martin JN Jr, Ingram FH, et al. Pregnancy complicated by carcinoma of the colon above the rectum. *Am J Perinatol*. 1992;9:102-110.
- Isbister WH, Fraser J. Large-bowel cancer in the young: a national survival study. *Dis Colon Rectum*. 1990;33:363-366.
- Francavilla A, Di Leo A, Polimeno L, et al. Nuclear and cytosolic estrogen receptors in human colon carcinoma and in surrounding non cancerous colonic tissue. *Gastroenterology*. 1987;93:1301-1306.
- Hendrickse CW, Jones CE, Donovan IA, et al. Oestrogen and progesterone receptors in colorectal cancer and human colonic cancer cell lines. *Br J Surg*. 1993;80:636-640.
- Xu X, Thomas ML. Estrogen receptor-mediated direct stimulation of colon cancer cell growth in vitro. *Mol Cell Endocrinol*. 1994;105:197-201.
- Slattery ML, Samowitz WS, Holden JA. Estrogen and progesterone receptors in colon tumors. *Am J Clin Pathol*. 2000;113:364-368.
- Korenaga D, Orita H, Maekawa S, et al. Relationship between hormone receptor levels and cell-kinetics in human colorectal cancer. *Hepatogastroenterology*. 1997;44:78-83.
- Geelhoed GW, Alford C, Lippman ME. Biologic implications of steroid hormone receptors in cancers of the colon. *South Med J*. 1985;78:252-254.
- Lim H, Paria BC, Das SK, et al. Multiple female reproductive failures in cyclooxygenase 2-deficient mice. *Cell*. 1997;91:197-208.
- Majerus PW. Prostaglandins: critical roles in pregnancy and colon cancer. *Curr Biol*. 1998;8:R87-R89.
- Williams CS, Smalley W, DuBois RN. Aspirin use and potential mechanisms for colorectal cancer prevention. *J Clin Invest*. 1997;100:1325-1329.
- Giovannucci E, Rimm EB, Stampfer MJ, et al. Aspirin use and the risk for colorectal cancer and adenoma in male health professionals. *Ann Intern Med*. 1994;121:241-246.
- Balthazer EJ, Megibow AJ, Hulnick D, et al. Carcinoma of the colon: detection and preoperative staging by CT. *AJR Am J Roentgenol*. 1988;150:301-306.
- Cappell MS. Gastrointestinal endoscopy in high risk patients. *Dig Dis*. 1996;14:228-244.
- Melmed AD. Anesthesia principles and techniques in pregnancy. In: Cherr ST, Merkatz IR, eds. *Complications of Pregnancy: Medical, Surgical, Gynecologic, Psychosocial, and Perinatal*. 4th ed. Baltimore, Md: Williams and Wilkins; 1991.
- Dark DS, Campbell DR, Wesselius LJ. Arterial oxygen desaturation during gastrointestinal endoscopy. *Am J Gastroenterol*. 1990;85:1317-1321.
- Cappell MS, Colon VJ, Sidhom OA. A study of eight medical centers of the safety and clinical efficacy of esophagogastroduodenoscopy in 83 pregnant females with follow-up of fetal in 83 pregnant females with follow-up of fetal outcome and with comparison control groups. *Am J Gastroenterol*. 1996;91:348-354.
- Lamerz R, Ruider H. Significance of CEA determinations in patients with cancer of the colon-rectum and the mammary gland in comparison to physiological states in connection with pregnancy. *Bull Cancer*. 1976;63:575-586.
- Fletcher RH. Carcinoembryonic antigen. *Ann Intern Med*. 1986;104:66-73.
- Brent RL. Radiation teratogenesis. *Teratology*. 1980;21:281-298.
- Brent RL. The effect of embryonic and fetal exposure to x-ray, microwaves, and ultrasound: counseling the pregnant and nonpregnant patient about these risks. *Semin Oncol*. 1989;16:347-368.
- Lees WR. Ultrasound of liver and spleen. In: Sutton D, Isherwood I, Forbes W, et al, eds. *A Textbook of Radiology and Imaging*. 5th ed. Edinburgh, NY: Churchill Livingstone; 1993.
- Nies C, Leppek R, Sitter H, et al. Prospective evaluation of different diagnostic techniques for the detection of liver metastases at time of primary resection of colorectal carcinoma. *Eur J Surg*. 1996;162:811-816.
- Seidman DS, Heyman Z, Ben-Ari GY, et al. Use of magnetic imaging in pregnancy to diagnose intussusception induced by colonic cancer. *Obstet Gynecol*. 1992;79:822-823.
- Knoepp LF Jr, Ray JE, Overby I. Ovarian metastases from colorectal carcinoma. *Dis Colon Rectum*. 1973;16:305-311.
- Mason MH 3rd, Kovalcik PJ. Ovarian metastases from colon carcinoma. *J Surg Oncol*. 1981;17:33-38.
- Pitluk H, Poticha SM. Carcinoma of the colon and rectum in patients less than 40 years of age. *Surg Gynecol Obstet*. 1983;157:335-337.
- Recalde M, Holyoke ED, Elias EG. Carcinoma of the colon, rectum and anal canal in young patients. *Surg Gynecol Obstet*. 1974;139:909-913.
- Motwani BT, Shafir M, Merrick M, et al. Adenocarcinoma of the colon and rectum. In: Holland JF, Frei E III, Bast RC Jr, et al, eds. *Cancer Medicine*. 4th ed. Baltimore, Md: Williams & Wilkins; 1997.
- Fleshman JW, Myerson RJ. Adjuvant radiation therapy for adenocarcinoma of the rectum. *Surg Clin North Am*. 1997;77:15-25.
- Lashrop JC. Malignant pelvic lymphomas. *Obstet Gynecol*. 1967;30:137-145.
- Weeks AE, Abbruzzese JL, Levin B. Current status of chemotherapy for colorectal cancer. *Drug Ther (NY)*. 1989;19:36-55.
- Grage TB, Moss SE. Adjuvant chemotherapy in cancer of the colon and rectum: demonstration of effectiveness of prolonged 5-FU chemotherapy in a prospectively controlled, randomized trial. *Surg Clin North Am*. 1981;61:1321-1329.
- Higgins GA, Lee LE, Dwight RW, et al. The case for adjuvant 5-fluorouracil in colorectal cancer. *Cancer Clin Trials*. 1978;1:35.
- MacDonald JS. Adjuvant therapy for colon cancer. *CA Cancer J Clin*. 1997;47:243-256.
- Moertel CG, Fleming TR, MacDonald JS, et al. Fluorouracil plus levamisole as effective adjuvant therapy after resection of stage III colon carcinoma: a final report. *Ann Intern Med*. 1995;122:321-326.
- Chabner BA, Allegra CJ, Curt GA et al. Antineoplastic agents. In: Hardman JG, Limbird LE, Molinoff PB, et al, eds. *Goodman and Gilman's The Pharmacological Basis of Therapeutics*. 9th ed. New York, NY: McGraw-Hill, Health Professions Division; 1996.
- Shuey DL, Buckalew AR, Wilke TS, et al. Early events following maternal exposure to 5-fluorouracil lead to dysmorphology in cultured embryonic tissues. *Teratology*. 1994;50:379-386.
- Sommers GM, Kao MS. Using chemotherapeutic agents during pregnancy. *Contemp Obstet Gynecol*. 1987;30:45-48.
- Aviles A, Diaz-Maqueo JC, Talavera A, et al. Growth and development

of children of mothers treated with chemotherapy during pregnancy: current status of 43 children. *Am J Hematol*. 1991;36:243-248.

48. Laurie JA, Moertel CG, Fleming TR, et al. Surgical adjuvant therapy of large-bowel carcinoma: an evaluation of levamisole and the combination of levamisole and fluorouracil. The North Central Cancer Treatment Group and the Mayo Clinic. *J Clin Oncol*. 1989;7:1447-1456.

49. Moertel CG, Fleming TR, MacDonald JS, et al. Levamisole and fluorouracil for adjuvant therapy of resected colon carcinoma. *N Engl J Med*. 1990;322:352-358.

50. Lipton LR, Johnson V, Cummings C, et al. Refining the Amsterdam Criteria and Bethesda Guidelines: testing algorithms for the prediction of mismatch repair mutation status in the familial cancer clinic. *J Clin Oncol*. 2004;22:4934-4943.

51. Umar A, Boland CR, Terdiman JP, et al. Revised Bethesda guidelines for hereditary non-polyposis colorectal cancer and microsatellite instability. *J Natl Cancer Inst*. 2004;96:261-268.

52. Chan YM, Ngai SW, Lao TT. Colon cancer in pregnancy: a case report. *J Reprod Med*. 1999;44:733-736.