



Charles Joseph Frederic Soulacroix, 1825-1879. *Betrothed*. Oil on canvas, 24 7/8" × 33".  
Courtesy of the Callan Fine Art gallery, New Orleans, Louisiana.

*Head and neck melanoma should be treated aggressively when morbidity is not significantly increased.*

## Head and Neck Melanoma

Matthew A. Kienstra, MD, and Tapan A. Padhya, MD

**Background:** Melanoma of the head and neck and its treatment are complex issues. The behavior of head and neck melanoma is aggressive, and it has an overall poorer prognosis than that of other skin sites.

**Methods:** The authors review current data on the treatment of head and neck melanoma, including both cutaneous and mucosal melanoma.

**Results:** Current understanding of the behavior of head and neck melanoma is reviewed and treatment stratagems are presented. Controversies in treatment include lymphoscintigraphy with sentinel node biopsy, nodal dissection, margin size, role of radiation therapy, and reconstruction. The management goal is to treat melanoma aggressively while minimizing the effects of treatment on patient quality of life.

**Conclusions:** Due to its aggressiveness, head and neck melanoma should be treated aggressively when morbidity is not significantly increased. Patient specific treatment is imperative.

### Etiology/Risk Factors

The number of new cases of melanoma in the United States in 2005 is estimated to be more than 59,000, and over 7,000 people will ultimately die of this disease.<sup>1</sup> The 600% rise in melanoma incidence over the past 50 years can be best explained by improved education and earlier

diagnosis resulting from better skin screening.<sup>2</sup> It is clear that sun exposure remains one of the most important risk factors in developing melanoma. Analysis has shown that the frequency of sunburns, geographic latitude, and age of exposure all play a part in lifetime melanoma presentation.<sup>3,4</sup> In a recent meta-analysis, Gandini et al<sup>5</sup> found a possible positive correlation between an individual's number of nevi and the overall risk of melanoma. Other major risk factors include pale skin, blue or green eyes, fair or freckled complexion, blond or reddish hair, and inability to tan.<sup>6,7</sup>

*From the Head and Neck Division at the H. Lee Moffitt Cancer Center & Research Institute, Tampa, Florida.*

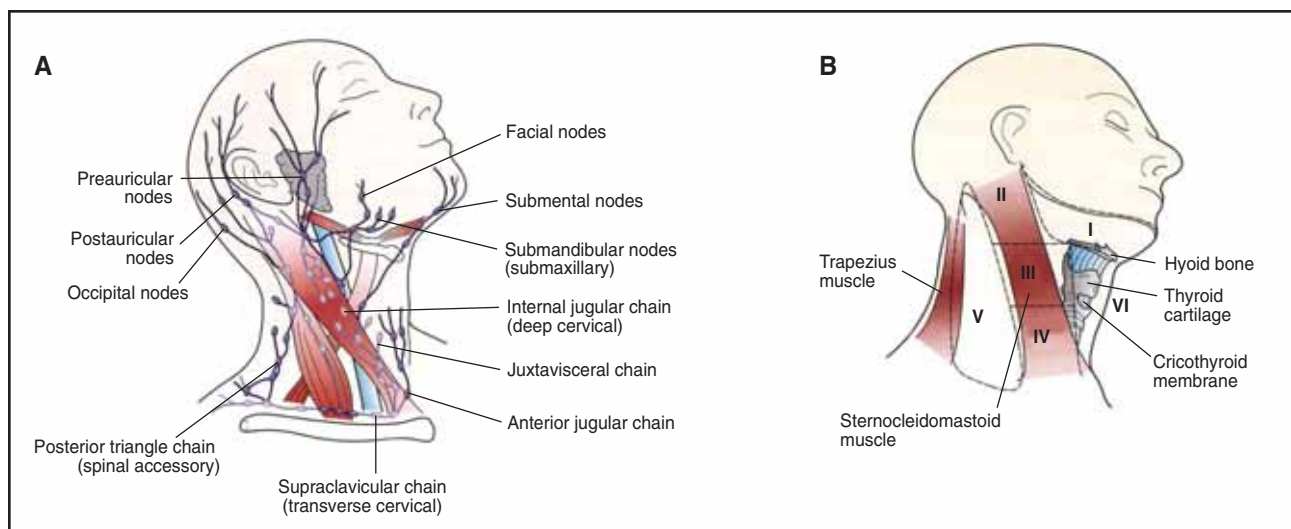
*Submitted March 5, 2005; accepted August 30, 2005.*

*Address correspondence to Matthew A. Kienstra, MD, Head and Neck Oncology Division, H. Lee Moffitt Cancer Center & Research Institute, 12902 Magnolia Drive, Tampa, FL 33612. E-mail: kienstma@moffitt.usf.edu*

*No significant relationship exists between the authors and the companies/organizations who products or services may be referenced in this article.*

### Sites of Origin

Anatomic cutaneous locations in the head and neck correlate with the areas of greatest sun exposure. Face,



Cervical nodal groups as described by their anatomic location (A), and classification of the lymph nodes according to nodal level (B). From Gluckman JL, Johnson JT, eds. *Surgical Management of Neck Metastases*. London, New York: Martin Dunitz; Independence, Ky: Distributed in the US by Taylor & Francis; 2003:9. Reprinted with permission from Thompson Publishing Services.

scalp, neck, and external ear are the leading sites for melanoma.<sup>8-15</sup> Of these sites, patients with scalp melanoma have been shown to exhibit poorer overall survival.<sup>16,17</sup> The rich regional lymphatics of the head and neck play an integral part in staging and the overall prognosis for an individual melanoma patient (Figure).

Mucosal melanomas in the head and neck are mainly found in the sinonasal cavity or the oral cavity.<sup>18-25</sup> Despite better diagnostic imaging and surveillance, mucosal melanomas generally exhibit poorer survival rates than cutaneous sites. Postoperative radiation therapy has shown promise in locoregional tumor control but has yet to show any benefit for overall survival.<sup>26,27</sup> Although still experimental, the use of biochemotherapy may have a promising role in a multimodality approach to mucosal melanomas.

## Types of Melanoma

The appearance and growth of melanoma differ depending on the morphologic type. Table 1 shows the incidence and features of six types of melanoma

**Table 1. — Characteristics and Incidence of Morphologic Subtypes of Melanoma**

Subtype	Incidence	Special Features
Superficial spreading	75%	Flat during early phase, typically from pre-existing nevus
Nodular	15%	Early vertical growth
Desmoplastic	low	Associated with perineural invasion
Lentigo maligna	10%	Prolonged radial growth
Acral lentiginous	2%–8%	Palms, soles, nail beds
Mucosal	2%	Poorer prognosis

**Superficial spreading melanomas** are the most common type. They are typified by an initial radial (spreading) growth phase with eventual development of a vertical growth phase. Superficial spreading melanoma is frequently associated with a nevus and often occurs in younger patients.

**Nodular melanomas** are the next most common type. These exhibit vertical growth from their onset.

**Lentigo maligna melanomas** are characterized by a prolonged radial growth phase. They tend to start as a slow-growing, flat patch in sun-exposed areas (often the face and neck). They have a proclivity for the dermal-epidermal junction and tend to follow hair follicles.

**Acral lentiginous melanomas** are characteristically located on the palms or soles. Not all such lesions are acral lentiginous; however, they have a defined histologic appearance.

**Desmoplastic melanomas** can be seen in association with pre-existing melanocytic lesions and can more frequently be amelanotic, making their diagnosis more difficult. They tend to be characterized by infrequent metastasis with a higher local recurrence rate, as well as more frequent perineural involvement.

**Mucosal melanomas** most frequently present in the nose and/or sinuses, followed by the oral cavity and nasopharynx. They are rare lesions but have a poor prognosis. Because of their development in hidden, clinically silent areas, diagnosis often occurs late, requiring more radical treatment and contributing to the poorer prognosis.

## Staging

In 2002, the American Joint Council on Cancer (AJCC) revised the melanoma staging system last modified in 1997 using a database of more than 17,000 patients.<sup>28,29</sup>

Multiple features of the primary tumor and subsequent nodal status were added to better stratify and stage new melanoma patients (Table 2).<sup>30</sup> In the past, Breslow depth of invasion has been shown to have prognostic significance, as has Clark level of invasion. In the new system, Breslow depth plays a more vital role, while Clark level is de-emphasized (relevant only for T1 lesions). Other changes include the presence or absence of tumor ulceration, as well as tumor (T) thickness limits at 1.0-mm, 2.0-mm, and 4.0-mm depth for defining T stage. Stages I and II were confined to clinical staging, while stages III and IV used pathologic information from the nodes to define

staging. Where the 1997 system used the size of nodal metastases to judge prognosis, new data have shown that the number of metastatic nodes is more relevant. The new system reflects that relevance by basing the N (nodal) stage on number of nodes as follows: 1 vs 2-3 vs  $\geq 4$  metastatic nodes. In-transit metastases, which were grouped with the T staging in the 1997 system, are now included with the N staging. In general, in-transit metastases have been recognized to portend a poorer prognosis, which is reflected in the new system. Distant metastases are now grouped into one of three groups: M1a (including subcutaneous nodules/distant nodes), M1b (confined to lung metastases), and M1c (for all other visceral sites). Elevated lactate dehydrogenase (LDH) serum level also is associated with poor prognosis, and patients with distant metastases and increased LDH are stage M1c regardless of site of metastasis.

**Table 2. — Melanoma TNM Classification**

<b>Primary Tumor (T)</b>	
TX	Primary tumor cannot be assessed (eg, shave biopsy or regressed melanoma)
T0	No evidence of primary tumor
Tis	Melanoma <i>in situ</i>
T1	Melanoma $\leq 1.0$ mm in thickness with or without ulceration
T1a	Melanoma $\leq 1.0$ mm in thickness and level II or III, no ulceration
T1b	Melanoma $\leq 1.0$ mm in thickness and level IV or V or with ulceration
T2	Melanoma 1.01-2 mm in thickness with or without ulceration
T2a	Melanoma 1.01-2.0 mm in thickness, no ulceration
T2b	Melanoma 1.01-2.0 mm in thickness, with ulceration
T3	Melanoma 2.01-4 mm in thickness with or without ulceration
T3a	Melanoma 2.01-4.0 mm in thickness, no ulceration
T3b	Melanoma 2.01-4.0 mm in thickness, with ulceration
T4	Melanoma greater than 4.0 mm in thickness with or without ulceration
T4a	Melanoma $> 4.0$ mm in thickness, no ulceration
T4b	Melanoma $> 4.0$ mm in thickness, with ulceration
<b>Regional Lymph Nodes (N)</b>	
NX	Regional lymph nodes cannot be assessed
N0	No regional lymph node metastasis
N1	Metastasis in one lymph node
N1a	Clinically occult (microscopic) metastasis
N1b	Clinically apparent (macroscopic) metastasis
N2	Metastasis in two to three regional nodes or intra-lymphatic regional metastasis without nodal metastases
N2a	Clinically occult (microscopic) metastasis
N2b	Clinically apparent (macroscopic) metastasis
N2c	Satellite or in-transit metastasis <i>without</i> nodal metastasis
N3	Metastasis in four or more regional nodes, or matted metastatic nodes, or in-transit metastasis or satellite(s) <i>with</i> metastasis in regional node(s)
<b>Distant Metastasis (M)</b>	
MX	Distant metastasis cannot be assessed
M0	No distant metastasis
M1	Distant metastasis
M1a	Metastasis to skin, subcutaneous tissues or distant lymph nodes
M1b	Metastasis to lung
M1c	Metastasis to all other visceral sites or distant metastasis at any site associated with an elevated serum lactic dehydrogenase (LDH)
Used with the permission of the American Joint Committee on Cancer, Chicago, Illinois. The original source for this material is the <i>AJCC Cancer Staging Manual</i> , 6th ed (2002) published by Springer-Verlag New York. <a href="http://www.springeronline.com">www.springeronline.com</a>	

## Evaluation and Treatment

Suspicious lesions are defined by the ABCD(E) criteria. This acronym denotes asymmetry, border irregularity, color variegation, diameter greater than 6 mm, and evolution of the lesion. This last criterion, which is a relatively recent addition, emphasizes monitoring of benign lesions to evaluate change over time.<sup>31</sup> For suspicious lesions, a full thickness biopsy is crucial for adequate diagnosis of lesion depth and invasion.

Stage-appropriate treatment of head and neck melanoma is paramount for achieving good outcomes. The AJCC staging system for cutaneous melanoma is the standard.<sup>28</sup> Treatment of melanoma *in situ* is typically resection with 5-mm margins. Stage I disease is also treated typically with resection alone but with 1-cm margins. For T2a N0 M0 disease (stage 1B), because of depth of invasion greater than 1 mm, sentinel lymph node biopsy is also recommended. For stage II disease, wide excision of the primary lesion with 2-cm margins and sentinel lymph node biopsy is recommended. Regional node dissection is performed if positive nodes are identified. Stage III disease is treated with wide excision of the primary with 2-cm margins and regional node dissection. Consideration of postoperative radiation treatment is undertaken, and systemic chemotherapy usually is recommended. At our institute, treatment for stage IV disease is individualized and usually is coordinated by a medical oncologist through the Cutaneous Oncology Tumor Board. In addition to more traditional chemotherapy, interferon, interleukins, vaccine therapy, and other forms of biochemotherapy are commonly used and hold promise for the future. A discussion of chemotherapy is beyond the scope of this article and is covered in more detail elsewhere in this issue.

It is important to emphasize that these are treatment guidelines. Some controversy exists in a number of areas. In terms of excision of the primary site, thin melanoma

margins are generally accepted to be 1 cm. For melanomas greater than 2 mm in thickness, 2-cm margins are the norm. However, Krown and Chapman<sup>32</sup> noted that the ideal margin width for these deeper lesions has not been adequately studied. More information regarding current excision margin recommendations is available, please see the review on the subject by Lens et al.<sup>33</sup> In the head and neck regions, adequate margins may not be possible or advisable due to cosmetic or functional concerns. For example, centrally located thick eyelid melanomas would normally be treated with 2-cm margins, thus requiring complete excision of the eyelid and resulting in significant reconstructive issues and risk of blindness or a non-functional eye. Similar concerns exist around the mouth, nose, and ears. In such cases, narrower margins are necessary, likely resulting in an increase in treatment failure but preventing functional and cosmetic problems that are associated with severe loss of quality of life. The decision to utilize narrower margins than has been shown to be effective is never made lightly and involves thorough discussion with the patient to determine the best option for each individual.

Radiation therapy also has been controversial in the past due to the fact that the radiosensitivity of melanoma was at least considered questionable. This is changing as more recent data becomes available. Adjuvant radiation therapy for neck disease has been shown to be beneficial for patients with aggressive disease.<sup>34</sup> Extracapsular extension, large nodal size, numerous (greater than 4) nodes involved, and recurrent disease are generally considered indications for adjuvant radiation therapy, and some argue that all patients with lymph node involvement should receive adjuvant radiation therapy.<sup>34</sup> There are also data that support radiation treatment alone for regional disease control in head and neck melanoma, although no direct comparison of radiation vs surgical treatment has been studied.<sup>35</sup>

Another controversial issue involves the role of sentinel node biopsy and nodal (usually neck) dissection in the treatment of head and neck cutaneous melanoma. This issue deserves greater examination in separate subsections.

### **Lymphoscintigraphy With Sentinel Node Biopsy**

In most high-volume academic centers that treat patients with melanoma, lymphoscintigraphy with sentinel node biopsy (LSNB) has become the standard of care for identifying occult regional metastases in at-risk, low-stage lesions. As stated above, this topic warrants special consideration in the head and neck. Methodology is described elsewhere.<sup>36</sup>

Because of the varied drainage patterns and complex anatomy of the region with subsequent risk to cranial nerves and major blood vessels, successful LSNB is technically challenging. Dissection for intraparotid lymph nodes, for example, puts the facial nerve at risk. Injury to the facial nerve is associated with significant cosmetic and functional problems including chewing and eating diffi-

culties, drooling, marked facial asymmetry, loss of facial expressions, epiphora, eye pain, vision obstruction, corneal damage, and even blindness. This has led to consideration for parotidectomy with dissection and preservation of the facial nerve, an arguably safer procedure, for patients with sentinel node involvement in the parotid. In cases where mapping has identified two or more parotid nodes as sentinel, superficial parotidectomy is used at our institute to remove the at-risk nodes while minimizing the risk of facial nerve injury. There also tends to be a higher number of sentinel nodes identified in head and neck tumors, further increasing risk of morbidity.<sup>37</sup> Dissection through small incisions for individual nodes in the head and neck can be time-consuming and risky since the nodes are located primarily near the carotid sheath structures and cranial nerves. When more nodes need to be located, there is a greater risk of injury. Multiple incisions are usually necessary when multiple nodes are sentinel, which increases the number of visible scars on the head and neck. As the Sunbelt Melanoma Trial has confirmed, however, LSNB accuracy and safety for head and neck lesions is acceptable and compares with that of truncal and extremity lesions.<sup>37</sup> Although there are concerns with altered draining patterns, LSNB is generally considered reasonable after excision of the primary site as long as flap reconstruction has not been performed (ie, primary closure or skin graft was used to reconstruct the primary site). The preferred method, however, is lymphoscintigraphy prior to but during the same surgery as wide excision of the primary site. Data have confirmed the utility of SNLB as a staging procedure, but its therapeutic role is less clear. Removal of sentinel nodes and dissection of the nodal basins in positive cases has been shown to improve locoregional recurrence rates but has not positively affected survival. Studies are currently underway to examine this issue further.<sup>38</sup>

### **Neck Dissection**

As already noted, the therapeutic value of regional node dissection in terms of prolonged survival is questionable. Because of this fact, as well as efficacy data from the Sydney Melanoma Unit of various types of neck dissection, selective dissections are recommended where adequate disease removal (eg, clinically negative neck, non-fixed disease, small nodes) is possible using that technique.<sup>39,40</sup> Sacrifice of obviously involved structures is indicated otherwise. Radical neck dissection, unless indicated because of disease extent, should be avoided due to unnecessary morbidity. Because of the high risk of occult involved nodes, neck dissection should accompany parotidectomy for positive parotid disease.<sup>41</sup> Dissection extent in terms of at-risk nodal basins depends on the primary site.<sup>40</sup> Lesions of the upper neck, face, and scalp anterior to the ear usually require dissection of the parotid and levels I-IV of the neck. Lesions of the upper neck and scalp posterior to the ear usually require dis-

section of levels II-V of the neck. Lesions of the inferior neck usually require dissection of levels III-V. Lesions of the ear and of the scalp and neck at the level of the ear drain to all areas of the neck and require parotid and complete (levels I-V) neck dissections.

According to data from the Sydney Melanoma Unit, these drainage patterns are consistent in 92% of cases. This leaves a significant 8% incidence of drainage to nodal basins outside those listed as typical by primary site. For this reason, we have had a tendency to perform more extensive dissection in cases of more aggressive disease or in primaries that involve more than one of the arbitrarily defined regions listed above. In cases where sentinel node sampling has revealed positive nodes outside of the standard drainage patterns defined above, all involved nodal basins should be dissected. In cases of T3 and T4 lesions associated with risk of lymph involvement greater than 20% (for T3) and 30%-50% (for T4), we have used LSNB to direct the need for regional node dissection, performing dissection only in positive cases. Some argue for node dissection in these cases due to the high risk of nodal involvement. This debate continues because, as stated above, therapeutic nodal dissection has not been definitively shown to have a survival benefit; it improves locoregional control.<sup>38</sup> Adding further complexity to this debate, data show that recurrence rates in the neck after neck dissection are higher than those in the axillary or inguinal areas.<sup>42,43</sup> This fact has been used to support both sides — one side argues that the more aggressive disease requires more aggressive treatment and thus favors dissection, while the other argues that dissection is less likely to matter and therefore morbidity should be decreased by avoiding dissection when the clinical situation does not clearly show the need (eg, in negative LSNB). Further studies are necessary to answer this question.

## Considerations in Reconstruction of Head and Neck Melanoma Defects

Because of the need for permanent section pathology review with its attendant time lapse for staining, traditional initial reconstructive efforts have been temporizing, in the form of secondary intention healing, primary closure, or skin grafts. These options generally are not the best options for restoring function and cosmesis for head and neck defects in visible regions. Tissue contraction from skin grafting or healing by secondary intention and distortion from primary closure is not well tolerated near or on the nose, mouth/lips, eyelids, and eyebrows and can cause dysfunction and/or cosmetic deformity in these areas. In cases distant from these sites, healing by secondary intention, primary closure, and/or skin grafting is generally sufficient for defects of less than 3 cm in diameter. Unfortunately, most melanoma resection defects are larger (greater than 3 cm in diameter) because of the need for at least 1-

cm margins to perform oncologically adequate tumor removal. Secondary, more appropriate closures in the form of locoregional or free flaps can be performed once negative margin status is achieved; these have been shown to improve functional and cosmetic outcomes.<sup>44</sup>

For lesions where improved functional and cosmetic outcomes are expected to require flap reconstruction, delayed wound closure is recommended after negative margin status has been achieved. Moffitt Cancer Center has the capability for rapid staining and pathologist review within 24 hours, allowing for wound closure in 1 to 2 days. For patients who cannot or do not want to undergo another procedure that rapidly, skin homografts or allografts are recommended to provide a safe wound that can heal rapidly. Functional and/or cosmetic deformities from the reconstruction can then be addressed with secondarily as required.

## Conclusions

Head and neck melanoma is a complex disease, especially in treatment considerations. In general, it carries a well-recognized poorer prognosis. We therefore have had a lower threshold for more aggressive treatment where risk of morbidity is still minimal. The complex anatomy of the region warrants special considerations and further complicates therapeutic decision-making. As in any area of medicine, thorough study and individualized treatment based on specific patient needs yield optimal outcomes.

## References

1. Jemal A, Murray T, Ward E, et al. Cancer statistics, 2005. *CA Cancer J Clin.* 2005;55:10-30. Erratum in: *CA Cancer J Clin.* 2005;55:259.
2. Ries LAG, Eisner MP, Kosary CL, et al, eds. *SEER Cancer Statistics Review, 1975-2002.* Bethesda, Md: National Cancer Institute; 2004. Available at: [http://seer.cancer.gov/csr/1975\\_2002](http://seer.cancer.gov/csr/1975_2002). Accessed September 6, 2005.
3. Gandini S, Sera F, Cattaruzza MS, et al. Meta-analysis of risk factors for cutaneous melanoma, II: sun exposure. *Eur J Cancer.* 2005;41:45-60.
4. Berwick M, Armstrong BK, Ben-Porat L, et al. Sun exposure and mortality from melanoma. *J Natl Cancer Inst.* 2005;97:195-199.
5. Gandini S, Sera F, Cattaruzza MS, et al. Meta-analysis of risk factors for cutaneous melanoma, I: common and atypical naevi. *Eur J Cancer.* 2005;41:28-44.
6. Holman CD, Armstrong BK. Pigmentary traits, ethnic origin, benign nevi, and familial history as risk factors for cutaneous malignant melanoma. *J Natl Cancer Inst.* 1984;72:257-266.
7. Rigel DS. Epidemiology and prognostic factors in malignant melanoma. *Ann Plast Surg.* 1992;28:7-8.
8. Ballantyne AJ. Malignant melanoma of the skin of the head and neck: an analysis of 405 cases. *Am J Surg.* 1970;120:425-431.
9. Byers RM, Smith JL, Russell N, et al. Malignant melanoma of the external ear: review of 102 cases. *Am J Surg.* 1980;140:518-521.
10. Urist MM, Balch CM, Soong SJ, et al. Head and neck melanoma in 534 clinical stage I patients: a prognostic factors analysis and results of surgical treatment. *Ann Surg.* 1984;200:769-775.
11. Loree TR, Spiro RH. Cutaneous melanoma of the head and neck. *Am J Surg.* 1989;158:388-391.
12. Fisher SR. Cutaneous malignant melanoma of the head and neck. *Laryngoscope.* 1989;99(8 pt 1):822-836.
13. Andersson AP, Gottlieb J, Drzewiecki KT, et al. Skin melanoma of the head and neck: prognostic factors and recurrence-free survival in 512 patients. *Cancer.* 1992;69:1153-1156.
14. Ringborg U, Afzelius LE, Lagerlof B, et al. Cutaneous malignant melanoma of the head and neck. Analysis of treatment results and prognostic factors in 581 patients: a report from the Swedish Melanoma Study Group. *Cancer.* 1993;71:751-758.

15. Garbe C, Buttner P, Bertz J, et al. Primary cutaneous melanoma: prognostic classification of anatomic location. *Cancer*. 1995;75:2492-2498.
16. Close LG, Goepfert H, Ballantyne AJ. Malignant melanoma of the scalp. *Laryngoscope*. 1979;89:1189-1196.
17. Essner R, Wong JH, Economou JS, et al. Prognostic significance of melanoma arising in the scalp. *Am J Surg*. 1988;156:314-317.
18. Stern SJ, Guillaumondegui OM. Mucosal melanoma of the head and neck. *Head Neck*. 1991;13:22-27.
19. Kingdom TT, Kaplan MJ. Mucosal melanoma of the nasal cavity and paranasal sinuses. *Head Neck*. 1995;17:184-189.
20. Patel SG, Prasad ML, Escrig M, et al. Primary mucosal malignant melanoma of the head and neck. *Head Neck*. 2002;24:247-257.
21. Medina JE, Ferlito A, Pellitteri PK, et al. Current management of mucosal melanoma of the head and neck. *J Surg Oncol*. 2003;83:116-122.
22. Yii NW, Eisen T, Nicolson M, et al. Mucosal malignant melanoma of the head and neck: the Marsden experience over half a century. *Clin Oncol (R Coll Radiol)*. 2003;15:199-204.
23. Prasad ML, Busam KJ, Patel SG, et al. Clinicopathologic differences in malignant melanoma arising in oral squamous and sinonasal respiratory mucosa of the upper aerodigestive tract. *Arch Pathol Lab Med*. 2003;127:997-1002.
24. Prasad ML, Patel SG, Huvos AG, et al. Primary mucosal melanoma of the head and neck: a proposal for microstaging localized, stage I (lymph node-negative) tumors. *Cancer*. 2004;100:1657-1664.
25. Martin JM, Porceddu S, Weih L, et al. Outcomes in sinonasal mucosal melanoma. *ANZ J Surg*. 2004;74:838-842.
26. Owens JM, Roberts DB, Myers JN. The role of postoperative adjuvant radiation therapy in the treatment of mucosal melanomas of the head and neck region. *Arch Otolaryngol Head Neck Surg*. 2003;129:864-868.
27. Temam S, Mammelle G, Marandas P, et al. Postoperative radiotherapy for primary mucosal melanoma of the head and neck. *Cancer*. 2005;103:313-319.
28. Balch CM, Buzaid AC, Soong SJ, et al. Final version of the American Joint Committee on Cancer staging system for cutaneous melanoma. *J Clin Oncol*. 2001;19:3635-3648.
29. Greene FL, Page DL, Fleming ID, et al, eds. *AJCC Cancer Staging Manual*. 6th ed. New York, NY: Springer Verlag; 2002:209-217.
30. Balch CM, Soong SJ, Gershenwald JE, et al. Prognostic factors analysis of 17,600 melanoma patients: validation of the American Joint Committee on Cancer melanoma staging system. *J Clin Oncol*. 2001;19:3622-3634.
31. Abbasi NR, Shaw HM, Rigel DS, et al. Early diagnosis of cutaneous melanoma: revisiting the ABCD criteria. *JAMA*. 2004;292:2771-2776.
32. Krown SE, Chapman PB. Defining adequate surgery for primary melanoma. *N Engl J Med*. 2004;350:823-825.
33. Lens MB, Dawes M, Goodacre T, et al. Excision margins in the treatment of primary cutaneous melanoma: a systematic review of randomized controlled trials comparing narrow vs wide excision. *Arch Surg*. 2002;137:1101-1105.
34. Ballo MT, Bonnen MD, Garden AS, et al. Adjuvant irradiation for cervical lymph node metastases for melanoma. *Cancer*. 2003;97:1789-1796.
35. Bonnen MD, Ballo MT, Myers JN, et al. Elective radiotherapy provides regional control for patients with cutaneous melanoma of the head and neck. *Cancer*. 2004;100:383-389.
36. Morton DL, Thompson JF, Essner R, et al. Validation of the accuracy of intraoperative lymphatic mapping and sentinel lymphadenectomy for early-stage melanoma: a multicenter trial. Multicenter Selective Lymphadenectomy Trial Group. *Ann Surg*. 1999;230:453-465.
37. McMasters KM, Noyes RD, Reintgen DS, et al. Lessons learned from the Sunbelt Melanoma Trial. *J Surg Oncol*. 2004;86:212-223.
38. Reintgen D, Pendas S, Jakub J, et al. National trials involving lymphatic mapping for melanoma: the Multicenter Selective Lymphadenectomy Trial, the Sunbelt Melanoma Trial, and the Florida Melanoma Trial. *Semin Oncol*. 2004;31:363-373.
39. O'Brien CJ, Petersen-Schaefer K, Ruark D, et al. Radical, modified, and selective neck dissection for cutaneous malignant melanoma. *Head Neck*. 1995;17:232-241.
40. Pathak I, O'Brien CJ, Petersen-Schaefer K, et al. Do nodal metastases from cutaneous melanoma of the head and neck follow a clinically predictable pattern? *Head Neck*. 2001;23:785-790.
41. O'Brien CJ, McNeil EB, McMahon JD, et al. Incidence of cervical node involvement in metastatic cutaneous malignancy involving the parotid gland. *Head Neck*. 2001;23:744-748.
42. Lee RJ, Gibbs JF, Proulx GM, et al. Nodal basin recurrence following lymph node dissection for melanoma: implications for adjuvant radiotherapy. *Int J Radiat Oncol Biol Phys*. 2000;46:467-474.
43. Bowsher WG, Taylor BA, Hughes LE. Morbidity, mortality and local recurrence following regional node dissection for melanoma. *Br J Surg*. 1986;73:906-908.
44. Bogle M, Kelly P, Shenaq J, et al. The role of soft tissue reconstruction after melanoma resection in the head and neck. *Head Neck*. 2001;23:8-15.