



Donna Morrison. *Lone Flyer*. Watercolor, 23" × 30".

Clinical and pathologic information on the different features of these rare entities is important in managing these tumors.

Poorly Differentiated and Anaplastic Thyroid Cancer

Kepal N. Patel, MD, and Ashok R. Shaha, MD, FACS

Background: Poorly differentiated thyroid carcinoma (PDTC) and anaplastic (undifferentiated) thyroid carcinoma (ATC) comprise a small subset of thyroid tumors that are associated with a poor prognosis and account for a significant portion of the morbidity and mortality related to thyroid cancer. Since management strategies vary between these two entities, it is important for clinicians to be able to differentiate PDTC from ATC.

Methods: We reviewed the literature on PDTC and ATC and compared clinical and histopathologic features important in defining the disease process.

Results: Both PDTC and ATC display aggressive behavior with increased locoregional and distant disease. In most cases, patients are older and have large, locally advanced tumors. PDTC may represent an intermediate entity in the progression of well-differentiated thyroid carcinoma to ATC. The use of surgical management may be curative or palliative and differs between PDTC and ATC. The roles of radiotherapy and chemotherapy have not been well described.

Conclusions: PDTC and ATC are rare diseases that carry a poor prognosis. Recognition of their different clinicopathologic features is important to the optimal management of these tumors.

From the Department of Surgery, Stony Brook University Hospital, Stony Brook, New York (KNP), and the Head and Neck Service, Memorial Sloan-Kettering Cancer Center, New York, New York (ARS). Submitted July 28, 2005; accepted December 26, 2005.

Address correspondence to Ashok R. Shaha, MD, FACS, Head and Neck Service, Memorial Sloan-Kettering Cancer Center, 1275 York Avenue, New York, NY 10021. E-mail: shabaa@mskcc.org

No significant relationship exists between the authors and the companies/organizations whose products or services may be referenced in this article.

Abbreviations used in this paper: PDTC = poorly differentiated thyroid carcinoma, WDTC = well-differentiated thyroid carcinoma, ATC = anaplastic thyroid carcinoma, ITC = insular thyroid carcinoma, FNAB = fine-needle aspiration biopsy, TG = thyroglobulin, RAI = radioactive iodine, EBRT = external-beam radiation therapy.

Introduction

Malignant tumors of thyroid follicular cell origin have traditionally been classified as either well-differentiated thyroid carcinoma (WDTC), which is composed of papillary and follicular carcinoma, or undifferentiated/anaplastic thyroid carcinoma (ATC). The vast majority of patients with WDTC have an excellent prognosis regardless of the types of treatment used, whereas patients with ATC uniformly have a poor prognosis.¹ There is growing evidence for the existence of a group of tumors that fall between WDTC and ATC in terms of both morphologic appearance and biologic behavior.

These tumors, classified as poorly differentiated thyroid carcinoma (PDTC), may represent *intermediate* entities in the progression of WDTC to ATC.²⁵ Patients with PDTC often have a rapid and fatal outcome despite appropriate treatment. Although over the years multiple publications have reported on this subject, controversies regarding optimal management of these patients still exist. This review is limited to PDTC and ATC in an attempt to better document their clinical behavior and long-term prognosis.

Poorly Differentiated Thyroid Carcinoma

Much of the controversy, confusion, and inconsistency surrounding PDTC comes from the lack of consensus regarding criteria and definitions. The term *poorly differentiated thyroid carcinoma* was introduced by Sakamoto et al² in 1983, and their criteria were based mainly on the presence of nonglandular components with a solid, trabecular, and/or scirrhous growth pattern. Others have included aggressive papillary thyroid carcinoma variants such as columnar cell, tall cell, diffuse sclerosing, and solid.⁶⁸ The fact that these papillary thyroid cancer variants tend to show a more aggressive behavior pattern than the classic type of differentiated thyroid carcinoma does not in itself justify the use of the term *poorly differentiated*, as defined by the tumor architecture.⁹ Furthermore, these tumors do not have an invariably poor prognosis. For example,

the solid variant of papillary thyroid cancer displays some aggressive features, but patients tend to be younger and, with appropriate treatment, their overall prognosis is similar to that of classic papillary thyroid cancer.¹⁰ The tumors are especially frequent among pediatric thyroid carcinomas from the Chernobyl area and are associated with the *RET/PTC3* rearrangement.^{11,12} Patients with encapsulated columnar cell thyroid carcinoma also have an excellent prognosis and should not be classified as PDTC.¹³ Since some clinicians include clinical characteristics in defining PDTC, the literature is inconsistent, thus precluding any definitive conclusions regarding the disease process. It is preferable to limit this term to histologic criteria.

We agree with the definition by Burman et al¹⁴ and others¹⁵ that “poorly differentiated thyroid carcinoma is a concept proposed to include carcinomas of follicular thyroid epithelium that retain sufficient differentiation to produce scattered small follicular structures and some thyroglobulin, but generally lack the usual morphologic characteristics of papillary and follicular carcinoma.” Based on this description, we have developed a chart to help classify tumors of thyroid follicular origin (Fig 1). PDTCs fall into two main categories — insular and other (large cell).

Insular Thyroid Carcinoma

Insular thyroid carcinoma (ITC) is the best-characterized group of PDTCs. Langhans¹⁶ first described it in 1907 as “wuchernde struma” (proliferating struma). He

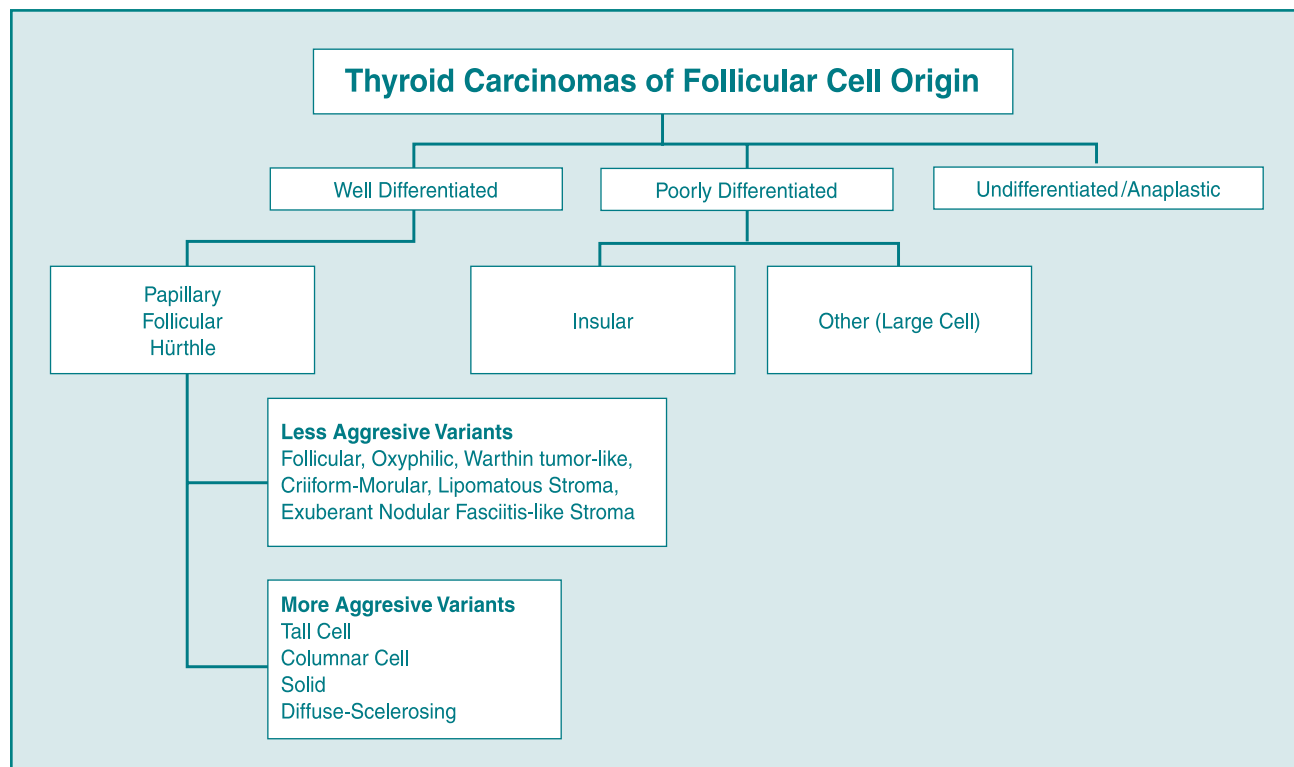


Fig 1. — Classification of thyroid carcinomas of follicular cell origin.

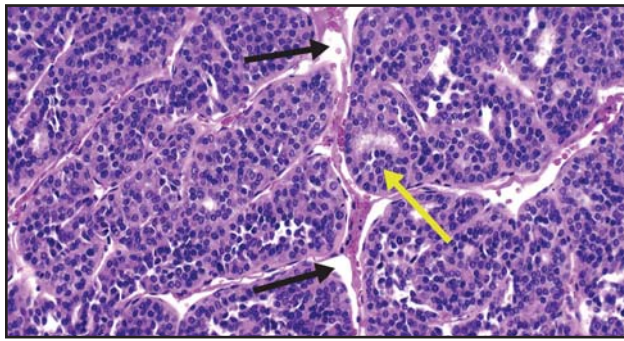


Fig 2. — Insular thyroid carcinoma, showing the nesting patterns of the follicles (yellow arrow) and the artifactually created clefts (black arrows).

described a tumor characterized by a distinct nesting pattern, formation of small follicular lumina leading to a cribriform configuration, small size and uniformity of the tumor cells, necrosis, and a focally peritheliomatous pattern of growth (tumor cells around blood vessels, with necrosis of tumor cells farther away from vessels). This tumor entity was ignored by most modern authors¹⁷⁻¹⁹ as an inconsequential morphologic variant of follicular carcinoma, partially due to geographic differences in the frequency of this neoplasm. It was reinterpreted and termed *poorly differentiated “insular” thyroid carcinoma* by Carcangiu et al³ in 1984. The term *insular* was used to describe these tumors because the cellular appearance was similar to that seen in the insular type of carcinoid tumors. Since this revised description in 1984, over 200 cases of ITC have been described in the literature.^{3,20-32}

Pathology

The morphologic appearance of this tumor is similar from case to case. Macroscopic features include a solid, grayish-white tumor with multiple foci of necrosis. They usually display an invasive margin, they tend to be more than 4 cm in size, and they can be either single or multinodular. The microscopic features as described by Carcangiu et al³ include solid clusters “nests” of tumor cells containing a variable number of follicles, often sharply separated by artifactually created clefts. This is the predominant growth pattern. This picture is typical for carcinoid and pancreatic endocrine tumors, which are referred to as insular (Fig 2). Other critical features are small size and uniformity of tumor cells, variable but

consistent mitotic activity, necrosis, and capsular and vascular invasion that sometimes leads to the formation of peritheliomatous structures. The peritheliomatous structures refer to the insulae surrounding the large blood vessels, which have been spared from necrosis.

Preoperative fine-needle aspiration biopsy (FNAB) can be helpful in planning treatment options and patient management. Pietribiasi et al³³ reviewed 6 cases of ITC with preoperative FNAB. They assessed cytologic features and compared them with the final histologic specimen. They consistently found high cellularity, necrotic background, low-grade atypia, trabeculae and/or clusters, microfollicles, cytoplasmic vacuoles containing thyroglobulin (TG), and nuclear inclusions. These features were not uniform. This is consistent with the histologic heterogeneity seen in these tumors. The authors concluded that FNAB could provide a suggestive but not definitive preoperative diagnosis of ITC.

Immunohistochemical staining is an invaluable tool in diagnosing and understanding the pathophysiology of thyroid tumors. It confirms that ITC is of follicular cell origin by staining positive for TG and thyroid transcription factor 1 (TTF-1). ATC does not stain positive for TG.²¹ Immunohistochemical staining for p53 mutation also can be helpful in determining tumor progression. WDTC does not usually stain for p53 mutation, whereas staining varies between 0% and 38% in ITC and is >70% in ATC.^{25,27,34} Furthermore, the presence of well-differentiated and/or anaplastic components within ITC has been frequently reported.^{25,34} In one series, concomitant WDTCs were noted in 59% of patients with ITC.²⁵ These observations lend support to the hypothesis that ITC represents an intermediate entity in the dedifferentiation of WDTC to ATC. Immunohistochemical staining for calcitonin, chromogranin, and carcinoembryonic antigen is negative in ITC. These stains, along with the distinct cellular features, can be helpful not only in narrowing the differential diagnosis, but also in ruling out entities such as medullary thyroid cancer.

Other (Large Cell)

This small group of PDTCs represents tumors that have a variable architecture consistent with intermediate differentiation. Unlike aggressive variants of papillary thyroid carcinoma, these tumors do not retain the usual

Table 1. — Comparison of Histologic Features of Insular and Other Subtypes of Poorly Differentiated Thyroid Carcinomas

Insular Carcinomas	Other Subtypes
Solid clusters (“insulae”) of tumor cells containing a variable number of follicles is the predominant growth pattern	Variable architecture (follicular, solid, trabecular, papillary); insular component minor
Small size and uniformity of tumor cells	Larger size of tumor cells with variable cytology (oncocytic, clear, pap nuclei)
Variable but consistent mitotic activity	Variable but consistent mitotic activity
Necrosis	Necrosis
Capsular and vascular invasion	Capsular and vascular invasion

morphologic characteristic formation of papillary structures, thereby making this a poorly differentiated tumor entity. Histologically, these tumors are similar to ITC in that they also display increased mitotic activity, necrosis, and capsular and vascular invasion, and they stain positive for TG. These tumors are unlike ITC in that they can have a variable architecture (follicular, solid, trabecular, papillary) with a minor insular component.²¹ Furthermore, the tumor cells are larger and have variable cytology when compared to ITC (Table 1). Clinically, these patients behave like patients with ITC, with similar overall survival; however, ITC tends to recur more frequently in patients.²¹

Clinical Characteristics

PDTCs are tumors of intermediate biological aggressiveness, consistent with their intermediate differentiation. They account for up to 10% of all thyroid cancers. This may be inaccurate due to inconsistent definitions of PDTC used by different authors. PDTC has a higher incidence in Europe than in the United States and the male-to-female ratio is greater than 1:2.^{14,35}

We recently reviewed our experience and compared the clinical characteristics of WDTC, PDTC, and ATC.³⁶ Our results were consistent with others in that PDTC displayed clinical characteristics of intermediate aggressive behavior when compared to WDTC and ATC (Table 2). Whether the presence of a minor component of PDTC worsens the prognosis of WDTC is an area of further investigation. Van den Brekel et al²⁹ found that the insular component within a WDTC was not associated with a poor prognosis, but the follow-up was only 2 years.²⁹ Ashfaq et al³¹ found that the insular component correlated with older age, and using multivariate analysis, only age and stage were prognostic. However, Pilotti et al⁷ demonstrated the prognostic impact of differentiation on recurrence and death. Decaussin et al³⁷ found that the presence of an insular component was an independent poor prognostic factor that must be

carefully searched for, in the background of a WDTC, since it could predict a worse prognosis. They also reported age, extrathyroidal extension, and vascular invasion as independent poor prognostic factors.

Treatment

The rarity of this tumor makes it difficult to draw conclusions from the literature as to the best treatment option for PDTC. Surgical management of this entity is the principal treatment approach. Most authors agree that due to the aggressive nature of these tumors, a total thyroidectomy is necessary. With over 50% of PDTCs having regional nodal metastases, central compartment with possible modified radical neck dissection should be considered.³⁶ The use of radioactive iodine (RAI), external-beam radiation therapy (EBRT), or chemotherapy is still controversial.

PDTCs arise from follicular epithelium and thus have the distinct potential to concentrate iodine. Justin et al³⁸ described 5 patients with PDTC, 4 of whom showed postoperative RAI localization and received therapeutic doses. Three of the 4 patients showed extrathyroidal localization, and 1 patient had resolution of metastatic disease. Currently the percentage of PDTCs having sufficient RAI concentration to allow postoperative RAI therapy is unknown. We recently reviewed our experience in treating patients with PDTC. Preliminary results showed that these tumors displayed up to 85% radioavidity. Although prospective evidence for its use and efficacy is not available, most authors advocate the use of RAI and L-thyroxine because these tumors display differentiated epithelial function with aggressive behavior, with high rates of regional and distant metastases.

The evidence for and against a role for adjuvant EBRT in PDTC is exclusively retrospective in nature, with varying criteria for patient selection that results in contradictory conclusions. EBRT is given as a local therapy to reduce the risk of local relapse; no improve-

Table 2. — Comparison of Clinical Characteristics of Well-Differentiated, Poorly Differentiated, and Anaplastic Thyroid Carcinomas at a Median Follow-Up of 43 Months: Memorial Sloan-Kettering Cancer Center Experience

Clinical Factor	WDTC (n = 15)	PDTC (n = 12)	ATC (n = 15)	P Value
Female sex	6 (40%)	9 (75%)	9 (60%)	.1
Age <45 years	4 (27%)	0 (0%)	1 (7%)	.05
Extrathyroidal extension	5 (33%)	8 (73%)	15 (100%)	<.0001
Tumor size >4 cm	2 (13%)	8 (73%)	9 (69%)	.0001
Lymph node metastasis	7 (47%)	7 (64%)	15 (100%)	.0007
Distant metastasis	0 (0%)	6 (50%)	13 (87%)	<.0001
5-year disease-free survival	91%	51%	0%	<.0001
5-year cause-specific survival	100%	70%	0%	<.0001
Overall survival	100%	70%	0%	<.0001

Reprinted from *Am J Pathol* 2002;161:1549-1556 with permission from the American Society for Investigative Pathology.

ment in overall survival has been documented.³⁹ No studies have specifically evaluated the use of EBRT in PDTC. Based on the characteristics of the tumor and the patient, EBRT may represent an added treatment modality. Patients with unresectable disease, incompletely excised tumors, and locoregional recurrences might benefit from EBRT.

Most data for the use of chemotherapy in thyroid cancer are based on studies performed for ATC. One study examined the in vitro chemosensitivity of primary cultures of 5 PDTCs.⁴⁰ Four tumors were resistant to doxorubicin, cisplatin, cyclophosphamide, etoposide, and carboplatin. Cells from one tumor were partially sensitive to doxorubicin. In vitro chemosensitivity testing may prevent the administration of ineffective chemotherapy. The use of chemotherapeutic agents for PDTC is still being investigated.

Due to the propensity of PDTC to recur and metastasize, patients with this disease need to be kept under close surveillance. Serial monitoring of TG levels, which is a key distinction between PDTC and ATC, can be helpful in detecting recurrences. Repeat RAI imaging, ultrasound, computed tomography scans, and magnetic resonance imaging are important in detecting and assessing the extent of disease. More recently the use of 18F-fluorodeoxyglucose (FDG) positron emission tomography (PET) in thyroid cancer has proven to be a valuable tool. Progressive dedifferentiation of thyroid tumors leads to underexpression of the sodium iodide symporter, decreasing the iodine concentrating ability and resulting in false-negative RAI scans. This has occurred in up to 20% of all differentiated metastatic thyroid lesions.⁴¹ Wang et al⁴² performed PET scans following surgery and RAI ablation on 37 patients with WDTC who had negative diagnostic RAI whole body scans during follow-up but an elevated TG. PET scans localized occult disease in 71% of these patients, with a positive predictive value of 92% and a negative predictive value of 93% and changing the clinical management in 19 of the 37 patients. Benign thyroid carcinoma and WDTC retain FDG poorly, whereas more malignant types (PDTC) appear to have a higher uptake of FDG. Further studies in 125 patients over 41 months found that the total volume of FDG-avid disease correlated with prognosis and was the strongest single risk factor predicting survival. PET scans serve as an excellent localization and prognostic study in patients with PDTC, who often have negative RAI scans and elevated TG levels.⁴²

Anaplastic Thyroid Cancer

ATC is the most aggressive and lethal form of thyroid cancer. Fortunately, it accounts for only 1% to 2% of all thyroid tumors.⁴³ ATC portends a dismal prognosis,

with a median survival of 4 to 12 months from the time of diagnosis.⁴⁴⁻⁴⁷ Long-term survivors are so rare that the diagnosis is questioned in reports describing 5-year survival rates.⁴⁸ The incidence of ATC has steadily decreased over the past few decades,⁴⁹ although the reason for this decline is not completely understood, and several factors may be involved. Some authors suggest that new diagnostic techniques can help distinguish previously described cases of ATC from lymphoma and medullary thyroid carcinoma.⁵⁰⁻⁵² Other authors have postulated that since ATC is more common in iodine-deficient areas, the decline could be due to iodine prophylaxis and improved socioeconomic status.^{53,54} A recent Swedish study, however, did not show any change in the incidence of ATC with the addition of iodine to their food supply.⁵⁴ ATC can occur concurrently with a variety of thyroid disorders, including WDTC.⁵⁵ Some have suggested that the increased surgical resection of the thyroid gland for a variety of conditions may contribute to the decline in ATC by potentially eliminating the transformation of WDTC to ATC.⁵⁶ Despite this decline, ATC usually has a fatal outcome, which warrants comprehensive understanding and management of this entity.

Pathology

The pathogenesis of ATC is not completely understood. Whether it arises de novo or from a preexisting WDTC is an area of controversy. We believe that it is probably both. The progression of WDTC to ATC has been well documented at a clinical and molecular level with the loss of the *p53* tumor suppressor gene.^{45,47,55-58} Furthermore, coexistence of WDTC and ATC with zones of transition have been well described. Demeter et al⁵⁶ found 76% of ATC had previous or concurrent thyroid disorders, with 47% related to WDTC. Some authors have suggested that all ATC contain foci of WDTC and that the inability to detect these foci is due to inadequate sectioning of the specimen.⁵⁹⁻⁶¹ Papillary thyroid carcinoma is the most common type of thyroid cancer associated with ATC; biologically aggressive variants such as tall cell are more common.⁶² Foci of PDTC are also common in ATC.²⁵ Recent genetic studies have identified the *BRAF* mutation as the most common mutation leading to the formation of papillary thyroid cancer.⁶³⁻⁶⁸ Several studies have now shown that some ATCs may be derived from *BRAF*-mutated papillary thyroid cancer, and targeted expression of *BRAF* in thyroid cells of transgenic mice results in papillary thyroid cancers that undergo dedifferentiation.^{69,70} This strengthens the theory that WDTC may dedifferentiate to ATC through intermediate forms. Understanding this progression might help identify valuable prognostic factors that can serve as potential therapeutic targets.

Grossly, ATCs are unencapsulated, tan-white, fleshy tumors that infiltrate into the surrounding soft tissues of

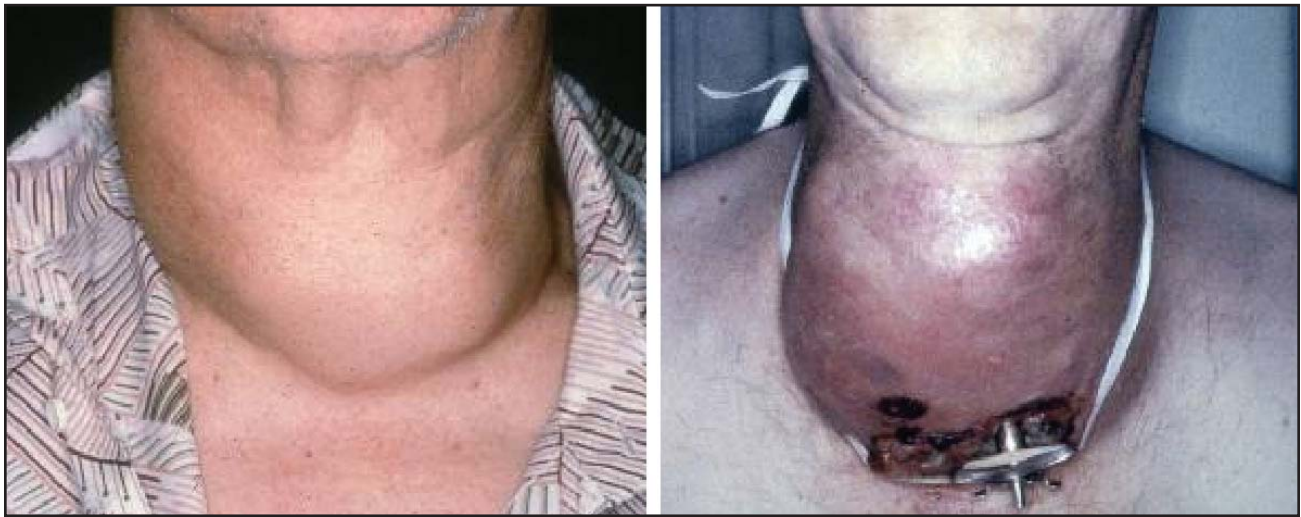

Fig 3. — Anaplastic thyroid carcinoma, showing the same patient in Fig 2 with rapidly enlarging, fixed mass. Tumor fungation is seen at the tracheostomy site.

the neck. Microscopically, three histologic patterns are commonly described: spindle, giant cell, and squamoid. There is no prognostic difference in these patterns. All three variants have numerous mitotic figures, with large areas of necrosis, hemorrhage, and vascular invasion.⁷¹ Unlike PDTC, these tumors often display p53 mutations and do not stain for TG.⁵⁸ Anaplastic cells typically do not have thyrotropin receptors, do not transport iodine, and do not produce TG.

The prognostic impact of the presence of small foci of ATC in WDTC has not been well studied. Some studies have reported improved outcomes in patients with only small foci of ATC; however, others report the same poor outcome as patients with large, rapidly growing tumors.^{72,73} As with PDTC, more aggressive therapy may be warranted in patients with WDTC containing anaplastic foci.

Diagnosis

The diagnosis of ATC is usually suspected on clinical examination and confirmed by FNAB or core biopsy. FNAB has been shown to be accurate in 90% of patients with ATC.^{57,74} Core biopsy is useful in narrowing the differential diagnosis and confirming ATC. Open biopsy can practically be eliminated; it is indicated only when clinical suspicion remains high and when FNAB and core biopsy are inadequate. Failure to obtain a diagnosis on FNAB or core biopsy may be secondary to sampling error or increased areas of necrosis, hemorrhage, or fibrosis.

ATC has been confused with lymphoma and poorly differentiated medullary thyroid carcinoma. These tumors, previously classified as small-cell ATC, carry a better prognosis and might account for the high survival reported in some ATC series.⁷⁵ For these reasons, both lymphoma and poorly differentiated medullary thyroid carcinoma need to be distinguished from ATC. A detailed history may help raise the suspicion of

lymphoma (ie, Hashimoto's thyroiditis, female gender). Core biopsies with immunohistochemical staining and flow cytometry analysis are valuable in this setting. Lymphomas stain for leukocyte-common antigen and do not have the marked cellular pleomorphism of ATC.⁵⁰⁻⁵² When considering the diagnosis of medullary thyroid cancer, a detailed family history is critical. A genetic workup looking for *RET* protooncogene mutations might be warranted in this setting. Medullary thyroid carcinoma can be distinguished from ATC by staining specifically for calcitonin.

Preoperative imaging is helpful in both staging and treatment planning. A thyroid scan is of no value since ATC does not take up RAI. Computed tomography scans and magnetic resonance imaging are useful in defining the local extent of disease and identifying distant metastases. PET scans are also useful in detecting distant disease since ATC is highly metabolic.⁷⁶

Clinical Characteristics

The peak incidence of ATC occurs in the 6th to 7th decade of life. The mean age at diagnosis is 55 to 65 years. Women comprise 55% to 77% of patients with ATC.^{45,47,55,77}

Although some series report incidentally discovered ATC in a thyroid nodule, most patients present with a rapidly growing, painful, low anterior neck mass that is often firm and fixed to underlying structures.^{44,45,78,79} The mean size of the mass at examination is 8 cm, ranging from 3 cm to 20 cm.^{47,77} Most patients demonstrate local compressive symptoms including dysphagia, dysphonia, stridor, dyspnea, and neck pain and tenderness (Fig 3). Regional nodal metastases and vocal cord paralysis are seen in up to 40% and 30%, respectively, of the patients with ATC.⁷⁷ Over 70% of patients with ATC have direct invasion of surrounding tissues, such as fat, trachea, muscle, esophagus, and larynx.⁸⁰ Systemic metastases occur in up to 75% of

patients, with lung being the most common site (80%), followed by bone (6% to 15%) and brain (5% to 13%).⁴⁴ Despite the high rate of synchronous metastases, death is usually related to extensive local disease with ultimate airway obstruction.

Treatment

Surgery: The role of surgery in ATC, whether it is removal of all gross disease or palliation, remains controversial. Patients often present at an advanced stage, making curative surgical resection not feasible. Most studies find that neither the extent of surgery nor the completeness of resection has a significant effect on survival.⁵⁵ Some studies suggest that in a select subset of patients with localized disease, survival can be improved by achieving complete resection of all gross disease.^{72,81-83} The incidence of regional metastases is high, and neck dissection should be performed for clinically evident disease. De Crevoisier et al⁸⁴ recently

reported high long-term survival in patients receiving radiotherapy and chemotherapy after complete gross removal of all tumor. The number of these cases is usually small. A recent consensus on the treatment of ATC suggests that total thyroidectomy is justified if cervical and mediastinal disease can be resected with limited morbidity.⁸⁵ Resection of vital structures, such as the larynx, pharynx, and esophagus, should be avoided.

One of the central issues in the management of ATC is palliation. Palliative management is meant to prevent death from asphyxiation. Securing a safe airway is a critical component of this effort. Airway management may be elective or emergent, depending on the patient's presentation. Airway obstruction occurs by one of three mechanisms: external compression of the trachea, intraluminal tumor extension, and bilateral vocal cord paralysis. External compression of the trachea is the most common cause of airway impairment in ATC. Patients with either stridor or rapid tumor

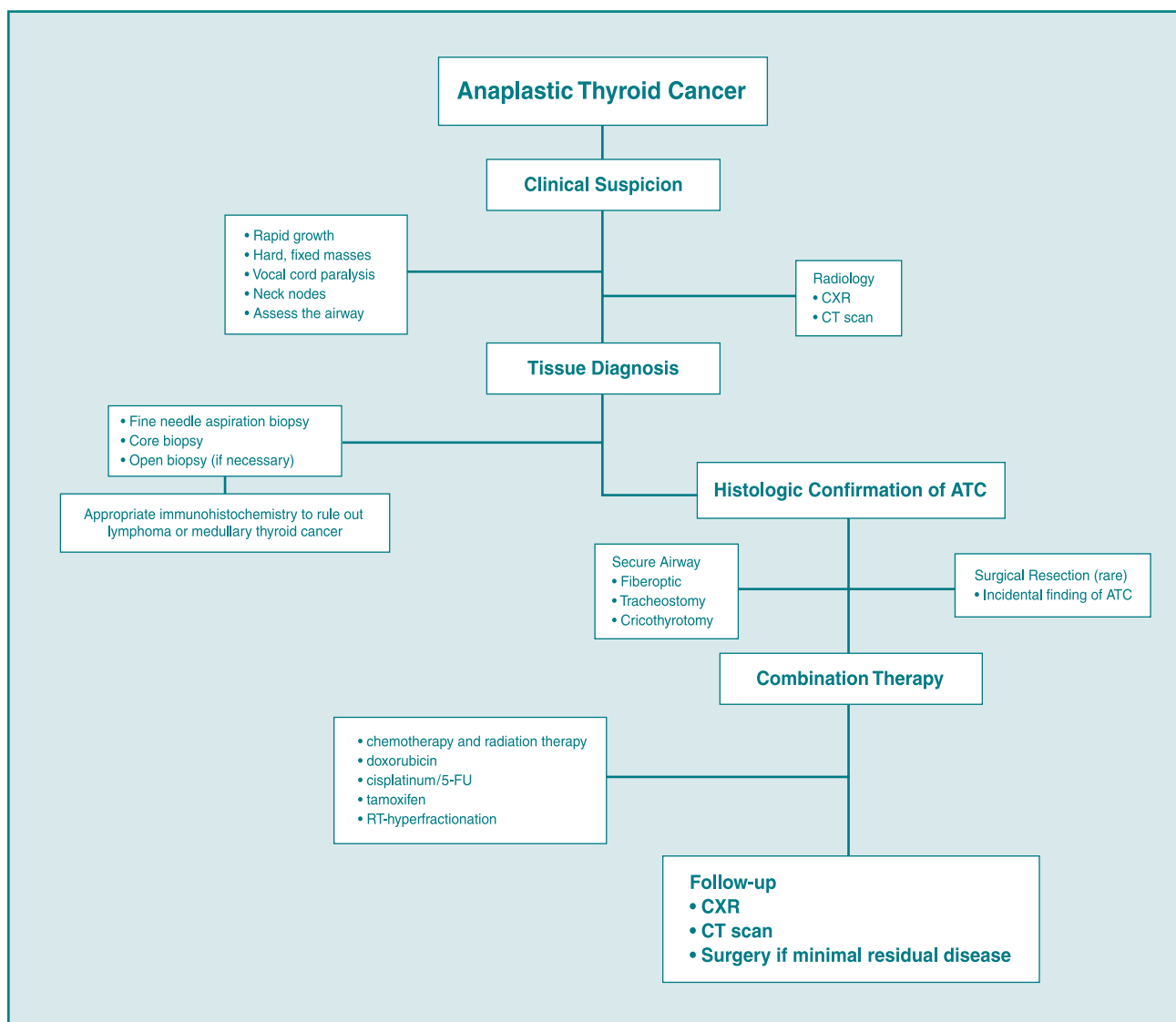


Fig 4. — Algorithm for managing anaplastic thyroid cancer.

growth should be considered for tracheostomy since further airway compromise can be expected. Computed tomography scans should be obtained to determine the extent of airway compromise and presence of intraluminal tumor. The patient should be taken to the operating room for secure airway management prior to performing the tracheostomy. Preoperative sedation should be avoided and the patient should be intubated under direct vision or fiberoptically. Once the airway is secured, the tracheotomy can be performed under more controlled conditions.⁸⁶ An extended-length tracheostomy tube is often necessary. In an emergent setting, a cricothyrotomy can be useful. A prophylactic tracheostomy is often difficult to perform and does not improve survival. It can be associated with increased morbidity due to healing problems and tumor fungation, and it might delay radiotherapy. A comprehensive discussion with the patient and family members is necessary to address the patient's needs appropriately.

Radiotherapy: Achieving local control is important since death from ATC is usually a consequence of uncontrolled local disease. The indications for EBRT range from providing palliation to improving survival. It is used either alone or in combination with surgery and/or chemotherapy. Although ATC is relatively radioresistant, some studies have shown palliative local control in 68% to 80% of patients.^{83,87-90} The timing, dose, and mode of delivery of EBRT remain controversial. Some investigators have tried hyperfractionated radiotherapy to keep up with the rapid doubling times of ATC.^{78,88-92} The efficacy of EBRT needs to be balanced with its toxicity. Reported complications include pharyngoesophagitis, tracheitis, and myelopathy.^{89,92} Patients undergoing EBRT spend a significant portion of their remaining life coping with the related morbidity. The effect of EBRT is limited, and most patients progress and ultimately die of their disease. In select cases, EBRT in combination with surgery and/or chemotherapy can improve short-term survival and provide some palliation.

Chemotherapy: Chemotherapy plays an important role in the management of ATC since the majority of patients present with or develop distant metastases. Most series studying the effects of chemotherapeutic agents on ATC have been unsuccessful in altering the fatal outcome of this disease.⁴⁹ Doxorubicin is the most frequently used drug. Monotherapy with doxorubicin demonstrated a response rate of approximately 20% with no evidence of a complete response.^{93,94} Combination therapy with cisplatin or bleomycin demonstrated little improvement in the clinical response.^{40,95,96} The recent addition of paclitaxel showed some improvement in response but did not alter the fatal outcome.⁹⁷⁻⁹⁹ The main limitation of all the combination therapies was drug toxicity.

Multimodality Therapy: The rationale of com-

bining treatment modalities stems from the failure of any one individual therapy. EBRT combined with surgery can improve local control, and chemotherapy combined with EBRT can increase the radiosensitivity of ATC.^{45,47,81,83,100} Controversy persists over the timing of chemoradiation in relation to surgery. Several authors believe that administering EBRT postoperatively provides a theoretical advantage by allowing radiation to treat a smaller tumor burden.^{45,47} Others have used the effects of radiation and chemotherapy preoperatively to allow for the potential resection of the tumor.^{78,82} A recent study suggested that primary chemoradiation followed by surgery had a positive impact on short-term survival.¹⁰¹ Despite the variable sequence of treatment, multimodality regimens currently offer the best hope for patients with ATC. Fig 4 represents our management of patients with ATC.

Future Directions

ATC remains one of the deadliest of human malignancies. Novel treatment strategies are necessary if we are to make any progress in treating ATC. Promising future directives include tumor suppressor gene therapy, induction of cell cycle arrest, and selective inhibition of certain proteins, thus inducing apoptosis. Blagosklonny et al¹⁰² showed that adenovirus-mediated *p53* tumor suppressor gene therapy increased the in vitro chemosensitivity of ATC to doxorubicin. Nagayama et al¹⁰³ showed similar results in vivo. Studies using bone morphogenetic protein (BMP-7) and bovine seminal ribonuclease have shown efficacy in treating ATC in vitro and in vivo.^{104,105} Several ongoing clinical trials are using vascular and growth factor-targeted therapies. Agents such as imatinib and combretastatin A4 phosphate are currently being used on protocol. More information regarding these and other trials can be found at www.clinicaltrials.gov. These studies hold promise for improved outcomes and help guide investigators in the search for better treatment strategies for patients with ATC.

Conclusions

Although PDTC and ATC make up a rare group of tumors, they account for a significant portion of the morbidity and mortality associated with thyroid cancer. It is important for clinicians to be able to recognize and differentiate these entities. Both of these tumors are more aggressive than WDTC. They have distinctive clinicopathologic features, and recognition of these histologic variants is important for appropriate management of these tumors. Surgery remains the mainstay of treatment for PDTC, whereas treatment for ATC is not so clear. Multimodality therapy is usually required to treat both of these rare tumors. Current investigations hold promise for better therapies in the future.

References

1. Shaha AR. Implications of prognostic factors and risk groups in the management of differentiated thyroid cancer. *Laryngoscope*. 2004;114:393-402.
2. Sakamoto A., Kasai N, Sugano H. Poorly differentiated carcinoma of the thyroid. A clinicopathologic entity for a high-risk group of papillary and follicular carcinomas. *Cancer*. 1983;52:1849-1855.
3. Carcangiu ML, Zampi G, Rosai J, et al. Poorly differentiated ("insular") thyroid carcinoma: a reinterpretation of Langhans' "wuchernde Struma." *Am J Surg Pathol*. 1984;8:655-668.
4. Nishida T, Katayama S, Tsujimoto M, et al. Clinicopathological significance of poorly differentiated thyroid carcinoma. *Am J Surg Pathol*. 1999;23:205-211.
5. Sobrinho-Simoes M, Sambade C, Fonseca E, et al. Poorly differentiated carcinomas of the thyroid gland: a review of the clinicopathologic features of a series of 28 cases of a heterogeneous, clinically aggressive group of thyroid tumors. *Int J Surg Pathol*. 2002;10:123-131.
6. Carcangiu ML, Bianchi S. Diffuse sclerosing variant of papillary thyroid carcinoma: clinicopathologic study of 15 cases. *Am J Surg Pathol*. 1989;13:1041-1049.
7. Pilotti S, Collini P, Manzari A, et al. Poorly differentiated forms of papillary thyroid carcinoma: distinctive entities or morphological patterns? *Semin Diagn Pathol*. 1995;12:249-255.
8. Sobrinho-Simoes M, Nesland JM, Johannessen JV. Columnar-cell carcinoma. Another variant of poorly differentiated carcinoma of the thyroid. *Am J Clin Pathol*. 1988;89:264-267.
9. Akslen LA, LiVolsi VA. Poorly differentiated thyroid carcinoma: it is important. *Am J Surg Pathol*. 2000;24:310-313.
10. Nikiforov YE, Erickson LA, Nikiforova MN, et al. Solid variant of papillary thyroid carcinoma: incidence, clinical-pathologic characteristics, molecular analysis, and biologic behavior. *Am J Surg Pathol*. 2001;25:1478-1484.
11. Nikiforov Y, Gnepp DR. Pediatric thyroid cancer after the Chernobyl disaster: pathomorphologic study of 84 cases (1991-1992) from the Republic of Belarus. *Cancer*. 1994;74:748-666.
12. Nikiforov Y, Gnepp DR, Fagin JA. Thyroid lesions in children and adolescents after the Chernobyl disaster: implications for the study of radiation tumorigenesis. *J Clin Endocrinol Metab*. 1996;81:9-14.
13. Yunta PJ, Ponce JL, Prieto M, et al. The importance of a tumor capsule in columnar cell thyroid carcinoma: a report of two cases and review of the literature. *Thyroid*. 1999;9:815-819.
14. Burman KD, Ringel MD, Wartofsky L, et al. Unusual types of thyroid neoplasms. *Endocrinol Metab Clin North Am*. 1996;25:49-68.
15. Livolsi VA. *Surgical Pathology of the Thyroid*. Philadelphia, Pa: Saunders; 1990.
16. Langhans T. Uber die epithelialen formen der malignen struma. *Virchows Arch A Pathol Anat*. 1907;189:69-188.
17. Hedinger CE. *Thyroid Cancer*. Berlin, New York: Springer; 1969.
18. Meissner WA, Warren S. *Tumors of the Thyroid Gland*. Washington, DC: Armed Forces Institute of Pathology; 1969.
19. Woolner LB, Beahrs OH, Black BM, et al. Classification and prognosis of thyroid carcinoma. A study of 885 cases observed in a thirty year period. *Am J Surg*. 1961;102:354-387.
20. Albareda M, Puig-Domingo M, Wengrowicz S, et al. Clinical forms of presentation and evolution of diffuse sclerosing variant of papillary carcinoma and insular variant of follicular carcinoma of the thyroid. *Thyroid*. 1998;8:385-391.
21. Papotti M, Botto Micca F, Favero A, et al. Poorly differentiated thyroid carcinomas with primordial cell component: a group of aggressive lesions sharing insular, trabecular, and solid patterns. *Am J Surg Pathol*. 1993;17:291-301.
22. Pilotti S, Collini P, Mariani L, et al. Insular carcinoma: a distinct de novo entity among follicular carcinomas of the thyroid gland. *Am J Surg Pathol*. 1997;21:1466-1473.
23. Hwang TS, Suh JS, Kim YI, et al. Poorly differentiated carcinoma of the thyroid retrospective clinical and morphologic evaluation. *J Korean Med Sci*. 1990;5:47-52.
24. Flynn SD, Forman BH, Stewart AF, et al. Poorly differentiated ("insular") carcinoma of the thyroid gland: an aggressive subset of differentiated thyroid neoplasms. *Surgery*. 1988;104:963-970.
25. Lam KY, Lo CY, Chan KW, et al. Insular and anaplastic carcinoma of the thyroid: a 45-year comparative study at a single institution and a review of the significance of p53 and p21. *Ann Surg*. 2000;231:329-338.
26. Machens A, Hinze R, Lautenschlager C, et al. Multivariate analysis of clinicopathologic parameters for the insular subtype of differentiated thyroid carcinoma. *Arch Surg*. 2001;136:941-944.
27. Takeuchi Y, Daa T, Kashima K, et al. Mutations of p53 in thyroid carcinoma with an insular component. *Thyroid*. 1999;9:377-381.
28. Killeen RM, Barnes L, Watson CG, et al. Poorly differentiated ("insular") thyroid carcinoma: report of two cases and review of the literature. *Arch Otolaryngol Head Neck Surg*. 1990;116:1082-1086.
29. van den Brekel MW, Hekkenberg RJ, Asa SL, et al. Prognostic features in tall cell papillary carcinoma and insular thyroid carcinoma. *Laryngoscope*. 1997;107:254-259.
30. Rodriguez JM, Parrilla P, Moreno A, et al. Insular carcinoma: an infrequent subtype of thyroid cancer. *J Am Coll Surg*. 1998;187:503-508.
31. Ashfaq R, Vuitch F, Delgado R, et al. Papillary and follicular thyroid carcinomas with an insular component. *Cancer*. 1994;73:416-423.
32. Sasaki A, Daa T, Kashima K, et al. Insular component as a risk factor of thyroid carcinoma. *Pathol Int*. 1996;46:939-946.
33. Pietribiasi F, Sapino A, Papotti M, et al. Cytologic features of poorly differentiated "insular" carcinoma of the thyroid, as revealed by fine-needle aspiration biopsy. *Am J Clin Pathol*. 1990;94:687-692.
34. Pilotti S, Collini P, Del Bo R, et al. A novel panel of antibodies that segregates immunocytochemically poorly differentiated carcinoma from undifferentiated carcinoma of the thyroid gland. *Am J Surg Pathol*. 1994;18:1054-1064.
35. Sywak M, Pasieka JL, Ogilvie T, et al. A review of thyroid cancer with intermediate differentiation. *J Surg Oncol*. 2004;86:44-54.
36. Wreesmann VB, Ghossein RA, Patel SG, et al. Genome-wide appraisal of thyroid cancer progression. *Am J Pathol*. 2002;161:1549-1556.
37. Decaussin M, Bernard MH, Adeleine P, et al. Thyroid carcinomas with distant metastases: a review of 111 cases with emphasis on the prognostic significance of an insular component. *Am J Surg Pathol*. 2002;26: 1007-1015.
38. Justin EP, Seabold JE, Robinson RA, et al. Insular carcinoma: a distinct thyroid carcinoma with associated iodine-131 localization. *J Nucl Med*. 1991;32:1358-1363.
39. Brierley JD, Tsang RW. External-beam radiation therapy in the treatment of differentiated thyroid cancer. *Semin Surg Oncol*. 1999;16:42-49.
40. Asakawa H, Kobayashi T, Komoike Y, et al. Chemosensitivity of anaplastic thyroid carcinoma and poorly differentiated thyroid carcinoma. *Anticancer Res*. 1997;17:2757-2762.
41. Wang W, Macapinlac H, Larson SM, et al. [18F]-2-fluoro-2-deoxy-D-glucose positron emission tomography localizes residual thyroid cancer in patients with negative diagnostic (131I) whole body scans and elevated serum thyroglobulin levels. *J Clin Endocrinol Metab*. 1999;84:2291-2302.
42. Wang W, Larson SM, Fazzari M, et al. Prognostic value of [18F] fluorodeoxyglucose positron emission tomographic scanning in patients with thyroid cancer. *J Clin Endocrinol Metab*. 2000;85:1107-1113.
43. Gilliland FD, Hunt WC, Morris DM, et al. Prognostic factors for thyroid carcinoma. A population-based study of 15,698 cases from the Surveillance, Epidemiology and End Results (SEER) program 1973-1991. *Cancer*. 1997;79:564-573.
44. Nel CJ, van Heerden JA, Goellner JR, et al. Anaplastic carcinoma of the thyroid: a clinicopathologic study of 82 cases. *Mayo Clin Proc*. 1985;60: 51-58.
45. Venkatesh YS, Ordenez NG, Schultz PN, et al. Anaplastic carcinoma of the thyroid: a clinicopathologic study of 121 cases. *Cancer*. 1990;66: 321-330.
46. Lo CY, Lam KY, Wan KY, et al. Anaplastic carcinoma of the thyroid. *Am J Surg*. 1999;177:337-339.
47. Tan RK, Finley RK III, Driscoll D, et al. Anaplastic carcinoma of the thyroid: a 24-year experience. *Head Neck*. 1995;17:41-48.
48. Schaefer CJ. Long-term survival in anaplastic thyroid cancer. *Md Med J*. 1988;37:873-874.
49. Pasieka JL. Anaplastic thyroid cancer. *Curr Opin Oncol*. 2003;15: 78-83.
50. Holting T, Moller P, Tschahargane C, et al. Immunohistochemical reclassification of anaplastic carcinoma reveals small and giant cell lymphoma. *World J Surg*. 1990;14:291-295.
51. Tobler A, Maurer R, Hedinger CE, et al. Undifferentiated thyroid tumors of diffuse small cell type. Histological and immunohistochemical evidence for their lymphomatous nature. *Virchows Arch A Pathol Anat Histopathol*. 1984;404:117-126.
52. Myskow MW, Krajewski AS, Dewar AE, et al. The role of immunoperoxidase techniques on paraffin embedded tissue in determining the histogenesis of undifferentiated thyroid neoplasms. *Clin Endocrinol (Oxf)*. 1986;24: 335-341.
53. Bakiri F, Djemli FK, Mokrane LA, et al. The relative roles of endemic goiter and socioeconomic development status in the prognosis of thyroid carcinoma. *Cancer*. 1998;82:1146-1153.
54. Pettersson B, Coleman MP, Ron E, et al. Iodine supplementation in Sweden and regional trends in thyroid cancer incidence by histopathologic type. *Int J Cancer*. 1996;65:13-19.
55. McIver B, Hay ID, Giuffrida DF, et al. Anaplastic thyroid carcinoma: a 50-year experience at a single institution. *Surgery*. 2001;130:1028-1034.
56. Demeter JG, De Jong SA, Lawrence AM, et al. Anaplastic thyroid carcinoma: risk factors and outcome. *Surgery*. 1991;110:956-963.
57. Ain KB. Anaplastic thyroid carcinoma: a therapeutic challenge. *Semin Surg Oncol*. 1999;16:64-69.
58. Fagin JA. Molecular genetics of human thyroid neoplasms. *Annu Rev Med*. 1994;45:45-52.
59. Carcangiu ML, Steeper T, Zampi G, et al. Anaplastic thyroid carcinoma

- noma: a study of 70 cases. *Am J Clin Pathol.* 1985;83:135-158.
60. Nishiyama RH, Dunn EL, Thompson NW. Anaplastic spindle-cell and giant-cell tumors of the thyroid gland. *Cancer.* 1972;30:113-127.
 61. Ibanez ML, Russell WO, Albores-Saavedra J, et al. Thyroid carcinoma: biologic behavior and mortality. Postmortem findings in 42 cases, including 27 in which the disease was fatal. *Cancer.* 1966;19:1039-1052.
 62. Moreno Egea A, Rodriguez Gonzalez JM, Sola Perez J, et al. Prognostic value of the tall cell variety of papillary cancer of the thyroid. *Eur J Surg Oncol.* 1993;19:517-521.
 63. Cohen Y, Xing M, Mambo E, et al. BRAF mutation in papillary thyroid carcinoma. *J Natl Cancer Inst.* 2003;95:625-627.
 64. Xing M. BRAF mutation in thyroid cancer. *Endocr Relat Cancer.* 2005;12:245-262.
 65. Xing M, Westra WH, Tufano RP, et al. BRAF mutation predicts a poorer clinical prognosis for papillary thyroid cancer. *J Clin Endocrinol Metab.* 2005;90:6373-6379. Epub 2005 Sep 20.
 66. Xing M, Vasko V, Tallini G, et al. BRAF T1796A transversion mutation in various thyroid neoplasms. *J Clin Endocrinol Metab.* 2004;89:1365-1368.
 67. Xu X, Quiros RM, Gattuso P, et al. High prevalence of BRAF gene mutation in papillary thyroid carcinomas and thyroid tumor cell lines. *Cancer Res.* 2003;63:4561-4567.
 68. Puxeddu E, Moretti S, Elisei R, et al. BRAF(V599E) mutation is the leading genetic event in adult sporadic papillary thyroid carcinomas. *J Clin Endocrinol Metab.* 2004;89:2414-2420.
 69. Quiros RM, Ding HG, Gattuso P, et al. Evidence that one subset of anaplastic thyroid carcinomas are derived from papillary carcinomas due to BRAF and p53 mutations. *Cancer.* 2005;103:2261-2268.
 70. Knauf JA, Ma X, Smith EP, et al. Targeted expression of BRAFV600E in thyroid cells of transgenic mice results in papillary thyroid cancers that undergo dedifferentiation. *Cancer Res.* 2005;65:4238-4245.
 71. Pasiaka JL. Anaplastic cancer, lymphoma, and metastases of the thyroid gland. *Surg Oncol Clin N Am.* 1998;7:707-720.
 72. Kobayashi T, Asakawa H, Umeshita K, et al. Treatment of 37 patients with anaplastic carcinoma of the thyroid. *Head Neck.* 1996;18:36-41.
 73. Pacheco-Ojeda LA, Martinez AL, Alvarez M, et al. Anaplastic thyroid carcinoma in Ecuador: analysis of prognostic factors. *Int Surg.* 2001;86:117-121.
 74. Us-Krasovec M, Golouh R, Auersperg M, et al. Anaplastic thyroid carcinoma in fine needle aspirates. *Acta Cytol.* 1996;40:953-958.
 75. Wolf BC, Sheahan K, DeCoste D, et al. Immunohistochemical analysis of small cell tumors of the thyroid gland: an Eastern Cooperative Oncology Group study. *Hum Pathol.* 1992;23:1252-1261.
 76. Poppe K, Lahoutte T, Everaert H, et al. The utility of multimodality imaging in anaplastic thyroid carcinoma. *Thyroid.* 2004;14:981-982.
 77. Ain KB. Anaplastic thyroid carcinoma: behavior, biology, and therapeutic approaches. *Thyroid.* 1998;8:715-726.
 78. Tennvall J, Lundell G, Hallquist A, et al. Combined doxorubicin, hyperfractionated radiotherapy, and surgery in anaplastic thyroid carcinoma: report on two protocols. The Swedish Anaplastic Thyroid Cancer Group. *Cancer.* 1994;74:1348-1354.
 79. Hadar T, Mor C, Shvero J, et al. Anaplastic carcinoma of the thyroid. *Eur J Surg Oncol.* 1993;19:511-516.
 80. Giuffrida D, Gharib H. Anaplastic thyroid carcinoma: current diagnosis and treatment. *Ann Oncol.* 2000;11:1083-1089.
 81. Haigh PI, Ituarte PH, Wu HS, et al. Completely resected anaplastic thyroid carcinoma combined with adjuvant chemotherapy and irradiation is associated with prolonged survival. *Cancer.* 2001;91:2335-2342.
 82. Nilsson O, Lindeberg J, Zedenius J, et al. Anaplastic giant cell carcinoma of the thyroid gland: treatment and survival over a 25-year period. *World J Surg.* 1998;22:725-730.
 83. Junor EJ, Paul J, Reed NS, et al. Anaplastic thyroid carcinoma: 91 patients treated by surgery and radiotherapy. *Eur J Surg Oncol.* 1992;18:83-88.
 84. De Crevoisier R, Baudin E, Bachelot A, et al. Combined treatment of anaplastic thyroid carcinoma with surgery, chemotherapy, and hyperfractionated accelerated external radiotherapy. *Int J Radiat Oncol Biol Phys.* 2004;60:1137-1143.
 85. Thyroid Carcinoma Task Force. AACE/AAES medical/surgical guidelines for clinical practice: management of thyroid carcinoma. American Association of Clinical Endocrinologists. American College of Endocrinology. *Endocr Pract.* 2001;7:202-220.
 86. Pellitteri PK, McCaffrey TV. *Endocrine Surgery of the Head and Neck.* Clifton Park, NY: Thomson Delmar Learning; 2003.
 87. Levendag PC, De Porre PM, van Putten WL. Anaplastic carcinoma of the thyroid gland treated by radiation therapy. *Int J Radiat Oncol Biol Phys.* 1993;26:125-128.
 88. Simpson WJ. Anaplastic thyroid carcinoma: a new approach. *Can J Surg.* 1980;23:25-27.
 89. Kim JH, Leeper RD. Treatment of anaplastic giant and spindle cell carcinoma of the thyroid gland with combination Adriamycin and radiation therapy: a new approach. *Cancer.* 1983;52:954-957.
 90. Kim JH, Leeper RD. Treatment of locally advanced thyroid carcinoma with combination doxorubicin and radiation therapy. *Cancer.* 1987;60:2372-2375.
 91. Tennvall J, Lundell G, Wahlberg P, et al. Anaplastic thyroid carcinoma: three protocols combining doxorubicin, hyperfractionated radiotherapy and surgery. *Br J Cancer.* 2002;86:1848-1853.
 92. Wong CS, Van Dyk J, Simpson WJ. Myelopathy following hyperfractionated accelerated radiotherapy for anaplastic thyroid carcinoma. *Radiother Oncol.* 1991;20:3-9.
 93. Shimaoka K, Schoenfeld DA, DeWys WD, et al. A randomized trial of doxorubicin versus doxorubicin plus cisplatin in patients with advanced thyroid carcinoma. *Cancer.* 1985;56:2155-2160.
 94. Ahuja S, Ernst H. Chemotherapy of thyroid carcinoma. *J Endocrinol Invest.* 1987;10:303-310.
 95. De Besi P, Busnardo B, Toso S, et al. Combined chemotherapy with bleomycin, adriamycin, and platinum in advanced thyroid cancer. *J Endocrinol Invest.* 1991;14:475-480.
 96. Williams SD, Birch R, Einhorn LH. Phase II evaluation of doxorubicin plus cisplatin in advanced thyroid cancer: a Southeastern Cancer Study Group Trial. *Cancer Treat Rep.* 1986;70:405-407.
 97. Ain KB, Egorin MJ, DeSimone PA, et al. Treatment of anaplastic thyroid carcinoma with paclitaxel: phase 2 trial using ninety-six-hour infusion. Collaborative Anaplastic Thyroid Cancer Health Intervention Trials (CATCHIT) Group. *Thyroid.* 2000;10:587-594.
 98. Yeung SC, Xu G, Pan J, et al. Manumycin enhances the cytotoxic effect of paclitaxel on anaplastic thyroid carcinoma cells. *Cancer Res.* 2000;60:650-656.
 99. Xu G, Pan J, Martin C, et al. Angiogenesis inhibition in the in vivo antineoplastic effect of manumycin and paclitaxel against anaplastic thyroid carcinoma. *J Clin Endocrinol Metab.* 2001;86:1769-1777.
 100. Sugino K, Ito K, Mimura T, et al. The important role of operations in the management of anaplastic thyroid carcinoma. *Surgery.* 2002;131:245-248.
 101. Besic N, Auersperg M, Us-Krasovec M, et al. Effect of primary treatment on survival in anaplastic thyroid carcinoma. *Eur J Surg Oncol.* 2001;27:260-264.
 102. Blagosklonny MV, Giannakakou P, Wojtowicz M, et al. Effects of p53-expressing adenovirus on the chemosensitivity and differentiation of anaplastic thyroid cancer cells. *J Clin Endocrinol Metab.* 1998;83:2516-2522.
 103. Nagayama Y, Yokoi H, Takeda K, et al. Adenovirus-mediated tumor suppressor p53 gene therapy for anaplastic thyroid carcinoma in vitro and in vivo. *J Clin Endocrinol Metab.* 2000;85:4081-4086.
 104. Franzen A, Heldin NE. BMP-7-induced cell cycle arrest of anaplastic thyroid carcinoma cells via p21(CIP1) and p27(KIP1). *Biochem Biophys Res Commun.* 2001;285:773-781.
 105. Kotchetkov R, Cinatl J, Krivtchik AA, et al. Selective activity of BS-RNase against anaplastic thyroid cancer. *Anticancer Res.* 2001;21:1035-1042.