



Sofia Cáceres. *El Sueño Profundo I (The Deep Dream I)*. Oil on table, 48" × 96".

Aggressive surgical resection of pancreatic neuroendocrine tumors may improve symptomatic disease and overall survival in selected patients.

Aggressive Surgical Resection in the Management of Pancreatic Neuroendocrine Tumors: When Is It Indicated?

Pamela J. Hodul, MD, Jonathan R. Strosberg, MD, and Larry K. Kvols, MD

Background: Pancreatic neuroendocrine tumors (PNETs) comprise a heterogeneous group of neoplasms for which treatment is variable, depending on the clinical stage. Despite this diversity, surgery remains the gold standard in the management of PNETs. This paper discusses whether aggressive surgical intervention is indicated for PNETs and investigates what prognostic factors may assist in predicting which patients with invasive disease will benefit most from surgical intervention.

Methods: A review was conducted of large surgical series reported in the English literature over the last 10 years as they pertain to current surgical intervention in PNETs and of prognostic factors related to surgical outcome and survival.

Results: Improved survival can be achieved with aggressive surgical management of PNETs. The presence of hepatic metastases is not a contraindication to surgical resection of the primary PNET. Results of series that reported prognostic factors are heterogeneous.

Conclusions: Aggressive surgical resection for selected individuals with PNETs can be performed safely and may improve both symptomatic disease and overall survival. Consideration for resection of primary PNETs should be given to patients with treatable hepatic metastases. Prognostic indices such as tumor differentiation and ability to achieve R0/R1 resection have been linked to survival outcome in PNETs and should be considered when planning aggressive surgical management for this disease.

Introduction

Pancreatic neuroendocrine tumors (PNETs) are a rare clinical entity with a variable natural history. Traditionally, their incidence has been reported as 0.4 per 100,000 persons, with PNETs constituting 2% to 4% of all pancreatic neoplasms.^{1,2} However, more recent studies suggest that the number of newly diagnosed PNETs may actually be on the rise due to increased incidental detection on radiographic imaging.³ As has been well established, these neoplasms can present as either

From the Gastrointestinal Tumor Program, Departments of Surgery (PJH), Medical Oncology (JRS), and Neuroendocrine Oncology (LKK) at the H. Lee Moffitt Cancer Center & Research Institute, Tampa, Florida.

Submitted July 10, 2008; accepted August 4, 2008.

Address correspondence to Pamela J. Hodul, MD, Gastrointestinal Tumor Program, WCB-GI PROG, Moffitt Cancer Center, 12902 Magnolia Drive, Tampa, FL 33612. E-mail: pamela.hodul@moffitt.org

Abbreviations used in this paper: PNETs = pancreatic neuroendocrine tumors, HAE = hepatic artery embolization.

nonfunctional tumors or as functional entities related to clinical syndromes of hormonal excess with distinct metabolic and clinical manifestations; they can be sporadic or related to familial syndromes such as multiple endocrine neoplasia syndrome type 1 (MEN-1); and their clinical course is relatively indolent, despite the fact that the majority of PNETs are malignant.

Surgery has been the focus of therapy for PNETs as it currently represents the only chance for cure. At presentation, resectability rates as high as 65% have been reported.⁴ Despite the initial successes for surgical intervention, 50% to 80% of these neoplasms will recur locally or metastasize. Additionally, another third of patients will present with metastases at initial presentation. Recent studies suggest that surgical intervention for PNETs metastatic to the liver may be indicated for select patients.^{5,6}

Despite the fact that it has generally been agreed upon that surgical therapy for PNETs is advantageous, determining which patients who exhibit malignant tumors will benefit from radical surgical intervention is less clear. Perhaps this confusion lies in the interpretation of single-institutional retrospective reviews that report on outcomes in heterogeneous populations exhibiting differences in disease burdens. These studies tend to be all-inclusive, combining benign and malignant tumors, functional and nonfunctional tumors, and poorly and well-differentiated histologies. Additionally, patients with aggressive disease have often received nonsurgical therapies either prior to or in addition to surgical resection, which makes the benefits of surgical intervention difficult to interpret. Due to the complex biological behavior of these tumors, indolent nature, and small numbers, conducting prospective randomized treatment trials regarding aggressive surgical therapies for PNETs will be difficult.

In this paper, we review the current indications and results of surgical intervention for PNETs and consider several possible prognostic factors that will allow us to propose an aggressive surgical treatment strategy in select patients.

The Impact of Surgical Resection on Primary PNETs

Indications and goals for surgical resection of primary PNETs include curative intent and relief from hormonally active tumors or those causing symptoms related to mass effect. Typical resections may consist of simple enucleations or segmental or radical pancreatic resections (pancreaticoduodenectomy, distal resection, or total pancreatectomy with or without vascular reconstruction of the portal-mesenteric vein) or en bloc removal of adjacent organs. Several studies have reported successful aggressive resections with acceptable morbidity and mortality (Table 1).⁷⁻¹⁶ Overall sur-

vival of resected PNETs was on average 40% to 75% in these studies compared with 46% for locally advanced nonresectable PNETs.¹⁷

Nonfunctional tumors account for 35% to 52% of PNETs, and nearly 92% are malignant with clinical presentations that are similar to exocrine pancreatic adenocarcinomas, which are more common.¹⁸⁻²⁰ This may be related to a delay in diagnosis due to lack of hormonal or clinical symptoms, usually by 4 to 6 years. Fortunately, resectability rates are higher and survival is significantly greater than its exocrine counterpart.^{19,21} Gullo et al²⁰ and others^{12,21} have reported improved survival in patients undergoing resection of nonfunctioning PNETs compared with those who did not undergo surgical intervention. Patients with relatively small tumor burden and absence of liver metastases who undergo surgical resection have a reported median survival of approximately 7 years; this is in comparison to patients with locally advanced unresectable disease who have a median survival of 5.2 years.^{17,20,21} Overall survival for completely resected nonfunctioning PNETs vs functional PNETs is reportedly similar (45% 5-year survival rate for both groups).¹³

Although the recurrence or the development of metastases following complete resection of invasive PNETs is reported to be 45% to 75%, the indolent nature of these tumors and prolonged overall survival justifies aggressive surgical intervention. Until more effective multimodality therapies are developed, such as novel targeted cytotoxic agents or radiologic interventions, survival will be limited by the completeness of surgical resection achieved.

Consideration of Cytoreductive Surgery for PNETs

From an oncologic viewpoint, cytoreductive surgery infers that at least 90% of tumor burden is eradicated. Efforts at debulking less than this amount rarely achieve the symptomatic relief and survival benefits afforded by more aggressive resections in PNETs.

Chamberlain et al⁵ reviewed 85 cases of hepatic metastasectomies for neuroendocrine tumors that reported 5-year survival rates of 50% and 76% for patients treated with hepatic artery embolization (HAE) and surgery, respectively. Thirty-day mortality rates were similar for the two groups. These findings demonstrate a significant survival advantage to historical controls, with untreated liver metastases having a 5-year survival rate of only 20% to 30%.^{22,23} Others have demonstrated similar 5-year survival rates of 72% to 81% with aggressive surgical resection of liver metastases, but they caution that patients with more extensive hepatic disease had a more limited survival.^{6,22-24} Furthermore, with aggressive surgical debulking, symptomatic relief can be achieved in the majority of patients with functional PNETs.^{25,26} Survival benefit of

cytoreductive surgery has been observed in both functional and nonfunctional PNETs compared with nonresectable controls.^{5,8,17,23,24,27}

Combined Resection of Primary and Metastatic Disease

Simultaneous resection of both the primary tumor and hepatic metastases can be performed in selected patients with acceptable morbidity and mortality. Unfortunately, at diagnosis, this is feasible in less than 20% of patients due to the high percentage of multifocal and bilateral metastases. When achievable, the 5-year actuarial survival rate is 73%.^{5,6,27}

House et al²⁸ performed synchronous liver metastasectomy and pancreatic resection in 26 of 31 patients. No operative or perioperative deaths occurred, and operative morbidity was reported as 25%. The 5-year survival rate for these patients was 65%, with 3 survivors alive > 10 years. This was significantly greater than the 5-year survival rate of patients with unresectable liver metastases, which was 20%.

Sarmiento et al²⁹ also reported their series of 23 patients undergoing concurrent pancreatic and metas-

tatic liver resections. Again, no perioperative deaths occurred, and major complications occurred in only 18% of patients. The reported 5-year survival rate was 71%; however, the recurrence-free or progression-free survival rate was only 5% at 5 years. Others have reported similar outcomes suggesting that concurrent resection of primary PNETs and liver metastasis can be achieved with similar morbidity and mortality rates to resection of primary PNETs or liver metastasectomy alone.¹⁶

Indications for Surgical Resection of Primary PNETs With Nonresectable Metastatic Disease

Liver metastases develop in roughly 46% to 93% of patients with neuroendocrine tumors.^{5,30} Resection for cure is possible in less than 20% of these patients.^{5,31} In light of these statistics, it is reasonable to assume that treatment strategies are eventually aimed at controlling the symptomatic and growth effects of hepatic metastases in the majority of patients. Effective control of unresectable hepatic metastasis by HAE, surgical debulking and/or radiofrequency ablation (RFA), chemotherapy, and radiolabeled peptide receptor therapy has

Table 1. — Results of Aggressive Surgical Resection for PNETs in Selected Studies

Author	No. of Patients	F/NF/M	Grades	No. of Synchronous Liver Metastases Resected	No. of Patients With Nonresectable Liver Metastasis	Morbidity	Mortality	5-Year Survival Rate for Malignant Tumors	Median Follow-Up (mos)
Phan et al ⁷ 1998	125	M	—	9	—	43%	2.8%	49%	55
Bartsch et al ⁸ 2000	18	NF	16 WD 2 PD	1	1	44%	16.6%	65%	56
Norton et al ⁹ 2003	20	M	—	8	5	30%	0%	80% ^{**}	19
Kazanjan et al ¹⁰ 2006	70	M	—	4	0	30%	0%	77%	50
Teh et al ¹¹ 2007	33	M	—	1	5	36%	3%	36%	44
Bahra et al ¹² 2007	19	M	—	1	0	10.5%	0%	26%	65
Nguyen et al ¹³ 2007	73	M	—	22	31	27%	0%	44%	48
Schurr et al ¹⁴ 2007	62	M	54 WD 8 PD	7	9	—	—	49%	30.5
Fischer et al ¹⁵ 2008	118	M	105 WD 13 PD	6	23	36.4%	3.4%	44%	19.8
Bonney et al ¹⁶ 2008	12	M*	9 WD 3 PD	3	0	25%	8%	73.3%	41

F = functional, NF = nonfunctional, M = mixed (benign/malignant/functional/nonfunctional tumors included), WD = well differentiated or low grade, PD = poorly differentiated or high grade.

(—) indicates not reported.

* Malignant tumors only.

** Actuarial overall survival rate for mixed population.

been reported.³²⁻³⁹ However, metastatic disease exists at presentation in up to one-third of patients with PNETs. Removal of the primary tumor in the presence of bulky hepatic metastases is often viewed as a contraindication to surgical resection.²⁹

Survival in patients presenting with neuroendocrine liver metastases is often measured in years rather than months.⁴⁰ These patients rarely suffer severe hepatic dysfunction resulting in death due to their bulky liver disease.⁵ On the contrary, many of these patients will experience serious complications related to the unresected primary tumor. These symptoms may include biliary obstruction, gastric outlet obstruction, abdominal pain, or gastrointestinal hemorrhage.^{17,27,41} Solorzano et al¹⁷ reported that 9% of patients experienced complications related to the primary tumor and had an average of two hospital admissions before death when the primary tumors were not resected. Tumors located in the tail of the pancreas may also cause problems related to bleeding from gastric varices.⁴²⁻⁴⁴ At our institute, 2 patients who recently presented with life-threatening bleeding gastric varices secondary to bulky nonresectable primary disease were treated by splenic

arterial embolization, which resulted in complete resolution of their symptoms (Fig 1).

Hung et al²⁷ reported their results of a prospective study with resection of the symptomatic primary tumors followed by treatment of unresectable hepatic metastases by lanreotide and HAE in patients with PNETs. There were no mortalities, and morbidity was 23% related to pancreatic fistula. No evidence of disease progression was noted in 61% of the patients, and 92% had no local recurrence at a mean follow-up of 26 months. Numbers were too small to evaluate whether resection of the primary tumor affected survival. Improved quality of life was reported in > 90% of the patients. Bartsch et al⁸ also support aggressive resection for asymptomatic nonfunctioning PNETs despite hepatic metastases, with the observation that 36% to 100% of patients present with potentially resectable disease.

In light of the fact that the disease course in patients with PNETs and liver metastases can be prolonged, serious consideration should be given to the resection of the pancreatic primary. It is our opinion that patients with treatable and responsive liver metastases should be given consideration for removal of their

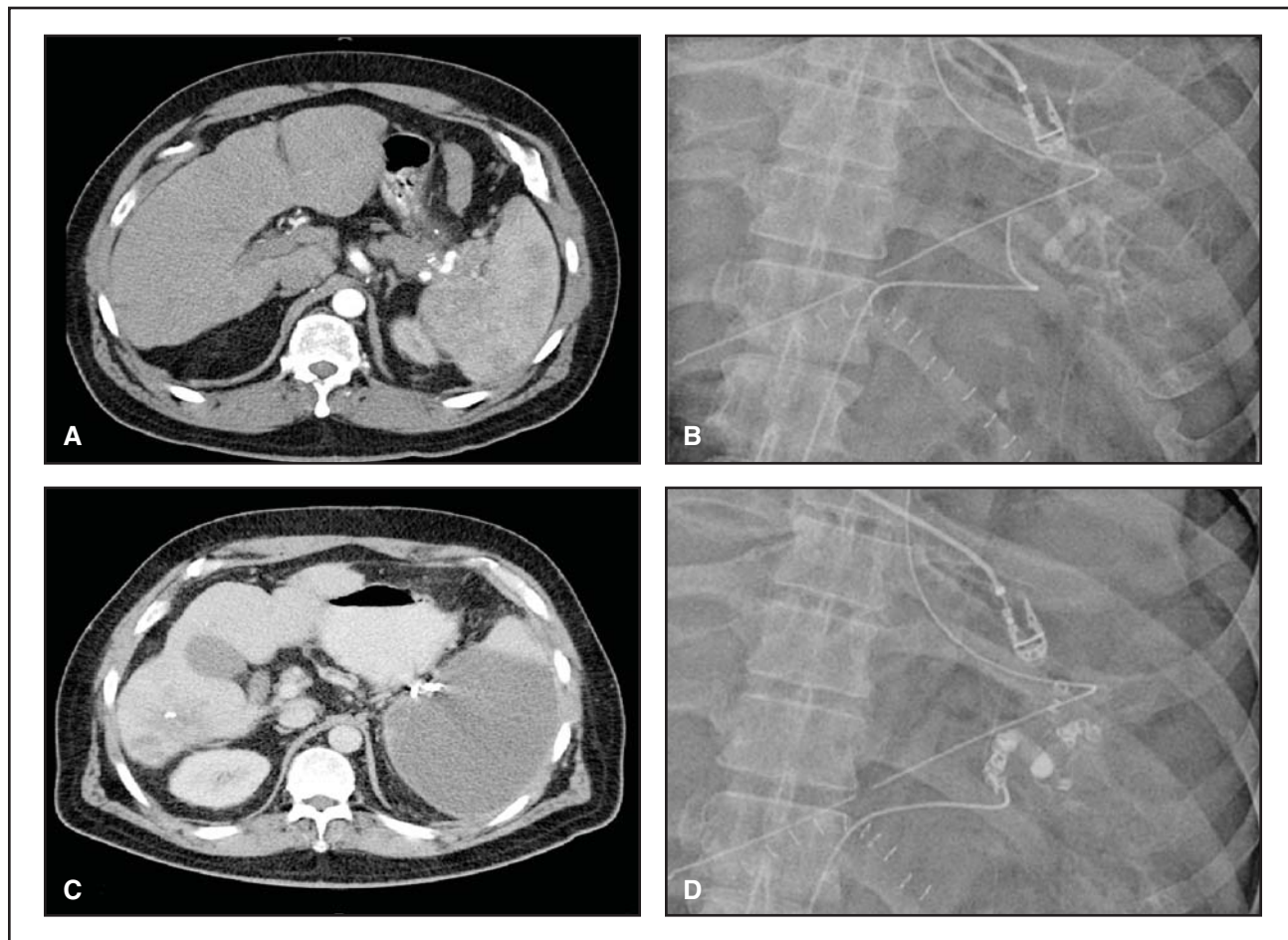


Fig 1. — Unresectable PNET causing bleeding gastric varices. A 57-year-old man with glucagonoma and liver metastases (A-B) controlled with hepatic artery embolization presented with bleeding gastric varices. Medically unfit to endure surgery (C-D), he was treated with splenic artery embolization with complete resolution of his symptoms. Postembolization CT demonstrates nearly complete infarction of the spleen.

primary disease, regardless of symptoms. Waiting for complications to arise significantly diminishes the chances for resection and symptomatic resolution.

The Role of Neoadjuvant Therapy in the Treatment of PNETs

Trials of cytotoxic chemotherapy in advanced PNETs have established response rates of 39% to 69% with combinational streptozocin, doxorubicin, and 5-fluorouracil and a response rate of 45% with temozolomide combined with thalidomide.⁴⁵⁻⁴⁸ The majority of these studies were undertaken in patients with diffuse hepatic metastases with or without unresected primary disease with palliative intent. Response rates were best in patients not previously exposed to other chemotherapy regimens.

At our institution, patients with bulky liver metastases with or without resectable primary disease that has a significant response to chemotherapy and/or HAE or to radiopeptide therapy are considered for aggressive surgical therapy if at least 90% of their disease can be controlled (Fig 2). Most recently, we reported a 71%

response rate in metastatic PNETs with a combination of capecitabine and temozolomide.⁴⁹ Several of these patients subsequently underwent complete surgical resection of their disease. In another investigation, Strosberg et al⁵⁰ demonstrated an objective response rate of 80% in locally advanced unresectable pancreatic neuroendocrine disease using concurrent infusional 5-fluorouracil along with induction and consolidation chemotherapy of streptozocin and doxorubicin. Although none of these patients have undergone surgical resection at our institution after treatment, it does suggest a potential role for neoadjuvant chemoradiation in the treatment of borderline PNETs.

Currently, a bias exists for aggressive surgical therapy for advanced well-differentiated PNETs; however, a recent report from Sørbye et al⁵¹ suggests that advanced poorly differentiated PNETs responsive to chemotherapy should also be considered. They report a 5-year survivor with poorly-differentiated carcinoma that responded to neoadjuvant cisplatin and etoposide who underwent complete surgical resection of the primary and liver metastases.

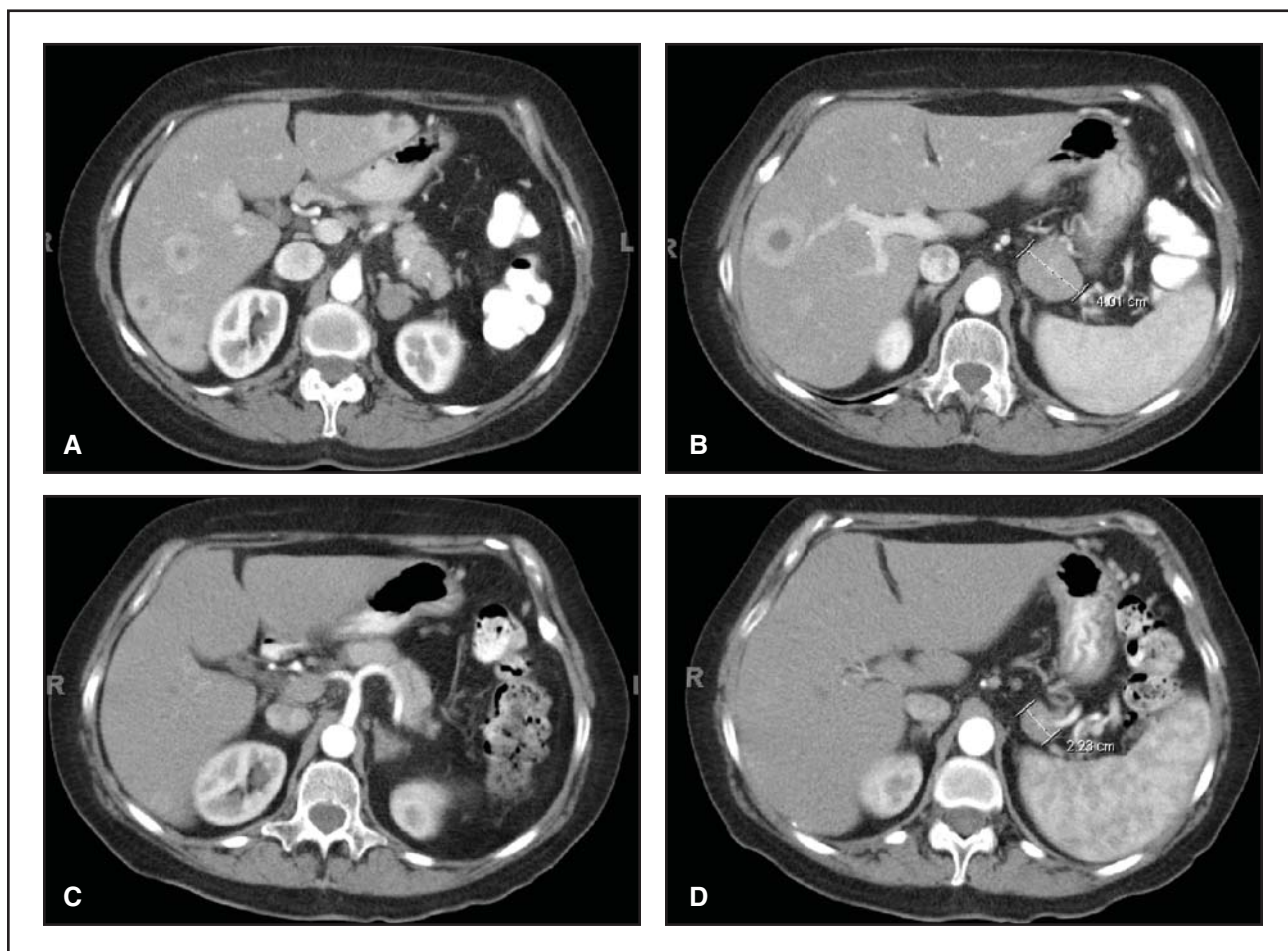

Fig 2. — Response to neoadjuvant chemotherapy. A 62-year-old woman with nonfunctioning pancreatic endocrine carcinoma and bilobar liver metastases (A-B) received preoperative chemotherapy with (C-D) significant response at all sites. She subsequently had resection of the primary tumor as well as combinational treatment of resection and radiofrequency ablation of her liver metastases with 100% eradication of her disease. She is alive and well 6 months postoperatively without recurrence.

Prognostic Factors Influencing Surgical Decision Making

No discussion regarding a proposal for aggressive surgical intervention for PNETs is complete without addressing prognostic factors that may influence surgical decision making and candidate selection. Several reports have examined these variables based on institutional review of surgical patients. Although results are heterogeneous, a few generalized guidelines can be concluded.

Bilimoria et al⁵² used the National Cancer Data Base to identify 3,851 patients who underwent pancreatic resection of PNETs. In this review, the 5-year overall survival rate was 59.3%, with the 5-year survival rate for neuroendocrine carcinomas reported as 58.3%. Patients with tumors < 4 cm had a better 5-year survival rate than patients with tumors > 4 cm (68% vs 54.9%, $P < .0001$). Those with node-negative tumors had better survival than those with nodal involvement (60.2% vs 53.6%, $P = .02$). Presence of liver or nonhepatic metastases negatively impacted 5-year survival. Patients

with well- to moderately differentiated tumors had a better 5-year survival rate than those with poorly differentiated tumors (63.9% vs 28%, $P < .0001$). The survival rate was worse for individuals with grossly positive margins compared to those with negative or microscopically positive disease (25% vs 57%–61.3%, $P < .001$). However, on multivariate analysis, only age > 55 years, poorly differentiated grade, presence of distant metastases, lack of clinical syndromes related to the primary, and resections requiring pancreaticoduodenectomy were found to be negative predictors of survival after resection of PNETs. Tumor size, lymph node involvement, margin status, adjuvant chemotherapy, and hospital volume were not associated with survival.

Several other studies have reported on prognostic factors that affected survival after resection for PNETs (Table 2).^{3,7,10,12-16,29,53,54} The majority of these studies would agree that the finding of lymph node-positive disease does not preclude resection and does not significantly affect survival.^{10,12,15,16,54} Functionality of the

Table 2. — Prognostic Factors Associated With Survival Outcome for PNETs in Selected Studies

	No. of Patients	Analysis	Lymph Nodes Positive	Functional vs Nonfunctional Tumor	Tumor Size	Presence of Liver or Distant Metastases	Age of Patient	Grade	Angiolymphatic Invasion Present	Resection Margins Positive
Phan et al ⁷ 1998	125	Univariate	–	ND	–	–	–	–	–	Yes
Sarmiento et al ²⁹ 2002	23	Univariate	–	–	–	–	–	–	–	ND
Kazanjan et al ¹⁰ 2006	70	Univariate	ND	–	–	–	–	–	Yes	ND
Bloomston et al ⁵³ 2006	120	Multivariate	–	–	–	–	–	WD > PD**	–	Yes
Chung et al ⁵⁴ 2007	22	Multivariate	ND	–	ND	–	ND	ND	–	Yes
Vagefi et al ³ 2007	168	Univariate	–	ND	–	–	–	–	–	–
Bahra et al ¹² 2007	19	Multivariate	ND	–	Yes†	–	–	–	–	–
Nguyen et al ¹³ 2007	73	Univariate	–	ND	–	–	–	–	–	–
Schurr et al ¹⁴ 2007	62	Univariate	Yes	–	–	Yes	–	–	–	Yes
Fischer et al ¹⁵ 2008	118	Multivariate	ND	F > NF*	ND	ND	ND	–	–	ND
Bonney et al ¹⁶ 2008	12	Univariate	ND	ND	ND	–	ND	WD > PD**	Yes	ND

ND = no statistically significant difference, Yes = variable was found to adversely affect survival outcome, WD = well differentiated or low grade, PD = poorly differentiated or high grade, F = functional, NF = nonfunctional.

(–) indicates no comment was made on this particular variable.

* Functional tumors had better overall survival compared with nonfunctional tumors.

** Well-differentiated or low-grade tumors had better overall survival compared with poorly differentiated or high-grade tumors.

† Tumors < 2 cm in size had improved overall survival compared with tumors > 2 cm.

tumor also does not seem to be a negative prognostic factor.^{3,7,13,16} However, these studies may be biased toward resection of early nonfunctional tumors incidentally found on radiologic imaging since most present at an advanced stage due to lack of symptoms. Age of the patient also does not seem to be a significant factor as long as the patient is medically fit to endure surgical resection.^{15,16,54} Most physicians, however, would give consideration to tumor grade when contemplating surgical intervention for poorly differentiated histologies. In general, patients with poorly differentiated or high-grade tumors generally do worse than patients with well-differentiated or low-grade neoplasms. In fact, these patients experience a higher likelihood of recurrence and shorter disease-free interval than their well-differentiated counterparts.^{16,53} Surprisingly, the presence of positive margins after surgical resection did not always negatively impact survival, as demonstrated by Bilimoria et al⁵² and others.^{10,15,16,29} Most of the R1 and R2 resections were not necessarily related to the primary tumor but rather were related to residual tumor burden within the liver, with the majority of these patients receiving additional therapy either medically or by radiographic means. In general, it is not good surgical principle to debulk the primary tumor, leaving gross disease behind due to increased risk of peritoneal seeding and tumor spread with no additional survival benefit.

In summary, patients of good functional capacity regardless of age, tumor size, tumor functionality, or presence of lymph node disease should be considered for aggressive surgical resection of the primary if at least an R0/R1 resection can be achieved with minimal morbidity. Patients with liver metastases should be considered for surgical intervention in cases of cytoreductive surgery when removal of > 90% of tumor burden can be accomplished or when control of hepatic metastases can readily be achieved by HAE, radiolabeled therapy, or the use of cytotoxic agents. However, consideration should be given to nonsurgical management for poorly differentiated and high-grade histologies with large tumor burden when recurrence is frequent and long-term survival uncommon.

Conclusions

A review of the current literature supports aggressive surgical resection for PNETs, even in advanced disease. However, the extent of radical surgery should be determined on an individual basis, with consideration given to a multidisciplinary approach that is focused at experienced, high-volume centers. An appreciation and understanding of each individual's tumor biology based on prognostic indicators and response to therapies should guide the surgeon as to the indications and goals of surgical intervention. Furthermore, until multicenter randomized multimodality treatment studies

are performed, optimization of the treatment for metastatic PNETs is deferred to individual institutions and the physicians focused on their treatment.

Disclosures

No significant relationship exists between the authors and the companies/organizations whose products or services may be referenced in this article.

References

1. Eriksson B, Oberg K. Neuroendocrine tumours of the pancreas. *Br J Surg.* 2000;87(2):129-131.
2. Oberg K, Eriksson B. Endocrine tumours of the pancreas. *Best Pract Res Clin Gastroenterol.* 2005;19(5):753-781.
3. Vagefi PA, Razo O, Deshpande V, et al. Evolving patterns in the detection and outcomes of pancreatic neuroendocrine neoplasms: the Massachusetts General Hospital experience from 1977 to 2005. *Arch Surg.* 2007;142(4):347-354.
4. Grant CS. Surgical management of malignant islet cell tumors. *World J Surg.* 1993;17(4):498-503.
5. Chamberlain RS, Canes D, Brown KT, et al. Hepatic neuroendocrine metastases: does intervention alter outcomes? *J Am Coll Surg.* 2000;190(4):432-445.
6. Chen H, Hardacre JM, Uzar A, et al. Isolated liver metastases from neuroendocrine tumors: does resection prolong survival? *J Am Coll Surg.* 1998;187(1):88-92; discussion 92-93.
7. Phan GQ, Yeo CJ, Hruban RH, et al. Surgical experience with pancreatic and peripancreatic neuroendocrine tumors: review of 125 patients. *J Gastrointest Surg.* 1998;2(5):472-482.
8. Bartsch DK, Schilling T, Ramaswamy A, et al. Management of non-functioning islet cell carcinomas. *World J Surg.* 2000;24(11):1418-1424.
9. Norton JA, Kivlen M, Li M, et al. Morbidity and mortality of aggressive resection in patients with advanced neuroendocrine tumors. *Arch Surg.* 2003;138(8):859-866.
10. Kazanjian KK, Reber HA, Hines OJ. Resection of pancreatic neuroendocrine tumors: results of 70 cases. *Arch Surg.* 2006;141(8):765-769; discussion 769-770.
11. Teh SH, Deveney C, Sheppard BC. Aggressive pancreatic resection for primary pancreatic neuroendocrine tumor: is it justifiable? *Am J Surg.* 2007;193(5):610-613; discussion 613.
12. Bahra M, Jacob D, Pascher A, et al. Surgical strategies and predictors of outcome for malignant neuroendocrine tumors of the pancreas. *J Gastroenterol Hepatol.* 2007;22(6):930-935. Epub 2007 Apr 19.
13. Nguyen SQ, Angel LP, Divino CM, et al. Surgery in malignant pancreatic neuroendocrine tumors. *J Surg Oncol.* 2007;96(5):397-403.
14. Schurr PG, Strate T, Rese K, et al. Aggressive surgery improves long-term survival in neuroendocrine pancreatic tumors: an institutional experience. *Ann Surg.* 2007;245(2):273-281.
15. Fischer L, Kleeff J, Esposito I, et al. Clinical outcome and long-term survival in 118 consecutive patients with neuroendocrine tumours of the pancreas. *Br J Surg.* 2008;95(5):627-635.
16. Bonney GK, Gomez D, Rahman SH, et al. Results following surgical resection for malignant pancreatic neuroendocrine tumours: a single institutional experience. *JOP.* 2008;9(1):19-25.
17. Solorzano CC, Lee JE, Pisters PW, et al. Nonfunctioning islet cell carcinoma of the pancreas: survival results in a contemporary series of 163 patients. *Surgery.* 2001;130(6):1078-1085.
18. Kent RB 3rd, van Heerden JA, Weiland LH. Nonfunctioning islet cell tumors. *Ann Surg.* 1981;193(2):185-190.
19. Thompson GB, van Heerden JA, Grant CS, et al. Islet cell carcinomas of the pancreas: a twenty-year experience. *Surgery.* 1988;104(6):1011-1017.
20. Gullo L, Migliori M, Falconi M, et al. Nonfunctioning pancreatic endocrine tumors: a multicenter clinical study. *Am J Gastroenterol.* 2003;98(11):2435-2439.
21. Evans DB, Skibber JM, Lee JE, et al. Nonfunctioning islet cell carcinoma of the pancreas. *Surgery.* 1993;114(6):1175-1181; discussion 1181-1182.
22. Carty SE, Jensen RT, Norton JA. Prospective study of aggressive resection of metastatic pancreatic endocrine tumors. *Surgery.* 1992;112(6):1024-1031; discussion 1031-1032.
23. Touzios JG, Kiely JM, Pitt SC, et al. Neuroendocrine hepatic metastases: does aggressive management improve survival? *Ann Surg.* 2005;241(5):776-783; discussion 783-785.
24. Fendrich V, Langer P, Celik I, et al. An aggressive surgical approach leads to long-term survival in patients with pancreatic endocrine tumors. *Ann Surg.* 2006;244(6):845-851; discussion 852-853.
25. Norton JA, Sugarbaker PH, Doppman JL, et al. Aggressive resection of metastatic disease in selected patients with malignant gastrinoma. *Ann Surg.* 1986;203(4):352-359.
26. McEntee GP, Nagorney DM, Kvols LK, et al. Cytoreductive hepatic

surgery for neuroendocrine tumors. *Surgery*. 1990;108(6):1091-1096.

27. Hung JS, Chang MC, Lee PH, Tien YW. Is surgery indicated for patients with symptomatic nonfunctioning pancreatic neuroendocrine tumor and unresectable hepatic metastases? *World J Surg*. 2007;31(12):2392-2397.

28. House MG, Cameron JL, Lillemoie KD, et al. Differences in survival for patients with resectable versus unresectable metastases from pancreatic islet cell cancer. *J Gastrointest Surg*. 2006;10(1):138-145.

29. Sarmiento JM, Que FG, Grant CS, et al. Concurrent resections of pancreatic islet cell cancers with synchronous hepatic metastases: outcomes of an aggressive approach. *Surgery*. 2002;132(6):976-982; discussion 982-983.

30. Falconi M, Bettini R, Boninsegna L, et al. Surgical strategy in the treatment of pancreatic neuroendocrine tumors. *JOP*. 2006;7(1):150-156.

31. Norton JA. Endocrine tumours of the gastrointestinal tract: surgical treatment of neuroendocrine metastases. *Best Pract Res Clin Gastroenterol*. 2005;19(4):577-583.

32. O'Toole D, Maire F, Ruzsiewicz P. Ablative therapies for liver metastases of digestive endocrine tumours. *Endocr Relat Cancer*. 2003;10(4):463-468.

33. Gillams A, Cassoni A, Conway G, et al. Radiofrequency ablation of neuroendocrine liver metastases: the Middlesex experience. *Abdom Imag-ing*. 2005;30(4):435-441.

34. Kwekkeboom DJ, de Herder WW, Kam BL, et al. Treatment with the radiolabeled somatostatin analog [177 Lu-DOTA 0,Tyr3]octreotate: toxicity, efficacy, and survival. *J Clin Oncol*. 2008;26(13):2124-2130.

35. Valkema R, Pauwels S, Kvols LK, et al. Survival and response after peptide receptor radionuclide therapy with [90Y-DOTA0,Tyr3]octreotide in patients with advanced gastroenteropancreatic neuroendocrine tumors. *Semin Nucl Med*. 2006;36(2):147-156.

36. Strosberg JR, Choi J, Cantor AB, et al. Selective hepatic artery embolization for treatment of patients with metastatic carcinoid and pancreatic endocrine tumors. *Cancer Control*. 2006;13(1):72-78.

37. Osborne DA, Zervos EE, Strosberg J, et al. Improved outcome with cytoreduction versus embolization for symptomatic hepatic metastases of carcinoid and neuroendocrine tumors. *Ann Surg Oncol*. 2006;13(4):572-581. Epub 2006 Feb 28.

38. Gupta S, Johnson MM, Murthy R, et al. Hepatic arterial embolization and chemoembolization for the treatment of patients with metastatic neuroendocrine tumors: variables affecting response rates and survival. *Cancer*. 2005;104(8):1590-1602.

39. Moertel CG, Johnson CM, McKusick MA, et al. The management of patients with advanced carcinoid tumors and islet cell carcinomas. *Ann Intern Med*. 1994;120(4):302-309.

40. Moertel CG. Karnofsky memorial lecture: an odyssey in the land of small tumors. *J Clin Oncol*. 1987;5(10):1502-1522.

41. Dhar A, Chawla Y, Dhiman RK, et al. Biliary obstruction due to pancreatic insulinoma. *Dig Dis Sci*. 1995;40(11):2368-2372.

42. Metz DC, Benjamin SB. Islet cell carcinoma of the pancreas presenting as bleeding from isolated gastric varices. Report of a case and review of the literature. *Dig Dis Sci*. 1991;36(2):241-244.

43. Yamaguchi T, Takahashi H, Kagawa R, et al. Nonfunctioning pancreatic endocrine tumor presenting with hemorrhage from isolated gastric varices. *Am Surg*. 2005;71(12):1027-1030.

44. Wolf JH, Long RJ, Miller FJ Jr, et al. Pancreatic islet cell tumor presenting as bleeding gastric varices secondary to splenic vein occlusion. *Am J Dig Dis*. 1977;22(7):652-655.

45. Moertel CG, Lefkopoulo M, Lipsitz S, et al. Streptozocin-doxorubicin, streptozocin-fluorouracil or chlorozotocin in the treatment of advanced islet-cell carcinoma. *N Engl J Med*. 1992;326(8):519-523.

46. Rivera E, Ajani JA. Doxorubicin, streptozocin, and 5-fluorouracil chemotherapy for patients with metastatic islet-cell carcinoma. *Am J Clin Oncol*. 1998;21(1):36-38.

47. Kouvaraki MA, Ajani JA, Hoff P, et al. Fluorouracil, doxorubicin, and streptozocin in the treatment of patients with locally advanced and metastatic pancreatic endocrine carcinomas. *J Clin Oncol*. 2004;22(23):4762-4771.

48. Kulke MH, Stuart K, Enzinger PC, et al. Phase II study of temozolomide and thalidomide in patients with metastatic neuroendocrine tumors. *J Clin Oncol*. 2006;24(3):401-406.

49. Strosberg JR, Choi J, Gardner N, et al. First-line treatment of metastatic pancreatic endocrine carcinomas with capecitabine and temozolomide. *J Clin Oncol*. 2008;26(May 20 suppl). Abstract 4612.

50. Strosberg J, Hoffe S, Gardner N, et al. Effective treatment of locally advanced endocrine tumors of the pancreas with chemoradiotherapy. *Neuroendocrinology*. 2007;85(4):216-220. Epub 2007 May 16.

51. Sorbye H, Westre B, Horn A. Curative surgery after neoadjuvant chemotherapy in metastatic poorly differentiated neuroendocrine carcinoma. *Eur J Surg Oncol*. 2007;33(10):1209-1210. Epub 2007 Mar 12.

52. Bilimoria KY, Talamonti MS, Tomlinson JS, et al. Prognostic score predicting survival after resection of pancreatic neuroendocrine tumors: analysis of 3851 patients. *Ann Surg*. 2008;247(3):490-500.

53. Bloomston M, Muscarella P, Shah MH, et al. Cytoreduction results in high perioperative mortality and decreased survival in patients undergoing pancreatectomy for neuroendocrine tumors of the pancreas. *J Gastrointest Surg*. 2006;10(10):1361-1370.

54. Chung JC, Choi DW, Jo SH, et al. Malignant nonfunctioning endocrine tumors of the pancreas: predictive factors for survival after surgical treatment. *World J Surg*. 2007;31(3):579-585.