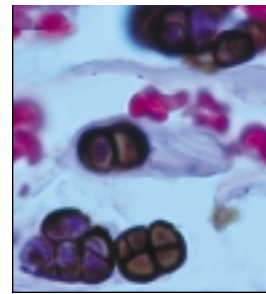


A PROGRESSIVELY ENLARGING CYSTIC RENAL MASS IN A PREVIOUSLY HEALTHY 48-YEAR-OLD WOMAN

Vernon M. Chapman, BS, and Todd R. Hazelton, MD

From the University of South Florida College of Medicine (VMC) and the Department of Radiology at the H. Lee Moffitt Cancer Center & Research Institute (TRH), Tampa, Fla.



This regular feature will enhance your knowledge of imaging technology in oncologic diagnosis, treatment, and evaluation.

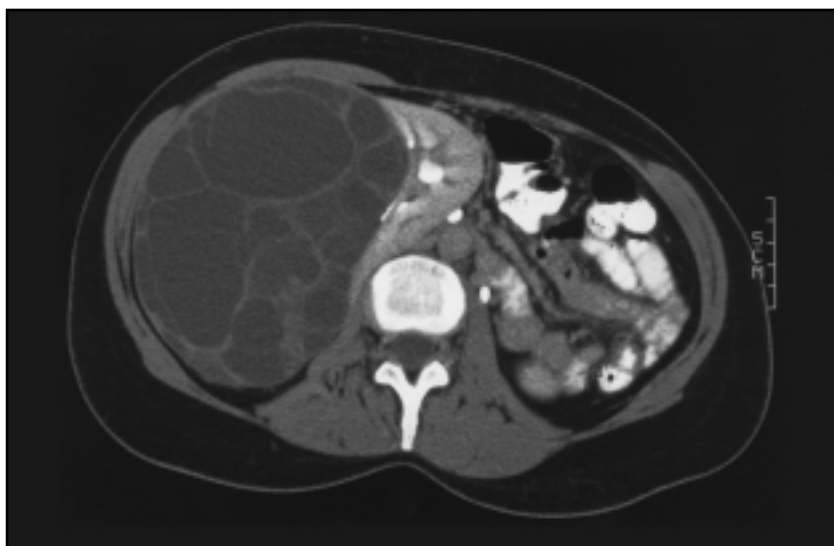
Case Description

A 48-year-old previously healthy woman was referred for evaluation of a cystic right renal mass. The mass was first noted in 1991 when an abdominal computed tomography (CT) scan revealed a 6 × 6-cm cystic mass with internal septations located in the mid right kidney. CT-guided aspiration was performed and cytologic evaluation of the specimen revealed no evidence of malignancy. Over the next seven years, periodic renal ultrasounds demonstrated enlargement of the mass. A second CT-guided cyst aspiration in 1995 again showed no evidence of malignancy on cytologic evaluation. An image from an abdominal CT scan performed in 1998 is shown in the Figure. The scan demonstrates a complex, nonenhancing, 14-cm cystic renal mass with multiple internal septations. The mass displaces the right psoas

muscle and right kidney, and it splays the right renal collecting system anteromedially. Based on its appearance, the lesion was categorized as a Bosniak class III cystic renal mass.¹ The left kidney and both ureters appeared normal. The patient had been without complaint since 1991 except for some mild abdominal discomfort in the weeks prior to referral.

The most likely diagnosis is:

1. adult-type polycystic kidney disease
2. multicystic dysplastic kidney
3. multilocular cystic nephroma
4. renal cell carcinoma
5. uremic medullary cystic disease



Contrast-enhanced abdominal CT image of a 48-year-old woman demonstrating a large, complex, non-enhancing, right cystic renal mass with multiple internal septations.

[Click here to go to the answer and discussion.](#)