



Roxanne Swentzell, *Santa Clara*, b. 1963. "The Emergence of the Clowns," 1988. Mixed media clay. Courtesy of the Heard Museum, Phoenix, Arizona.

*Endoscopic ultrasound  
may provide cost-effective  
evaluation of patients  
with pancreatic cancer.*

# Endoscopic Ultrasound in the Clinical Staging and Management of Pancreatic Cancer: Its Impact on Cost of Treatment

*Mark E. Powis, MD, and Kenneth J. Chang, MD*

**Background:** *Surgical resection for pancreatic cancer carries a 5% 5-year survival rate. Most conventional methods of imaging do not detect small pancreatic tumors and do not accurately stage pancreatic neoplasms. There is a significant impact on medical resources despite the relatively small number of patients affected. For these reasons, careful selection of patients for surgical resection is necessary.*

**Methods:** *Endoscopic ultrasound (EUS) and fine-needle aspiration (FNA) have been developed to overcome limitations of conventional staging. We address the issues of how EUS may provide cost-effective treatment in the patient with pancreatic cancer.*

**Results:** *EUS produces high-resolution images of the pancreas, which can detect small pancreatic tumors and accurately stage pancreatic neoplasms. Evaluation with EUS-guided FNA selects patients who would benefit most from surgical resection. EUS also can be used to deliver palliative treatment for pain at the initial time of staging. EUS with FNA identifies patients most likely to benefit from surgical resection and thus channels health care resources more appropriately.*

**Conclusions:** *Defining this patient population helps to reduce direct medical care costs in pancreatic cancer. However, prospective data are lacking in this regard and will need to be addressed in the future. When palliative care is the goal for patients, EUS-guided fine-needle injection techniques can be used for celiac neurolysis and possibly in the future use of antitumor agents.*

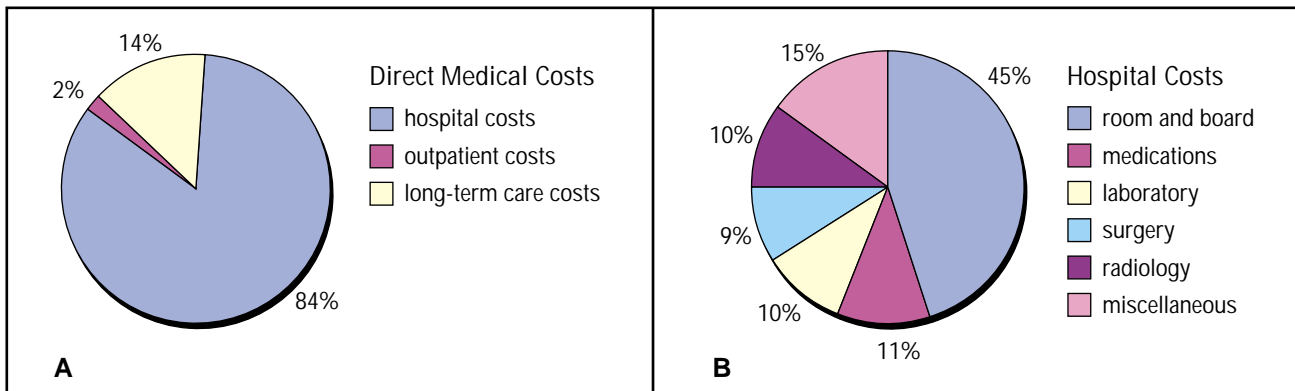
## Background and Economic Impact of Pancreatic Cancer

Pancreatic cancer occurs in approximately 29,000 patients per year and is the fourth leading cause of cancer related-mortality.<sup>1,2</sup> Despite recent advances in perioperative management, 5-year survival rates remain essentially unchanged from a historical 5-year survival of 5%.<sup>3</sup> Identifying patients who would best benefit

*From the Division of Gastroenterology at the University of Colorado Health Sciences Center, Denver, Colo (MEP), and the Gastrointestinal Oncology Program at the University of California, Irvine Medical Center, Orange, Calif (KJC).*

*Address reprint requests to Kenneth J. Chang, MD, Gastrointestinal Oncology, Chao Family Comprehensive Cancer Center, 101 The City Drive, Bldg 23, Rte 81, Orange, CA 92868.*

*Dr. Chang receives educational grants from Pentax Corp and from Olympus America, Inc.*



Figs 1A-B. — Estimated costs associated with pancreatic cancer treatment, with 84% of direct medical costs relating to hospitalization costs. (A) Breakdown of direct medical costs associated with hospital, outpatient, and long-term care costs. (B) Breakdown of hospital costs associated with room/board, medications, laboratory, surgery, radiology, and miscellaneous. Data from Wilson and Lightwood.<sup>4</sup>

from a surgical procedure as opposed to palliative treatment has remained problematic. Despite the best efforts, most patients are found to have unresectable tumors at the time of surgery.

The economic impact of pancreatic cancer is also of great concern. However, information about the costs of pancreatic cancer is limited. In a recent analysis using a prevalence approach method by Wilson and Lightwood,<sup>4</sup> the direct medical care costs in the United States were estimated to be \$881 million annually. In this series, direct medical costs referred to three components: hospitalization costs, outpatient costs (eg, medications, transportation, medical equipment, and supplies), and home and long-term care. In total, 84% of direct medical costs were related to hospitalization costs. Long-term care costs accounted for 14%, and outpatient costs accounted for 9% of direct medical costs (Fig 1A). Of hospitalization costs, room and board accounted for 45% of costs, surgery for 9%, and radiology for 10% (Fig 1B).

The average costs for admissions with major surgery were more than three times greater than for those without major surgery — \$22,546 and \$7,188, respectively. As with most medical costs, inpatient care represents the majority of costs.<sup>4</sup> Effectively dividing patients into surgical and palliative treatment groups clearly has economic repercussions.

Another analysis found that pancreatic cancer costs amounted to \$2.6 billion in total health care costs, accounting for 1.8% of the entire cost of caring for all cancer patients in the United States.<sup>5</sup> In the analysis by Wilson and Lightwood,<sup>4</sup> total annual costs in the United States, including direct medical costs and indirect costs (costs due to lost wages, lost employment, and lost activity days) accounted for \$4.9 billion lost annually. A great deal of resources are lost directly and indirectly as a result of pancreatic cancer.

## Conventional Diagnosis and Staging of Pancreatic Cancer

Traditionally, computed tomography (CT), endoscopic retrograde cholangiopancreatography (ERCP), and angiography have been the mainstays of preoperative staging and management in patients with pancreatic cancer. CT scan detection rates for pancreatic tumors of any size, for those smaller than 3 cm, and for those smaller than 2 cm are approximately 78%, 50%, and 29%, respectively.<sup>6,7</sup> Similarly, transabdominal ultrasound (US) detection rates are 70%, 50%, and 29%, respectively.<sup>6,7</sup> Additionally, helical CT scan has also been compared to EUS and has not been shown to be as sensitive in detecting tumors smaller than 3 cm.<sup>8,9</sup> Thus, for pancreatic carcinomas smaller than 2 cm, conventional CT or transabdominal US is inadequate for detection. When considering that these patients with small tumors are also the most likely to benefit from surgical resection, this low sensitivity is clinically relevant.

Likewise, ERCP also has a lower diagnostic sensitivity for small pancreatic tumors and offers no information regarding vascular invasion and lymph node involvement.<sup>6,7</sup> Overall, conventional diagnosis using CT, ERCP, or US seems to identify patients at a late stage in diagnosis, when surgical interventions may have little benefit and may consume resources.

## Endoscopic Ultrasound

In the 1980s, EUS was developed to overcome the limitations of transabdominal US and CT when imaging the pancreas. EUS is a dual-modality technique, where an ultrasound transducer is directly placed at the tip of an endoscope permitting transgastric and transduodenal imaging of the entire pancreas, thereby providing high-resolution images of the pancreas. EUS has been shown

to be superior to CT scan, US, ERCP, or angiography in detecting tumors smaller than 3 cm in size.<sup>6,7,10-13</sup>

Currently, two types of EUS scopes are available, using either radial sector or linear array transducers. Radial EUS provides high-resolution images of the gut lumen, adjacent organs, lymph nodes, and vascular structures. The radial EUS echoendoscope scans at 7.5

and 12 MHz and provides a 360° view. Because of its proximity to the gastric and duodenal walls, the pancreas can be easily imaged from the upper gastrointestinal tract. High-resolution images of the pancreas (Fig 2) are generated in an infinite number of views. EUS shows fine parenchymal details such as early fibrosis, calcifications, and pancreatic ductal changes (Figs 2-3). Pancreatic tumors typically appear as irregularly shaped hypoechoic or inhomogeneous areas within the normal echo-texture of the pancreas<sup>6</sup> (Fig 4). In cases of pancreatic cancer, tumor extension into the portal vein, splenic vein, common bile duct, and the duodenum can be readily identified (Fig 5). Additionally

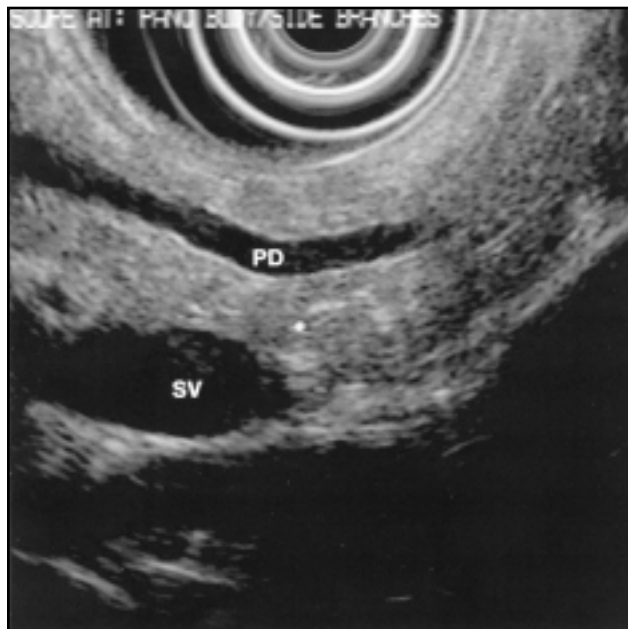


Fig 2. — 12 MHz radial EUS view of pancreas body, showing a 4-mm dilated pancreatic duct (PD) and a small pancreatic duct side branch adjacent to the white cursor. These findings are suggestive of chronic pancreatitis. SV = splenic vein.

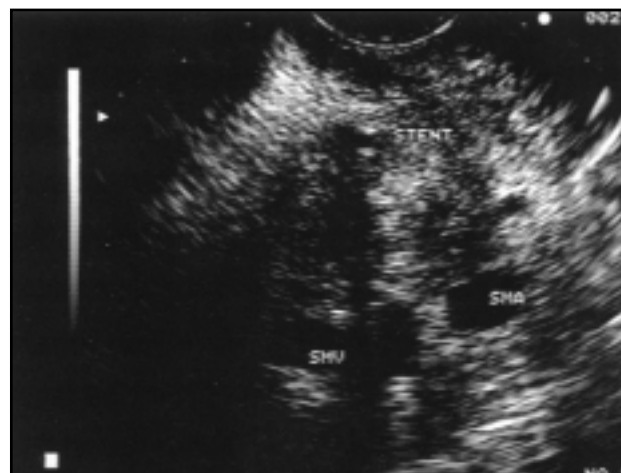


Fig 4. — Linear array EUS view of a pancreatic head mass. This view shows a biliary stent passing within the mass and shows the proximity of the superior mesenteric vein (SMV) and the superior mesenteric artery (SMA).

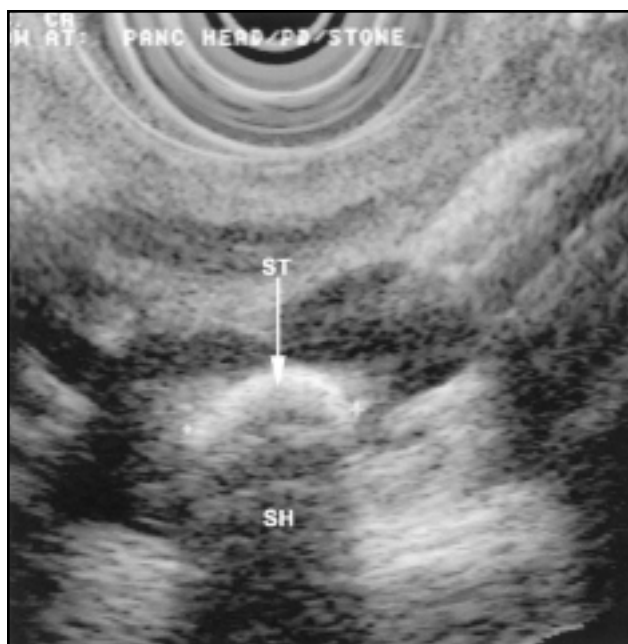


Fig 3. — 7.5 MHz radial EUS view of the pancreas body, showing a pancreatic duct stone (ST) in a patient with chronic calcific pancreatitis. Note the shadowing (SH) from the pancreatic duct stone.

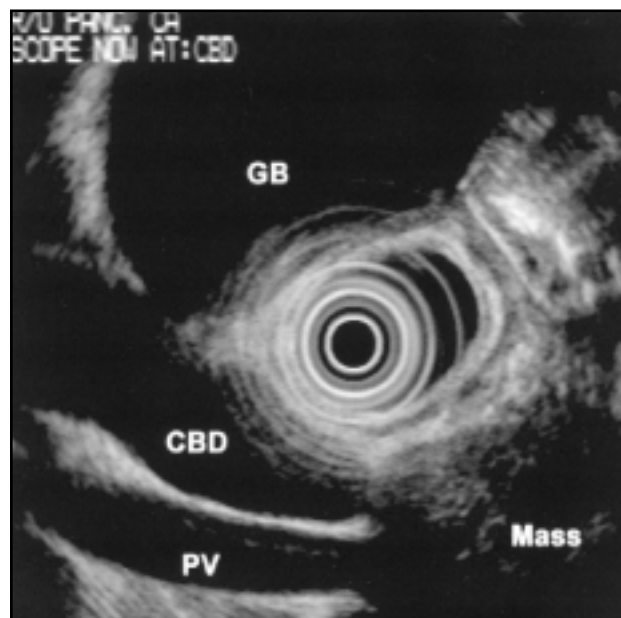


Fig 5. — 7.5 MHz radial EUS view of a pancreatic head lesion as viewed from the duodenal bulb. This image shows the pancreatic mass and the relationship of the mass to the common bile duct (CBD), portal vein (PV), and gallbladder (GB).

metastatic disease to the liver, ascites, celiac, and periduodenal lymph nodes can also be seen (Figs 6-9).

Linear array EUS echoendoscopes have transducers placed in a curvilinear fashion along the tip of the echoendoscope. This generates an ultrasound image in the plane of the endoscope. Unlike radial EUS, linear array EUS processors are equipped with color Doppler. This allows for accurate identification of vascular structures and aids in vascular staging of pancreatic tumors. Also, linear array EUS can be used for fine-needle aspiration (FNA) of tumors in real time (Fig 10).

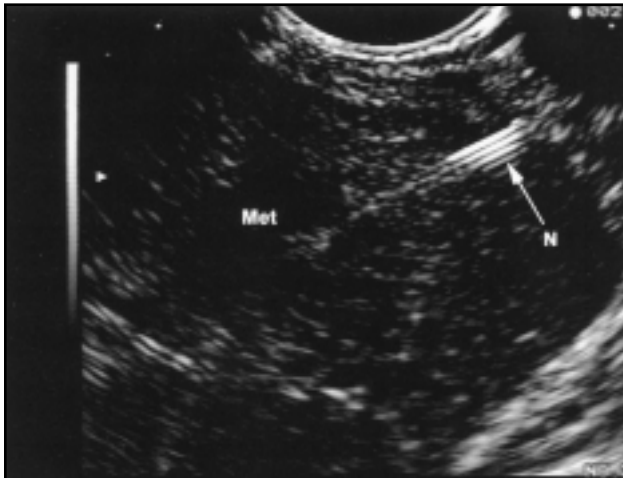

Fig 6. — Linear array EUS view showing FNA of an irregularly shaped hypoechoic lesion (Met) in the periphery of the liver. This lesion was not detected by CT scan and ultimately was shown to be a metastasis from a pancreatic adenocarcinoma. N = needle.

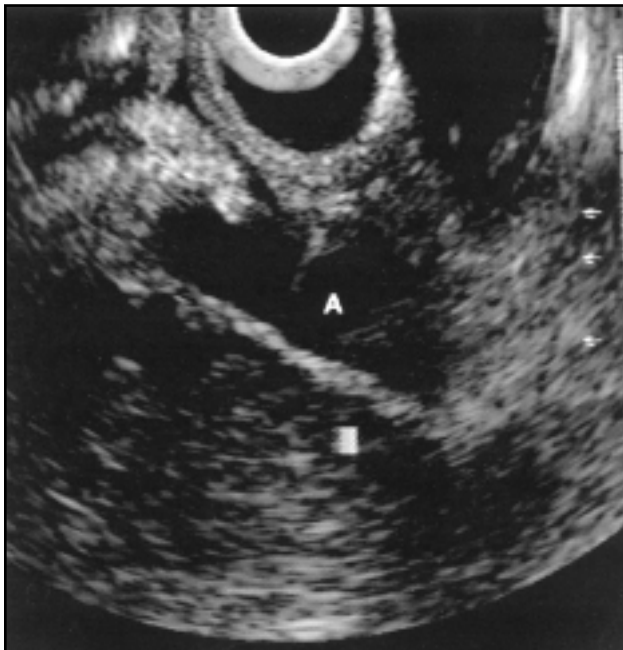

Fig 7. — Linear array EUS view of FNA of perigastric ascites (A). This patient was found to have malignant ascites by EUS-guided FNA.

Despite the detailed images produced by EUS, many authors have reported difficulty in differentiating malignant from inflammatory masses. Rosch et al<sup>6</sup> reported that EUS was not helpful in differentiating malignant from inflammatory pancreatic masses among

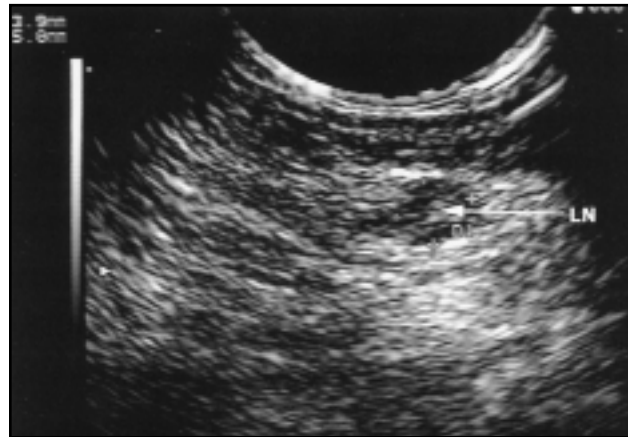


Fig 8. — Linear array EUS view of a small round 3-mm x 5-mm hypoechoic celiac lymph node (LN) in a patient with esophageal cancer. This lymph node was ultimately found to be malignant by EUS-guided FNA.

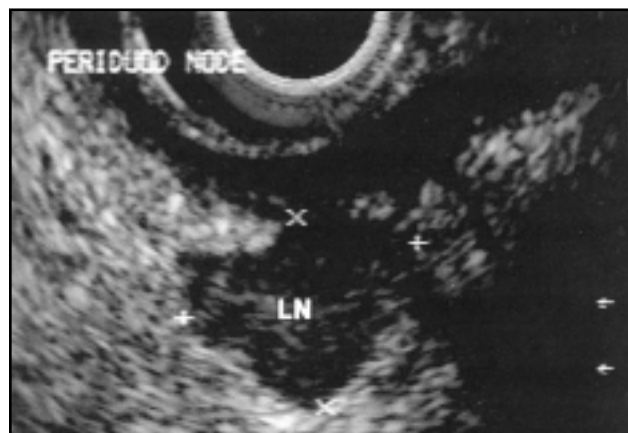


Fig 9. — 7.5 MHz radial EUS view of a periduodenal lymph node (LN) in a patient undergoing staging for pancreatic cancer. This lymph node is large, hypoechoic, and irregularly shaped — all suggestive of malignancy. This lymph node was found to be malignant by EUS-guided FNA.

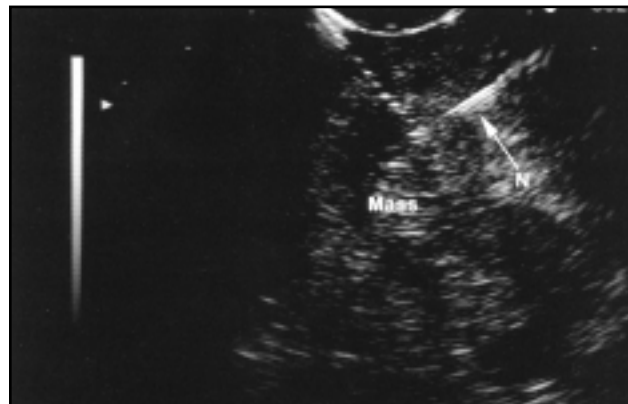

Fig 10. — Linear array EUS view of a EUS-guided FNA of a pancreatic adenocarcinoma. N = needle.

132 patients, with an overall accuracy of 76% for malignancy and 46% for focal inflammation. For this reason, EUS-guided FNA was devised as a technique to overcome this shortcoming.

## EUS-Guided FNA

The specificity of EUS in detecting primary and secondary cancers can be significantly increased by using EUS-guided FNA.<sup>14-19</sup> Although CT-guided FNA is the conventional method for making a tissue diagnosis, it is limited in its ability to detect small tumors. In a recent multicenter trial, the CT scans of 56% of patients who were later diagnosed with pancreatic carcinoma did not demonstrate a specific mass lesion.<sup>20</sup> In this multicenter trial, 164 consecutive patients with a variety of pancreatic mass lesions underwent FNA of these lesions or associated lymph nodes. Forty-nine pancreatic lesions were benign and 103 were malignant. The overall sensitivity, specificity, accuracy, negative predictive value, and positive predictive value of EUS-guided FNA for pancreatic cancer was 83%, 90%, 85%, 80%, and 100%, respectively, compared with 56%, 37%, 50%, 28%, and 65% for CT scan ( $P < .05$ ).

Additionally, EUS-guided FNA has been shown to have a relatively low complication rate. This same study showed a 1% rate of major complication (1 case of perforation and 1 of bleeding) and a 1% minor complication rate (fever).<sup>20</sup> Concerns over tumor seeding of the peritoneal cavity with CT-guided FNA of pancreatic masses has limited its use by many surgeons. However, EUS-guided FNA through the duodenum has the distinct advantage of not passing through the peritoneal cavity. In theory, this should prevent peritoneal seeding, but long-term data to this regard are lacking.

## EUS and Cost of Care in Pancreatic Cancer

EUS-guided FNA has been shown to affect clinical decisions in patients with pancreatic cancer. Lymph node staging, portal vein invasion, and the presence of hepatic metastasis or malignant ascites provide important prognostic information and prevent patients from undergoing further unnecessary evaluations. In a series of 44 consecutive patients who underwent EUS with or without FNA, demonstrating portal vein invasion or proving metastasis to celiac lymph nodes increased the stage of 41% of the patients referred to our institution for evaluation of pancreatic carcinoma.<sup>21</sup> The use of EUS prevented surgery in 12 (27%) patients and avoided further diagnostic testing in 57% of patients. In 70% of the patients in this series who underwent EUS-guided FNA,

Table 1. — Clinical Impact and Cost Savings With EUS-Guided FNA With Pancreatic Masses

- Surgery for a tissue diagnosis alone is avoided.
- Operative time waiting for a frozen section biopsy results is decreased.
- Tissue diagnosis (primary tumor, nodes, or peritoneal fluid) combined with EUS staging (vascular invasion) determines whether the patient is a candidate for curative resection, neoadjuvant therapy, palliative surgery, or nonoperative therapy.
- Diagnosis of lymphoma would warrant chemotherapy instead of surgical resection.
- Nonoperative palliative therapy (eg, chemotherapy, radiation therapy) usually requires a tissue diagnosis before initiation.
- The patient is expedited to some form of definitive therapy and avoids serial imaging studies.
- Patient anxiety is alleviated regarding the diagnosis.
- A more accurate prognosis can be provided to the patient.

clinical management was affected by EUS-guided FNA results. The overall economic benefit from the patients who avoided surgery was \$145,000 (or \$3,300 per patient) in this study. These findings suggest that EUS-guided FNA would be cost effective in pancreatic cancer patients who are considered for curative resection.

We recently obtained an independent audit of the hospital costs and the professional fees of an exploratory laparotomy compared with EUS-guided FNA during the period from the previously cited study.<sup>22</sup> The average direct hospital cost of a laparotomy was \$18,236, and the average professional fee for the surgeon, anesthesiologist, and pathologist was \$2,810, totaling \$21,046 for the cost for surgery. The hospital/technical costs and professional fees (endoscopist and pathologist) for EUS-guided FNA was \$2,440. For patients who have a high suspicion of advanced disease or who are poor surgical candidates, EUS provides a less expensive approach to staging as opposed to laparotomy. Using a numbers needed to treat (NNT) analysis, this means that at least 1 patient for every 8.6 patients staged would need to have unresectable disease by EUS to financially justify using EUS. To date, no prospective economic analysis comparing EUS to laparotomy exists.

In this era of cost containment, new technologies must be judged on their merits to affect outcome, clinical management, and costs. In the 1990s, EUS was proven to be accurate in staging pancreatic cancer and affecting clinical management. However, in the upcoming decade, EUS will need to be compared with helical CT, positron emission tomography, and surgical staging in terms of cost effectiveness. EUS combined with FNA for pancreatic cancer or suspected pancreatic cancer does have several possible cost benefits and implications (Table 1).

## Modified TNM Classification of Pancreatic Neoplasms

Currently, the only cure for pancreatic cancer is with a surgical approach. Palliative surgery for pancreatic cancer has not been shown to extend mortality curves. Although technically feasible, invasion of the portal vein, superior mesenteric vessels, and celiac trunk usually precludes a surgical resection.<sup>23</sup> For these reasons, particular attention is paid to the evaluation of these vascular structures at the time of EUS. The current TNM classification of malignant tumors is presented in Table 2.<sup>24</sup>

## EUS-Guided Celiac Block-Palliative Care

Celiac blocks have long been used for pain control in patients with pancreatic cancer. This is accomplished during surgery, with fluoroscopy, or via a CT-guided technique. During surgery, either ethyl alcohol or bupivacaine is administered into the area surrounding the celiac artery. When performed with fluoroscopy, injections into the celiac trunk are accomplished approaching from the spine in an anterolateral approach at the T12 level. CT scan guidance utilizes an anterior approach, which provides a more accurate placement of injection around the celiac

trunk. This leads to higher success rates approaching 70%-90%.<sup>25,26</sup>

EUS also can be used for placement of neurolytic agents into the celiac ganglia nerve complex. The celiac artery trunk is easily identified as it exits the aorta using a linear array echoendoscope.<sup>27</sup> A 22-gauge needle is passed through the biopsy channel and, under real-time guidance, is advanced through the gastric wall into the area surrounding the celiac trunk. Bupivacaine (0.25%) and ethyl alcohol (98%) can then be injected (Fig 11).

Wiersema and Wiersema<sup>28</sup> in 1996 reported on a series of 25 patients with pancreatic carcinoma and 5 patients with intra-abdominal metastasis who underwent EUS-guided celiac nerve blocks. Pain was evaluated using a visual analog scale (0 = no pain and 10 = most severe pain). Patients' perception of pain was significantly lower at 2, 4, 8, and 12 weeks after injection compared with baseline pain scores. During their 12-week follow-up, 82%-91% of patients required the same or lower dosages of pain medications, and 79%-88% of patients had persistent improvement in their pain scores. As with other types of celiac nerve blocks, transient orthostatic hypotension and diarrhea occurred in 4 of the patients from this series. Theoretically, spinal cord injuries should be less likely from EUS-guided celiac blocks because an anterior approach is used as opposed to fluoroscopically guided injections. Another benefit is that EUS-guided celiac block can be performed at the time of pancreatic cancer biopsy and staging. EUS-guided celiac neurolysis can be easily performed and adds little extra time to an EUS examination. Performing an EUS in this fashion allows staging, diagnosis, and palliative care to be performed in one setting. This in itself improves on the cost benefit of EUS.

Due to copyright restrictions, Table 2 has been removed from this online article.

Please refer to the printed version found in *Cancer Control Journal*, V7, N5, to view this table.

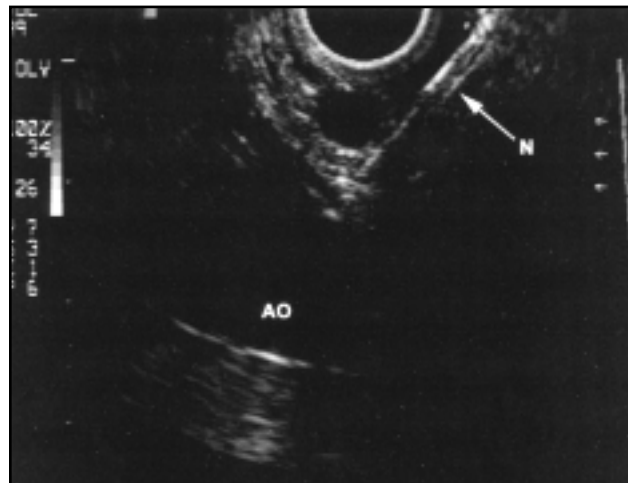


Fig 11. — Linear EUS view showing EUS-guided neurolysis of the celiac ganglia. AO = aorta, N = needle.

## EUS-Guided Fine-Needle Injection of Antitumor Agents

The natural extension of EUS-guided fine-needle injection (FNI) is its use for delivery of chemotherapeutic agents. At our center, we recently conducted a phase I clinical trial using EUS-guided FNI of a local immunotherapy in patients with unresectable pancreatic cancer.<sup>29</sup> Results from this trial appear favorable, and a phase II/III trial is currently underway. In the future, if anticancer agents could be delivered into pancreatic tumors as an alternative to surgical intervention, then additional cost reduction may be realized.

The algorithm shown in Fig 12 differs from many conventional workup schemes for pancreatic cancer in several ways. In this algorithm, EUS staging and FNA replace CT-guided FNA, which provides little additional information regarding patient staging. Additionally, mesenteric angiograms are not included in this algorithm. Rather, the authors believe that these should be used in selected cases where superior mesenteric artery invasion is suspected but not proven on CT or EUS. By carefully screening out patients with focal pancreatitis (false-positive CT), malignant ascites, pancreatic cancer with portal vein invasion, and hepatic metas-

tasis by EUS, these patients can avoid costly and ineffective surgical resections. This would result in a more select group of patients being sent for pancreatic cancer surgery.

## Conclusions

Even with the best surgical efforts, pancreatic cancer is a disease with significant mortality. It also has a significant impact on medical resources despite the relatively small number of patients affected. For these reasons, careful selection of patients for surgical resection is necessary. EUS currently provides the most sensitive modality for diagnosing early cases of pancreatic cancer. EUS also provides accurate and detailed staging of pancreatic cancer. Utilizing EUS is also helpful in identifying patients most likely to benefit from surgical therapy and those for whom palliative treatment is most appropriate. This differentiation reduces direct medical care costs in pancreatic cancer. However, prospective data are lacking in this regard and will need to be addressed in the future. When palliative care is the goal for patients, EUS-guided FNI techniques can be used for celiac neurolysis and possibly in the future antitumor agents.

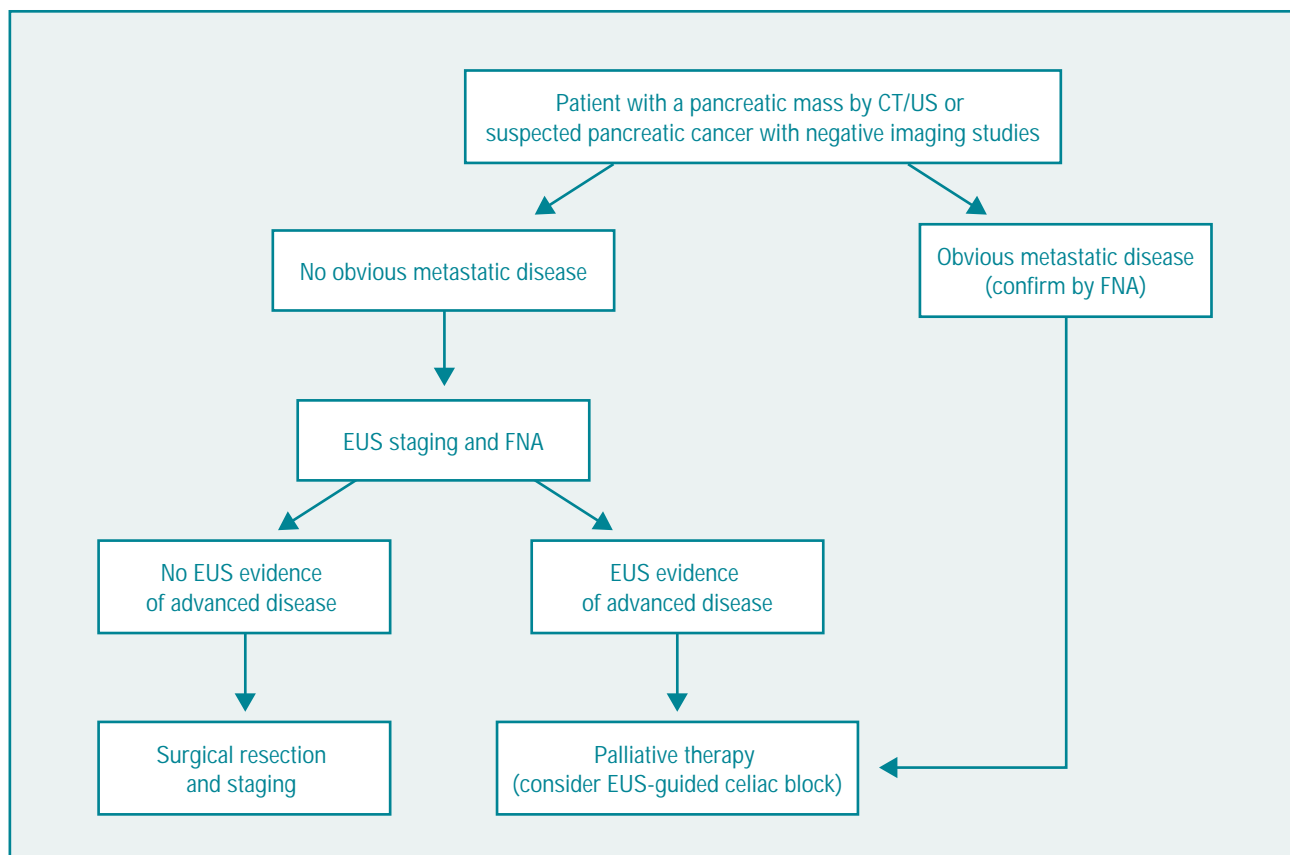


Fig 12. — Suggested algorithm for pancreatic cancer staging for a patient with a pancreatic mass by CT/US or suspected pancreatic cancer with negative imaging studies.

## References

1. Warshaw AL, Gu ZY, Wittenberg J, et al. Preoperative staging and assessment of resectability of pancreatic cancer. *Arch Surg*. 1990;125:230-233.
2. *Statistical Abstract of the United States*. US Dept of Commerce, Bureau of the Census; 1998:152-153.
3. Yeo CJ, Cameron JL, Lillemoe KD, et al. Pancreaticoduodenectomy for cancer of the head of the pancreas: 201 patients. *Ann Surg*. 1995;221:721-733.
4. Wilson LS, Lightwood JM. Pancreatic cancer: total costs and utilization of health services. *J Surg Oncol*. 1999;71:171-181.
5. Elixhauser A, Halpern MT. Economic evaluations of gastric and pancreatic cancer. *Hepatogastroenterology*. 1999;46:1206-1213.
6. Rosch T, Lorenz R, Braig C, et al. Endoscopic ultrasound in pancreatic tumor diagnosis. *Gastrointest Endosc*. 1991;37:347-352.
7. Yasuda K, Mukai H, Fujimoto S, et al. The diagnosis of pancreatic cancer by endoscopic ultrasonography. *Gastrointest Endosc*. 1988;34:1-8.
8. Howard TJ, Chin AC, Streib EW, et al. Value of helical computed tomography, angiography, and endoscopic ultrasound in determining resectability of periampullary carcinoma. *Am J Surg*. 1997;174:237-241.
9. Gress F, Ikenberry S, Sherman S, et al. A prospective comparison of endoscopic ultrasound vs spiral computed tomography for pancreatic, biliary and ampullary cancer staging and determination of resectability. *Gastrointest Endosc*. 1996;43:422A.
10. Ikeda M, Fugino MA, Morozumi L, et al. Diagnosis of small pancreatic tumors by endoscopic ultrasonography. *Gastroenterology*. 1989;96:A225.
11. Kaufman AR, Sivak MV Jr. Endoscopic ultrasonography in the differential diagnosis of pancreatic disease. *Gastrointest Endosc*. 1989;35:214-219.
12. Rosch T, Braig C, Gain T, et al. Staging of pancreatic and ampullary carcinoma by endoscopic ultrasonography: comparison with conventional sonography, computed tomography, and angiography. *Gastroenterology*. 1992;102:188-199.
13. Rosch T, Lightdale CJ, Botet JF, et al. Localization of pancreatic endocrine tumors by endoscopic ultrasonography. *N Engl J Med*. 1992;326:1721-1726.
14. Williams DB, Sahai AV, Aabakken L, et al. Endoscopic ultrasound guided fine needle aspiration biopsy: a large single centre experience. *Gut*. 1999;44:720-726.
15. Vilmann P, Jacobsen GK, Henriksen FW, et al. Endoscopic ultrasonography with guided fine needle aspiration biopsy in pancreatic disease. *Gastrointest Endosc*. 1992;38:172-173.
16. Wiersema MJ, Kochman ML, Cramer HM, et al. Endosonography-guided real-time fine-needle aspiration biopsy. *Gastrointest Endosc*. 1994;40:700-707.
17. Giovannini M, Seitz JF, Monges G, et al. Fine-needle aspiration cytology guided by endoscopic ultrasonography: results in 141 patients. *Endoscopy*. 1995;27:171-177.
18. Chang KJ, Katz KD, Durbin TE, et al. Endoscopic ultrasound-guided fine-needle aspiration. *Gastrointest Endosc*. 1994;40:694-699.
19. Suits J, Frazee R, Erickson RA. Endoscopic ultrasound and fine needle aspiration for the evaluation of pancreatic masses. *Arch Surg*. 1999;134:639-643.
20. Chang K, Wiersema M, Giovannini M, et al. Multicenter collaborative study on endoscopic ultrasound (EUS) guided fine needle aspiration (FNA) of the pancreas. *Gastrointest Endosc*. 1996;43:A507.
21. Chang KJ, Nguyen P, Erickson RA, et al. The clinical utility of endoscopic ultrasound-guided fine-needle aspiration in the diagnosis and staging of pancreatic carcinoma. *Gastrointest Endosc*. 1997;45:387-393.
22. Chang KJ, Nguyen P, Erickson R, et al. The clinical and economic impact of endoscopic ultrasound (EUS) guided fine needle aspiration. *Gastroenterology*. 1995;108:A455.
23. Rosch T, Classen M. Endosonographic staging of pancreatic cancer. In: Van Dam J, Sivak MV Jr, eds. *Gastrointestinal Endosonography*. Philadelphia, Pa: WB Saunders Co; 1999.
24. *TNM Classification of Malignant Tumours*. Sobin L, Wit-kind C, eds. 5th ed. New York, NY: John Wiley and Sons Inc; 1997.
25. Eisenberg E, Carr DB, Chalmers TC. Neurolytic celiac plexus block for treatment of cancer pain: a meta-analysis. *Anesth Analg*. 1995;80:290-295.
26. Ischia S, Ischia A, Polati E, et al. Three posterior percutaneous celiac plexus block techniques: a prospective, randomized study in 61 patients with pancreatic cancer pain. *Anesthesiology*. 1992;76:534-540.
27. Chang KJ, Erickson RA. A primer on linear array endosonographic anatomy. *Gastrointest Endosc*. 1996;43:S43-47.
28. Wiersema MJ, Wiersema LM. Endosonography-guided celiac plexus neurolysis. *Gastrointest Endosc*. 1996;44:656-662.
29. Chang K, Nguyen P, Thompson J, et al. Phase I clinical trial of local immunotherapy (cytoimplant) delivered by endoscopic ultrasound guided fine needle injection in patients with advanced pancreatic carcinoma. *Gastrointest Endosc*. 1998;47:A480.