



Polychrome plate, 1970-1977. Blue Corn, *San Ildefonso*, b. 1922. Courtesy of the Heard Museum, Phoenix, Arizona.

*Cystic abnormalities of the pancreas are rare but include several lesions ranging from nonmalignant pseudocysts to neoplastic lesions.*

# Mucinous Tumors of the Exocrine Pancreas

*Mohamad A. Eloubeidi, MD, MHS, and Robert H. Hawes, MD*

**Background:** *Mucin-producing cystic neoplasms of the pancreas account for 1% of all malignant tumors of the pancreas. They include mucinous cystic neoplasms (MCNs) and mucinous ductal ectasia (MDE), also known as intraductal mucin-hypersecreting neoplasms.*

**Methods:** *This review focuses on the clinical presentation, the role of diagnostic imaging modalities, and cyst fluid analysis preoperatively in the differentiation between these tumors and other nonneoplastic cysts of the pancreas.*

**Results:** *MCNs and MDE evolve from pancreatic duct epithelium, produce an abundance of mucin, and are considered premalignant or malignant. While MCNs affect primarily middle-aged women with lesions occurring predominantly in the body and tail of the pancreas, MDE affects primarily men in the sixth or seventh decade with lesions more often located in the head of the pancreas.*

**Conclusions:** *All mucin-producing cystic tumors of both types require surgical resection because they are frankly malignant or premalignant. Survival rates of both tumors are better than those reported for ductal cell carcinomas. Future studies are needed to improve the accuracy of diagnosing these tumors preoperatively.*

## Introduction

Cystic abnormalities of the pancreas encompass a wide variety of lesions ranging from the nonmalignant

pseudocyst to neoplastic lesions (Table 1).<sup>1</sup> Cystic neoplasms of the pancreas are rare, accounting for 10%-13% of pancreatic cysts and 1% of pancreatic carcinomas.<sup>2</sup> Cystic neoplasms of the pancreas include serous cystadenomas, papillary cystic tumors, cystic islet cell tumors, mucinous cystic neoplasms (MCNs [cystadenomas and cystadenocarcinomas]), and intraductal mucin-hypersecreting pancreatic neoplasms, also known as mucinous ductal ectasia (MDE). Better detection rates of these distinct clinical entities have resulted from recent advances in pancreatico-biliary imaging, including endoscopic retrograde cholangiopancreatography (ERCP), magnetic resonance cholangiopancreatography (MRCP), endoscopic ultrasonography (EUS), computed tomography (CT), and

*From the Division of Gastroenterology/Hepatology and the Digestive Disease Center at the Medical University of South Carolina, Charleston, South Carolina. Dr. Eloubeidi is currently at the University of Alabama at Birmingham.*

*Address reprint requests to Mohamad A. Eloubeidi, MD, MHS, Division of Gastroenterology and Hepatology, University of Alabama at Birmingham, 1530 3rd Avenue South - ZRB 636, Birmingham, AL 35294-0007. E-mail: eloubeim@gihep.uab.edu*

*No significant relationship exists between the authors and the companies/organizations whose products or services may be referenced in this article.*

ultrasonography. MCNs and MDE have received much attention due to the possibility of confusing them with benign pseudocysts and the potential for cure if diagnosed and managed appropriately.

MCNs and MDE evolve from pancreatic duct epithelium, produce an abundant amount of mucin, and are considered premalignant or malignant. While MCNs affect primarily middle-aged women with lesions occurring predominantly in the body and tail of the pancreas, MDE affects primarily men in the sixth and seventh decade with lesions more often located in the head of the pancreas.

## Intraductal Mucin-Hypersecreting Neoplasms

Intraductal mucin-hypersecreting neoplasms, also known as mucinous ductal ectasia (MDE), represent a form of pancreatic exocrine tumor previously confused with cystic neoplasms. This clinical entity, first described in 1982 by Ohhashi and colleagues,<sup>3</sup> was referred to as "mucin-producing intraductal tumor." The initial report described four patients with pancreatic carcinoma associated with unique clinical features

distinct from the typical pancreatic ductal adenocarcinoma. Intraductal excretion of mucin resulted in diffuse dilatation of the main pancreatic duct and extrusion of mucus through a patulous ampullary orifice. The variety of terms subsequently used to describe MDE (Table 2) stems from a lack of understanding of this clinicopathologic entity. It seems likely, however, that various authors have focused on different stages in an adenoma-carcinoma sequence when choosing a descriptive diagnosis.<sup>4</sup> A recent study by Rivera et al<sup>5</sup> showed that intraductal papillary neoplasms with or without MDE represent a spectrum of main-duct papillary tumors ranging from adenoma to carcinoma. The authors therefore suggested the term *intraductal papillary mucinous tumors* (IPMTs) of the pancreas to encompass both tumors.

Little information is available on the epidemiology and etiology of IPMTs because they occur rarely and have been only recently recognized. The study by Rivera et al<sup>5</sup> suggested that cigarette smoking is a risk factor for IPMTs, which was also noted in a series based on all pancreatic cancers.<sup>6</sup> Data from animal models suggest that nitrosamines play a significant role in the etiology of both IPMTs and solid ductal adenocarcinomas.<sup>7</sup> IPMTs arise from the epithelial lining of the pancreatic ducts and progress along the duct system. Approximately 75% of the IPMTs arise from the main pancreatic duct within the head of the pancreas. Some IPMTs involve the ampulla of Vater and/or the minor papilla from where they protrude into the duodenum. The dilated duct segment contains a grossly visible papillary/villous tumor and/or viscous mucin. IPMTs may be benign, borderline, or malignant according to the differentiation of the proliferating columnar epithelial cells.

Due to copyright restrictions, Table 1 has been removed from this online article.

Please refer to the printed version found in *Cancer Control Journal*, V7, N5, to view this table.

Table 2. — Terms Used to Describe Mucinous Ductal Ectasia

- Intraductal mucin-producing tumors
- Intraductal papillary adenocarcinoma
- Ductectatic variant of mucinous cystadenoma and cystadenocarcinoma
- Intraductal papillary mucinous tumors
- Intraductal mucin-hypersecreting neoplasms
- Pancreatic duct villous adenoma
- Intraductal cystadenoma
- Mucin-hypersecreting carcinoma
- Mucin-producing tumors
- Intraductal papillary neoplasms

IPMTs occur mostly in men in the sixth to seventh decade (range = 40 to 85 years). The most common presenting symptom is abdominal discomfort associated with mild elevations of pancreatic serum enzymes mimicking chronic or relapsing pancreatitis. The history of pancreatitis or recurrent pancreatitis varies from 29%<sup>5</sup> to 80%<sup>8</sup> in the literature. These symptoms are more commonly observed in patients with mucin-hypersecreting tumors and are most likely due to intermittent obstruction of the main pancreatic duct by plugs of viscous mucin or intraluminal tumor. Back pain (25%), jaundice (25%), weight loss (42%), steatorrhea (37.5%), and diabetes (37.5%) are among various presentations reported in one series.<sup>5</sup> In a recent report from our institution describing outcomes of 25 patients with IPMTs,<sup>9</sup> 52% of patients had acute relapsing pancreatitis with elevated pancreatic enzymes, 32% had pain with normal enzymes, 12% had weight loss with no pain, and 4% had incidental findings. Therefore, due to the indolent nature of these tumors and the limited awareness of this lesion among the medical community, a delay in diagnosis ranging from months to years is not uncommon.

Conventional imaging studies such as abdominal CT scanning and transabdominal ultrasonography reveal nonspecific changes that are indistinguishable from those of chronic pancreatitis, pancreatic pseudocysts, or nonmucinous producing cystic neoplasms. These studies typically demonstrate well-defined unilocular or multilocular cystic pancreatic masses and/or dilatation of the main pancreatic duct. The term *cystic duct* here would be a misnomer since these cystic

structures represent dilated ductular structures. The cystic changes of IPMTs may occasionally be so extensive as that they are confused with a mucinous cystic neoplasm. An important distinction between the two lesions is that, in IPMTs, the "cysts" communicate with the duct system, whereas MCNs generally do not show any connection with the duct system.

Endoscopy and endoscopic retrograde pancreatography (ERP) are essential to clarify the diagnosis. The typical ERP reveals extreme dilatation along the entire length of the main pancreatic duct, with associated side branch ectasia, in the absence of a demonstrable pancreatic duct stricture that would explain the duct dilation (Fig 1). The cystically dilated portions of the duct are filled with mucus, and the dilation is the result of mucus obstruction. In a report by Cunningham and colleagues,<sup>9</sup> ERCP findings were patulous papilla (80%), visible mucin (84%), ductal filling defects (88%), and dilated pancreatic duct (100%), with whole pancreatic duct dilated in 64% and focal segmental dilation in 36%. Tissue specimens (aspiration cytology, brush cytology, or pancreatic biopsy) obtained endoscopically have a high false-negative rate but are helpful when positive.

Pancreatotomy may provide valuable information for the differential diagnosis of amorphous filling defects in the main pancreatic duct and may help to determine the extent of the pathology and the resection margin. Pancreatotomy can be used to easily differentiate between an intraductal mass and mucin. Also, biopsies can be taken under direct vision from a suspicious mucosal lesion using the "mother-baby scope."<sup>10</sup> Although a diagnosis of malignancy can be obtained preoperatively, this usually does not substitute for surgical exploration and resection of the diseased segment based on frozen section results. In a series reporting on the results of 24 patients,<sup>5</sup> 20 (83%) were resectable. There were 9 pancreatoduodenectomies, 4 distal pancreatectomies, and 7 total pancreatectomies. The operation chosen is usually tailored to conform to the apparent distribution of the intraluminal tumor and not to the distribution of mucin. The inability to achieve histologically negative margins often leads to a total pancreatectomy. At final pathology, invasive adenocarcinoma was seen in 46% of the patients, carcinoma in situ was seen in an additional 24%, and low-grade dysplasia in 12% of the remaining patients. Despite the 88% prevalence of cancer in this series, the overall survival at a mean follow-up of 21 months was 81%. There were no recurrences or new papillary growths in the pancreatic remnants. Four of the 24 patients had unresectable disease due to liver metastasis. The serum CA 19-9 value was helpful in predicting unresectability. Three of the 4 unresectable patients in this series had values higher than 2000 U/mL.

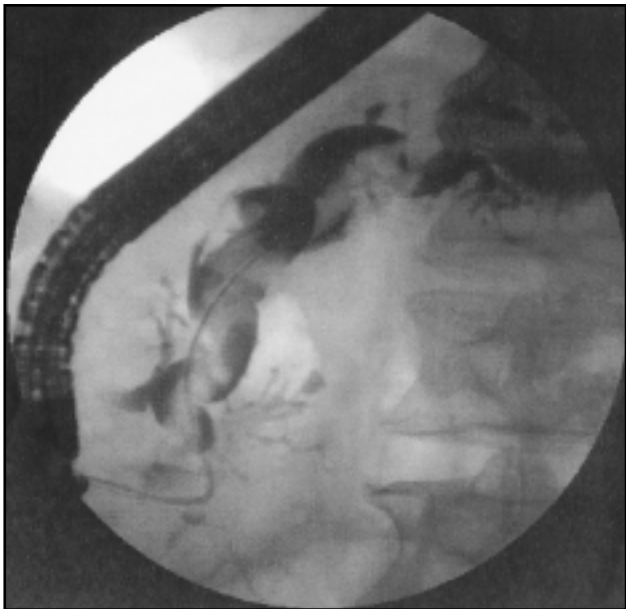


Fig 1. — Endoscopic retrograde pancreatography demonstrates a diffusely dilated main pancreatic duct with filling defects and dilated irregular side branches consistent with mucinous ductal ectasia (MDE).

Cellier and colleagues<sup>11</sup> found invasive carcinoma in 43% of their patients and carcinoma in situ in 21%, with significantly poorer prognosis for patients with invasive carcinoma. The overall actuarial 3-year survival for patients with IPMTs was 83% in their series, whereas the overall recurrence-free 3-year survival was only 21% among patients with invasive disease. A review by Shyr et al<sup>12</sup> found a cumulative 5-year survival of 92% for 51 cases. In a study by Loftus and colleagues<sup>13</sup> involving 15 patients, 3 of 4 patients with malignant IPMTs died of metastatic disease, and 2 of 11 patients with benign disease died although with no evidence of tumor spread.

MRCP has emerged as a new noninvasive technology to assess both pancreatic and bile ducts without the use of contrast material or endoscopy. A study by Koito and colleagues<sup>14</sup> compared MRCP to ERCP in the diagnosis of mucin-hypersecreting tumors of the pancreas. MRCP showed cystic dilated branches of the pancreas better than ERCP. The numbers of nodules or septa that were detectable by MRCP and ERCP were similar. The authors concluded that MRCP appears to be more effective than ERCP for the detection of intraductal cystic lesions of mucin-producing pancreatic tumors. Because some of these tumors are not malignant and do not require surgery, MRCP offers a less invasive alternative to ERCP for follow-up studies. In the study by Yamaguchi et al,<sup>15</sup> the details of cystic lesions of the branch ducts (eg, mural nodule, communication with main pancreatic duct) were more clearly demonstrated by ERCP than by MRCP. ERCP was clearly superior in demonstration of normal main pancreatic duct and its branches. These two studies suggest that both ERCP and MRCP are complementary studies that are helpful in the diagnosis and follow-up of patients with IPMTs.

Cellier and colleagues<sup>11</sup> reported on the role of EUS in assessing tumor extension and invasion in patients with IPMTs (Fig 2). They demonstrated that the sensitivity and specificity of EUS for invasive malignancy were 78% and 75%, respectively. The overall accuracy of EUS in assessing tumor invasiveness was 76%. The accuracy for EUS using the GF-UM-3 and GF-UM-20 was 82% and 70%, respectively. This compares with an accuracy of 76% and 79% for CT and ERCP, respectively. The accuracy of EUS in assessing tumor extension was 62% overall and varied from 63% to 60% when using the GF-UM-3 and GF-UM-20 instrument systems (Olympus Optical Co, Tokyo, Japan), respectively. Endoluminal endosonography using the UM-3R ultrasonic probe is a useful adjunct in the diagnosis of malignancy in patients with IPMTs. Inui and colleagues<sup>16</sup> studied 9 patients with IPMTs. The sensitivity, specificity, accuracy, positive predictive value, and negative predictive

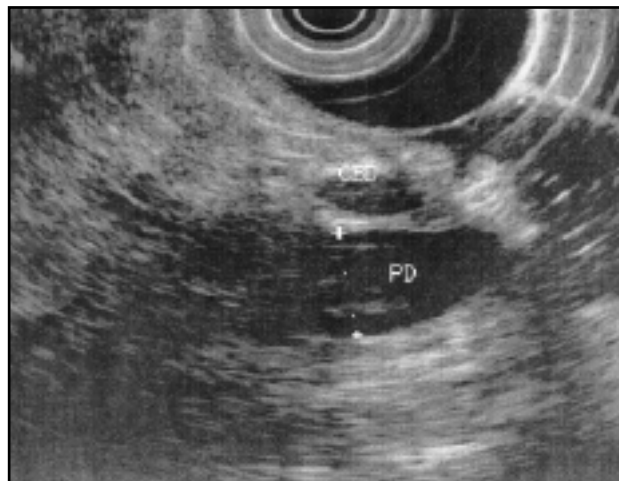

Fig 2. — EUS revealed a markedly dilated pancreatic duct with no mural vegetations. CBD = common bile duct, PD = pancreatic duct.

value for differentiation of malignant and benign design were 85.7%, 88.9%, 90.5%, 60.0%, and 96.9%, respectively. None of the patients developed acute pancreatitis, but high serum amylase levels were detected in 10% of the patients.

## Mucinous Cystic Neoplasms

Cystic pancreatic neoplasms consist of a heterogeneous group of pathologic entities, which share only cystic appearance on abdominal imaging and a predilection for female gender. The most common cystic pancreatic neoplasms are MCNs and serous cystadenomas. These two entities account for more than 75% of the cystic pancreatic neoplasms. Other less common cystic pancreatic neoplasms include papillary cystic tumors, cystic neuroendocrine tumor, cystic teratoma, lymphangioma, hemangioma, and paraganglioma.

MCNs are the most common cystic pancreatic neoplasms.<sup>17,18</sup> Eighty percent of MCNs occur in women with a mean age at presentation of 54 years. Abdominal pain, weight loss, early satiety, nausea and vomiting are among the most frequently reported symptoms. Twenty percent of MCNs and 50% of serous cystadenomas are asymptomatic and are discovered incidentally during laparotomy or radiological evaluation performed for an unrelated problem. Most MCNs consist of large loculi (macrocytic) filled with thick mucoid material. The walls are dense and fibrous and may even be calcified. Histologic evaluation reveals mucin-producing epithelial cells lining the cyst, but denudation of large areas of epithelium is common. In general, cystic tumors of the pancreas are distinguished from pseudocysts by the presence of solid components, septa, and loculations on CT scan and extracorporeal ultrasonography.<sup>19</sup> Calcifications can be seen in one third of cys-

Due to copyright restrictions, Table 3 has been removed from this online article.  
Please refer to the printed version found in *Cancer Control Journal*, V7, N5, to view this table.

microcystic type. The accuracy of EUS for differentiating tumors, as classified by two independent EUS observers blinded to the pathologic specimens, was estimated at 96% and 92%. Ikeda and coworkers<sup>24</sup> reported EUS criteria for follow-up of small pancreatic cysts (87.1% <2 cm) of unknown etiology. The cysts were classified as (1) a clear thin wall, (2) smooth contour, (3) round or oval shape, (4) no septum or nodule, (5) asymptomatic, and (6) no findings of chronic pancreatitis. After a follow-up of 3 years, 30 (97%) of 31 cases appeared to be nonprogressive. Following resection, the enlarging lesion was found to be a retention cyst. Sugiyama and colleagues<sup>25</sup> were able to reliably distinguish MCNs from intraductal papillary tumors by using a combination of EUS, ERCP, MRCP, and CT. EUS and MRCP demonstrated septa within cysts and mural nodules more accurately than ultrasonography, CT, and ERCP. EUS was significantly superior to ultrasonography, CT, and ERCP for the detection of mural nodules.

tic tumors and, unlike calcifications, are seen with pseudocysts arising from chronic pancreatitis. They never form part of the pseudocyst wall.

Misdiagnosis of a cystic neoplasm as a pancreatic pseudocyst either delays appropriate resection or leads to performance of an inappropriate procedure in as many as 37% of cases.<sup>18</sup> A thorough clinical history might provide some clues as to the nature of the pancreatic cystic lesion and might minimize confusion between these two entities. While a pseudocyst usually develops in the setting of chronic pancreatitis or following an episode of acute necrotizing pancreatitis, neoplastic cysts arise de novo. In rare instances, however, cystic tumors can cause acute pancreatitis due to obstruction of the pancreatic duct. While an elevated serum amylase supports the diagnosis of a pseudocyst, a normal value provides no discriminatory information. Cysts whose fluid is low in amylase are almost always neoplastic.

Identifying cystic lesions on the basis of imaging modalities is difficult, especially for solitary unilocular cysts. The diagnostic accuracy of cytology obtained by CT-guided aspiration is limited due to the difficulty in finding diagnostic cells, but the overall accuracy is 67% for malignant cysts and 40% for mucinous cysts.<sup>20</sup> To improve the diagnostic yield of cyst fluid analysis, both the physical characteristics of cyst fluid and other tumor markers in the cyst fluid have been studied (Table 3). The fluid within MCNs is more viscous than within serous cystadenomas. Carcinoembryonic antigen (CEA) appears to be the most useful marker for detecting MCNs.<sup>21</sup> Other markers such as CA-72-4 and CA 15-3 appear better at discerning benign from malignant lesions.<sup>22</sup>

The role of EUS in differentiating benign cystic lesions from malignant ones has been recently clarified. Koito and colleagues<sup>23</sup> used EUS to classify 52 cystic lesions according to the wall and septa characteristics. All nonneoplastic tumors belonged to the thin septa type or simple type, and all malignant tumors belonged to the thick wall, tumor-protruding, thick septal, or

microcystic type. The accuracy of EUS for differentiating tumors, as classified by two independent EUS observers blinded to the pathologic specimens, was estimated at 96% and 92%. Ikeda and coworkers<sup>24</sup> reported EUS criteria for follow-up of small pancreatic cysts (87.1% <2 cm) of unknown etiology. The cysts were classified as (1) a clear thin wall, (2) smooth contour, (3) round or oval shape, (4) no septum or nodule, (5) asymptomatic, and (6) no findings of chronic pancreatitis. After a follow-up of 3 years, 30 (97%) of 31 cases appeared to be nonprogressive. Following resection, the enlarging lesion was found to be a retention cyst. Sugiyama and colleagues<sup>25</sup> were able to reliably distinguish MCNs from intraductal papillary tumors by using a combination of EUS, ERCP, MRCP, and CT. EUS and MRCP demonstrated septa within cysts and mural nodules more accurately than ultrasonography, CT, and ERCP. EUS was significantly superior to ultrasonography, CT, and ERCP for the detection of mural nodules.

The presence of mural nodules suggests malignancy in both cystic tumor types. EUS therefore facilitates the diagnosis of serous cystadenomas, mucinous cystadenomas, and cystadenocarcinomas when microcysts, vegetation of the wall of a macrocyst, limited invasion of the pancreas due to the presence of vegetation, or a localized thickening of the wall of the cystic lesion are detected (Fig 3). Moreover, when faced with diagnostic uncertainty, EUS allows sampling of cystic fluid materi-

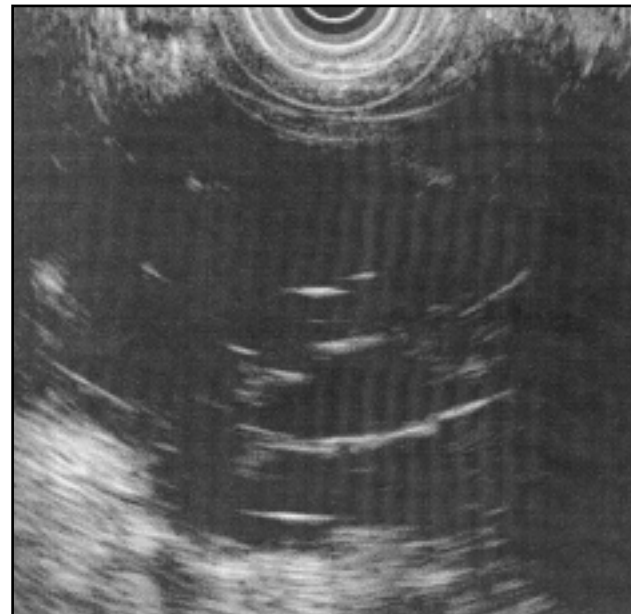


Fig 3. — EUS revealed a complex cystic lesion with multiple thin septa. EUS-guided FNA revealed markedly elevated CEA and CA 19-9 and low amylase. Pathology revealed a mucinous (macrocytic) cystadenoma.

al for biochemical analysis and evaluation of the mucins and tumor markers (Figs 3 and 4). In a study by Mallery et al,<sup>26</sup> the use of EUS-guided fine-needle aspiration (FNA) with cyst fluid analysis in pancreatic cystic lesions was evaluated in 20 patients. In addition to cytology, cyst fluid was sent for mucin staining and tumor markers (CEA, CA 125, CA 19-9, CA 72-4, CA 15-3, and tissue polypeptide antigen). Positive cytology or an elevated level of a tumor marker had an accuracy of 86%, a sensitivity of 83%, a specificity of 88%, a positive predictive value of 83%, and a negative predictive value of 88% for diagnosing a cystic neoplasm. Two patients developed self-limited pancreatitis, and no patients developed any infectious complications. Other groups<sup>27</sup> have encountered infectious complications up to 14% when aspirating pancreatic cystic lesions with EUS-guided FNA. Because of the potential risk of infection, our current practice is to administer antibiotics prior to aspirating a cystic lesion of the pancreas. A multicenter study is underway to evaluate the role of EUS-guided FNA in determining the nature of cystic pancreatic lesions preoperatively.

Treatment of cystic pancreatic neoplasms depends on the tumor's size, location, type, and extent. The prognosis depends on the tumor type and the resectability of the lesion. MCNs should be resected according to standard oncologic principles. The prognosis for completely resected MCNs is excellent, with a 5-year survival rate of more than 50% reported for malignant lesions. Long-term survival is possible in patients with cystadenocarcinomas, so these patients

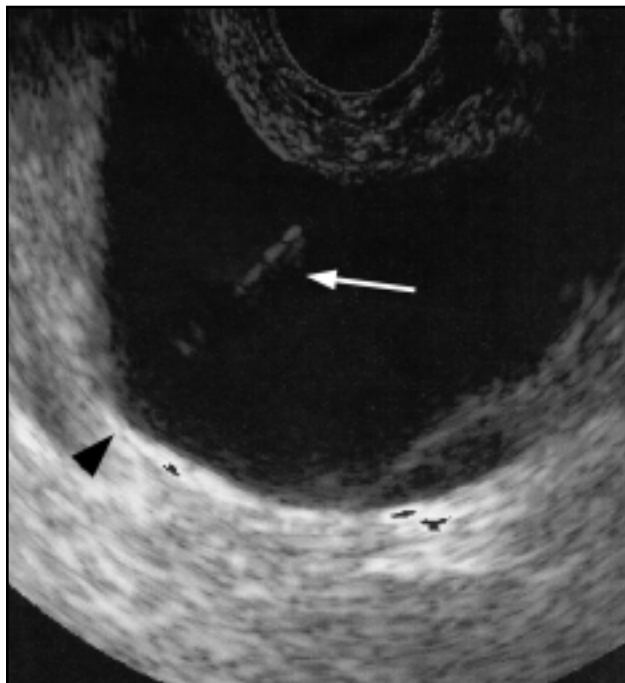


Fig 4. — Transgastric aspiration of a large simple cyst under EUS guidance (arrow = needle, arrowhead = cyst).

should undergo resection with the intent to cure even if a large tumor or local extension is found. In a series by Warsaw et al<sup>18</sup> of 42 patients with MCNs, 64% were found to be malignant. Sixty three percent of mucinous adenocarcinomas were judged to be resectable, and 22% had nonlocal metastases. Overall, 76% of patients with mucinous carcinomas resected with curative intent were alive, without evidence of recurrent disease, at a follow-up ranging from 6 months to 10 years. All patients with unresectable local or metastatic cancer died of their disease at an average of 4 months after having followed a rapid downhill course similar to that of unresectable pancreatic adenocarcinoma. In a review of 21 cases of cystadenocarcinomas, Hodgkinson and colleagues<sup>28</sup> noted a 5-year survival rate of 68% after complete excision compared with a 14% rate for those who had partial excision. Delcore and colleagues<sup>29</sup> reported 90% long-term disease-free survival among 10 patients with resectable mucinous cystadenocarcinomas, whereas 3 patients who underwent palliative resection died within 9 months. These two studies emphasize the prognosis and survival in these patients; localized and therefore resectable cystadenocarcinomas are highly curable, while those with distant spread have a dismal prognosis similar to patients with ductal adenocarcinoma.

## Conclusions

Mucinous-producing neoplasm of the pancreas, IPMTs and MCNs, are two distinct clinical entities, and they present a diagnostic and therapeutic challenge. They behave in an indolent manner, with frequent overlap of symptoms and radiological appearance with pancreatic cysts, pseudocysts, or malignancy. Both IPMTs and MCNs originate in the pancreatic duct epithelium, produce mucin, demonstrate a papillary growth pattern, and are considered to be premalignant or malignant at the time of diagnosis. Both lesions are less aggressive biologically than ductal adenocarcinoma, and they appear to infiltrate peripancreatic tissue and metastasize to lymph nodes or adjacent structures late in the course of the disease. IPMTs are located primarily in the head of the pancreas, predominantly affect elderly men, and present with acute or recurrent pancreatitis symptoms. MCNs are more likely to develop in the body or tail, are more commonly seen in women of middle age, and present with symptoms referable to a mass effect on adjacent structures. To diagnose these lesions preoperatively, a high index of suspicion is needed; factors that should heighten the suspicion include the presence of a cystic structure of the pancreas on abdominal imaging, the absence of a history of pancreatitis in a patient with a cystic lesion of the pancreas, and the presence of exuding mucus

from the major or minor papilla and the amorphous filling defects in an elderly patient undergoing ERCP. Cyst fluid aspiration and analysis preoperatively are helpful in differentiating between malignant and benign neoplasms. Both lesions are managed by surgical resection because the opportunity for cure is high in the absence of metastatic disease. Future studies are needed to improve the accuracy of diagnosing these tumors preoperatively.

*Appreciation is expressed to Mrs. Linda McDaniel for her assistance in reproducing the figures shown in this manuscript.*

## References

1. Lichtenstein DR, Carr-Locke DL. Mucin-secreting tumors of the pancreas. *Gastrointest Endosc Clin N Am.* 1995;5:237-258.
2. Becker WF, Welsh RA, Pratt HS, et al. Cystadenoma and cystadenocarcinoma of the pancreas. *Ann Surg.* 1965;161:845-863.
3. Ohhashi K, Murakami F, Takekoshi T, et al. Four cases of "mucin-producing" cancer of the pancreas on specific findings of the ampulla of Vater. *Prog Dig Endosc.* 1982;20:248.
4. Longnecker DS. Observations on the etiology and pathogenesis of intraductal papillary-mucinous neoplasms of the pancreas. *Hepatogastroenterology.* 1998;45:1973-1980. Review.
5. Rivera JA, Fernandez-del Castillo C, Pins M, et al. Pancreatic mucinous ductal ectasia and intraductal papillary neoplasms: a single malignant clinicopathologic entity. *Ann Surg.* 1997;225:637-646.
6. Yamada M, Kozuka S, Yamao K, et al. Mucin-producing tumor of the pancreas. *Cancer.* 1991;68:159-168.
7. Rivenson A, Hoffmann D, Prokopczyk B, et al. Induction of lung and exocrine pancreas tumors in F344 rats by tobacco-specific and Aroclor-derived N-nitrosamines. *Cancer Res.* 1988;48:6912-6917.
8. Itai Y, Kokubo T, Atomi Y, et al. Mucin-hypersecreting carcinoma of the pancreas. *Radiology.* 1987;165:51-55.
9. Cunningham JT, Hawes RH, Payne KM, et al. Clinical presentation and ERCP findings in patients with suspected intraductal papillary mucinous tumors (IPMTs). *Am J Gastroenterol.* 1999;94:A2627.
10. Seo DW, Kim MH, Lee SK, et al. The value of pancreatoscopy in patients with mucinous ductal ectasia. *Endoscopy.* 1997;29:315-318.
11. Cellier C, Cuillierier E, Palazzo L, et al. Intraductal papillary and mucinous tumors of the pancreas: accuracy of preoperative computed tomography, endoscopic retrograde pancreatography and endoscopic ultrasonography, and long-term outcome in a large surgical series. *Gastrointest Endosc.* 1998;47:42-49.
12. Shyr YM, Su CH, Tsay SH, et al. Mucin-producing neoplasms of the pancreas. Intraductal papillary and mucinous cystic neoplasms. *Ann Surg.* 1996;223:141-146.
13. Loftus EV Jr, Olivares-Pakzad BA, Batts KP, et al. Intraductal papillary-mucinous tumors of the pancreas: clinicopathologic features, outcome, and nomenclature: members of the Pancreas Clinic, and Pancreatic Surgeons of Mayo Clinic. *Gastroenterology.* 1996;110:1909-1918.
14. Koito K, Namieno T, Ichimura T, et al. Mucin-producing pancreatic tumors: comparison of MR cholangiopancreatography with endoscopic retrograde cholangiopancreatography. *Radiology.* 1998;208:231-237.
15. Yamaguchi K, Ogawa Y, Chijiwa K, et al. Mucin-hypersecreting tumors of the pancreas: assessing the grade of malignancy preoperatively. *Am J Surg.* 1996;171:427-431.
16. Inui K, Nakazawa S, Yoshino J, et al. Endoluminal ultrasonography for pancreatic diseases. *Gastroenterol Clin North Am.* 1999;28:771-781.
17. Fernandez-del Castillo C, Warshaw AL. Cystic tumors of the pancreas. *Surg Clin North Am.* 1995;75:1001-1016.
18. Warshaw AL, Compton CC, Lewandrowski K, et al. Cystic tumors of the pancreas: new clinical, radiologic, and pathologic observations in 67 patients. *Ann Surg.* 1990;212:432-445.
19. Johnson CD, Stephens DH, Charboneau JW, et al. Cystic pancreatic tumors: CT and sonographic assessment. *A J R Am J Roentgenol.* 1988;151:1133-1138.
20. Centeno BA, Warshaw AL, Mayo-Smith W, et al. Cytologic diagnosis of pancreatic cystic lesions: a prospective study of 28 percutaneous aspirates. *Acta Cytol.* 1997;41:972-980.
21. Lewandrowski KB, Warshaw AL, Compton CC, et al. Variability in cyst fluid carcinoembryonic antigen level, fluid viscosity, amylase content, and cytologic findings among multiple loculi of a pancreatic mucinous cystic neoplasm. *Am J Clin Pathol.* 1993;100:425-427.
22. Rubin D, Warshaw AL, Southern JF, et al. Expression of CA 15.3 protein in the cyst contents distinguishes benign from malignant pancreatic mucinous cystic neoplasms. *Surgery.* 1994;115:52-55.
23. Koito K, Namieno T, Nagakawa T, et al. Solitary cystic tumor of the pancreas: EUS-pathologic correlation. *Gastrointest Endosc.* 1997;45:268-276.
24. Ikeda M, Sato T, Ochiai M, et al. Ultrasonographic follow-up study of small pancreatic cysts of unknown etiology. *Bildgebung.* 1993;60:209-214.
25. Sugiyama M, Atomi Y, Kuroda A, et al. Two types of mucin-producing cystic tumors of the pancreas: diagnosis and treatment. *Surgery.* 1997;122:617-625.
26. Mallery S, Quirk D, Lewandrowski K, et al. EUS-guided FNA with cyst fluid analysis in pancreatic cystic lesions. *Gastrointest Endosc.* 1998;47:A149.
27. Wiersema M, Vilmann P, Giovannini M, et al. Prospective multicenter evaluation of EUS-guided fine needle aspiration biopsy (FNA): diagnostic accuracy and complication assessment. *Gastrointest Endosc.* 1996;43:432.
28. Hodgkinson DJ, ReMine WH, Weiland LH, et al. A clinicopathologic study of 21 cases of pancreatic cystadenocarcinoma. *Ann Surg.* 1978;188:679-684.
29. Delcore R, Thomas JH, Forster J, et al. Characteristics of cystic neoplasms of the pancreas and results of aggressive surgical treatment. *Am J Surg.* 1992;164:437-442.