

FACIAL CELLULITIS BY *PSEUDOMONAS AERUGINOSA* IN A NEUTROPENIC PATIENT

Anju Tallamraju, MD, John N. Greene, MD, Rama Ganguly, PhD, and Ramon L. Sandin, MD

From the Department of Medicine, Division of Infectious and Tropical Diseases (AT, JNG, RG) and the Department of Pathology (RLS) at the University of South Florida College of Medicine and the H. Lee Moffitt Cancer Center & Research Institute, Tampa, Fla.

Introduction

Focal and generalized head and neck lesions may occur in severely neutropenic patients following chemotherapy. Causes may be multiple and include leukemia infiltration, hemorrhage, corticosteroid administration, and infection.^{1,2} The most serious infection is from *Pseudomonas aeruginosa*, which remains a major cause of morbidity and mortality in neutropenic patients. Nearly 47% of these infections are nosocomial. Leukemia patients in particular receive more intensive myelosuppressive chemotherapy, resulting in longer periods of neutropenia and more frequent hospitalizations for antibiotic therapy. Both of these conditions favor microbial colonization and risk of infection.³ We report a neutropenic patient with facial cellulitis due to *P aeruginosa* and a brief review of head and neck pathology in the setting of neutropenia.

Case Report

A 45-year-old man with acute myelogenous leukemia received induction chemotherapy. His hospital course was complicated by the development of neutropenia and a left lower lobe pneumonia. Throat cultures grew *P aeruginosa*, although his blood cultures were negative. He received intravenous (IV) cilastatin-imipenem 500 mg four times daily, levofloxacin 500 mg daily, vancomycin 1 g twice daily, metronidazole 500 mg four times daily, and amphotericin 50 mg daily. The

pneumonia resolved both clinically and radiologically. Subsequent throat and blood cultures were negative. When oral ulcers developed that were culture-positive for herpes simplex virus, IV acyclovir 5 mg/kg thrice daily was administered. After a 3-week hospitalization, he was discharged with persistent neutropenia but no fever or signs of infection.

One month later, the patient was admitted again for a second course of induction chemotherapy due to failure to achieve remission. He remained neutropenic since diagnosis 6 weeks prior to admission, with a white blood cell count of 0.19/mm³ upon admission to the hospital. After 5 days of chemotherapy, fever developed along with left neck pain and swelling. Physical examination revealed diffuse swelling and slight erythema of the left tonsil and left neck, with extension to the left side of the face. An ulceration with a white base was seen on the gingiva near the lower left molar tooth. Blood cultures grew both *Clostridium perfringens* and *P aeruginosa*. CT scan of the head and neck showed left facial subcutaneous infiltration/swelling and maxillary mucosal thickening (Figure).

Treatment was started with piperacillin-tazobactam 3.375 g four times daily, gentamicin 160 mg thrice daily, clindamycin 900 mg thrice daily, famciclovir 500 mg twice daily, itraconazole 200 mg twice daily, and vancomycin 1,000 mg twice daily. Ciprofloxacin 400 mg twice daily was

added on hospital day 9. Amphotericin B lipid complex 500 mg daily IV was added on hospital day 10. After 4 weeks of treatment, gradual clearing of cellulitis occurred. Subsequent blood cultures were negative. Because of residual leukemia on bone marrow aspiration, the patient wanted to be at home with no further chemotherapy. The patient was sent home on oral ciprofloxacin 500 mg twice daily, amoxicillin/clavulanate 500 mg twice daily, and itraconazole 200 mg twice daily for 8 weeks. His WBC count on discharge was 0.16 cells/mm³, with a nadir of 0.08 cells/mm³ and total duration of neutropenia of 24 days while in the hospital.

Discussion

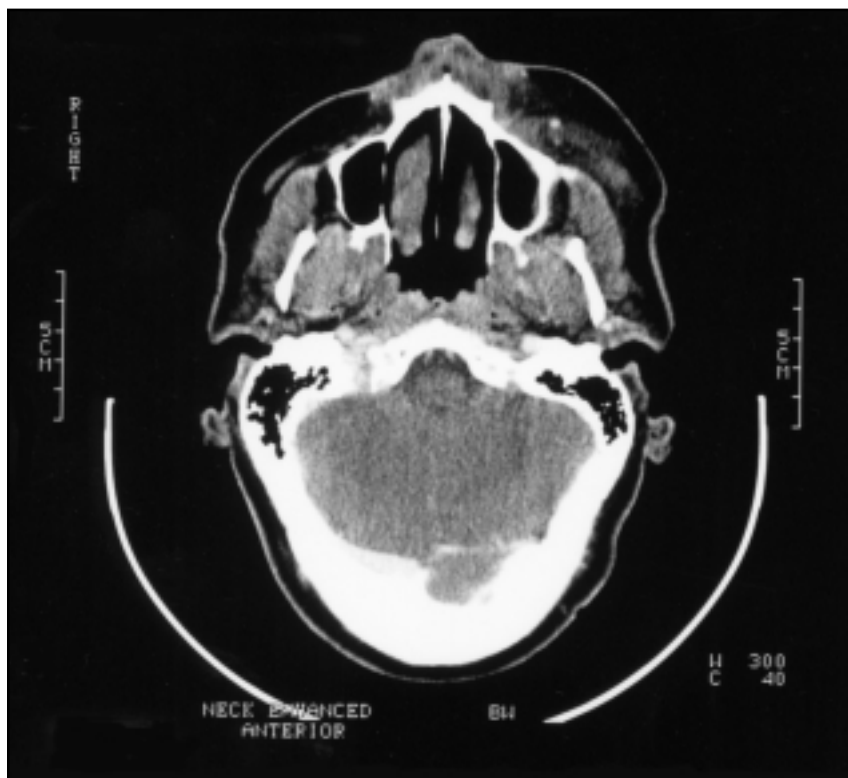
Cellulitis is characterized by an acute, diffuse spreading of inflammation into the dermis and subcutaneous tissues, often associated with systemic symptoms such as malaise and fever. Pathogens invade the dermis and subcutis, and the host immune system responds by mounting an acute inflammatory reaction.⁴ Cellulitis tends to be more severe and progresses more rapidly in the setting of neutropenia. Profound and prolonged neutropenia is the most important factor predisposing patients with leukemia to *Pseudomonas* infection.⁵ Dental infections, including abscesses, caries,

and root canal infections, are the most common portal of entry and are present in 15% of all head and neck cellulitis.⁶ In our patient, gum ulceration probably served as a portal of entry for *P. aeruginosa*. Other precipitating causes of facial cellulitis include sinusitis, upper respiratory tract infections, and oral herpes.^{7,8} *C. perfringens* in neutropenic patients can originate from an abdominal source such as typhlitis and may also be associated with spreading cellulitis, hemolysis, or gas gangrene.

Causes of Head and Neck Lesions During Neutropenia

Orbital Cellulitis

Orbital cellulitis is most commonly caused by *Staphylococcus aureus*, *Streptococcus* sp, and anaerobic bacteria. In children, *Haemophilus influenzae* type B was the most common cause of head and neck cellulitis.⁹ With the *H. influenzae* type B vaccination, non-type B *H. influenzae* is now more common. In addition to these pathogens, *P. aeruginosa* can cause orbital cellulitis. In cancer patients, especially those with lymphoma or leukemia, *Aspergillus sinusitis* spreading to the orbit is the most common organism associated with orbital cellulitis.¹⁰ Other predisposing factors include surgery, trauma, pre-existing ocular disease, and immunosuppressive therapy.¹¹ Affected patients usually present with acute onset of unilateral perior-



Computed tomography scan of the head reveals soft-tissue swelling in the maxillary area on the left with maxillary mucosal thickening.

bital pain, redness, edema, warmth, and tenderness. This life-threatening infection should be treated promptly and aggressively with anti-staphylococcal and two antipseudomonal antibiotics,¹² and amphotericin B or a lipid formulation of amphotericin B if fungal sinusitis is suspected.

Lingual Cellulitis

Lingual cellulitis is extremely rare.¹³ If it occurs in neutropenic patients, the inflammation and associated swelling of the soft tissue can advance quickly. Prompt surgical and medical management are required to prevent local progression. This has been reported in profoundly neutropenic patients with acute myeloblastic leukemia.¹³ It may occur after minor local trauma, followed by infections with organisms colonizing the mouth. Anaerobic streptococci and pseudomonas have been isolated from blood cultures.

Tonsillitis

Tonsillitis in the setting of neutropenia is most commonly caused by anaerobic bacteria such as *Capnocytophaga ochracea* and *Fusobacterium* sp. Usually, this entity is diagnosed only when blood cultures are positive because anaerobic cultures of the oropharynx cannot be obtained without a tissue biopsy. The treatment of choice is a penicillin-containing antibiotic or clindamycin.

Cryptococcus neoformans usually causes chronic meningitis or pneumonia, or it can be completely

asymptomatic early in the course.¹⁴ One case of cryptococcal tonsillitis in a patient with chronic lymphocytic leukemia was reported.¹⁵ He presented with left tonsillar enlargement without exudate. Blood cultures and excisional biopsy of the involved tonsil revealed the presence of *C. neoformans*. He was successfully treated with amphotericin B and flucytosine for 6 weeks.

Malignant Otitis Externa

Malignant otitis externa is a serious, locally invasive *Pseudomonas* infection that typically occurs in elderly diabetic patients.^{16,17} Severe otalgia is the usual presenting complaint. Purulent drainage and granulation tissue in the external auditory canal are usually found on examination. Local cellulitis and bone destruction are best documented by computed tomography scan or magnetic resonance imaging techniques. Malignant otitis externa has been reported in three severely neutropenic children with acute lymphoblastic leukemia who were receiving induction chemotherapy.¹⁸ All of them presented with pain, extensive soft-tissue involvement, and profound discharge. External ear canal cultures showed prolific growth of *P. aeruginosa* and *S. aureus*. They were treated with a 2-week regimen of intravenous antibiotics and regular suctioning and washing of the canal to remove debris and necrotic tissue. Although rare, external otitis with local extension into the mastoid due to *Aspergillus* infection can occur in patients with prolonged neutropenia.

Ramsay Hunt Syndrome

Ramsay Hunt syndrome is caused by reactivation of the latent varicella-zoster virus infection harbored in the geniculate ganglion.¹⁹ It is most common in immunocompromised patients, usually presenting with vesicles over the pinna and external auditory meatus, facial nerve palsy, and auditory involvement (tinnitus, vertigo, and deafness). It has been reported recently in a patient with malignant granulosa cell tumor of the ovary who developed Ramsay Hunt syndrome following aggressive chemotherapy.²⁰ She presented with classical symptoms and signs. Tzanck smear from the vesicular lesions showed acantholytic and inflammatory cells with an occasional binucleated pattern suggesting herpes zoster virus. She was treated with high-dose acyclovir. Skin lesions and pain rapidly resolved, but facial paralysis persisted partially. Risk factors for reactivation varicella infection include radiation therapy, chemotherapy, and corticosteroid use as well as the underlying malignancy.

Acute Bilateral Parotitis

Acute bacterial parotitis typically occurs in elderly, dehydrated, intubated, or postoperative patients. The most common pathogen associated with acute parotitis is *S. aureus*, followed by viridans streptococci.²¹ However, acute parotitis resulting from anaerobes, enteric Gram-negative bacilli, and *P. aeruginosa* has also been documented.^{22,23} Patients usually present with pain, swelling, and dysphagia. On examination, symptoms

include tense swelling over the parotid area, tenderness, and pain on opening the mouth. In cancer patients, the occurrence of acute bilateral parotitis may not be related to an infectious agent but can be caused by chemotherapy. Chemotherapy-induced acute parotitis occurred in three patients with acute myeloid or lymphoblastic leukemia who were being treated with L-asparaginase, daunorubicin, or cytarabine.^{24,26} The parotitis persisted throughout chemotherapy administration and resolved promptly upon discontinuation of the drugs.

Leukemic Infiltration

Cutaneous involvement in certain types of leukemia is not uncommon. An unusual case of leukemic infiltration of the skin secondary to acute myeloblastic leukemia mimicking cellulitis has been reported.²⁷ The patient presented with bilateral periorbital edema and erythema clinically simulating infectious periorbital cellulitis. Pathologic evidence of polymorphonuclear leukocyte infiltrate in the dermis suggested the presence of pyoderma gangrenosum, a condition that has been shown to coexist with leukemic infiltration.²⁸

Conclusions

The sinuses and oropharynx can be entry sites for infections in the neutropenic cancer patient. Mucositis, a common complication of chemotherapy and radiation therapy, may lead to the development of aggressive local head and neck

infections when neutropenia develops. Our patient exhibited the rare presentation of *P. aeruginosa* causing facial cellulitis. Although head and neck infections in cancer patients can have grave consequences, most patients respond well to prompt antimicrobial therapy.

References

1. Barrett AP. Facial cellulitis responsive to flucloxacillin in acute leukemia. *Ann Dent.* 1989;48:28-29.
2. Barrett AP. Oral mucosal complications in cancer chemotherapy. *Aust N Z J Med.* 1984;14:7-12.
3. Fergie JE, Patrick CC, Lott L. *Pseudomonas aeruginosa* cellulitis and ecthyma gangrenosum in immunocompromised children. *Pediatr Infect Dis J.* 1991;10:496-500.
4. Johnson RA. Complete dermatologist's guide to cellulitis. In: Fitzpatrick TB, ed. *Fitzpatrick's Journal of Clinical Dermatology.* Cambridge, Mass: Kenet Medical Pub; 1994:12-23.
5. van der Meer JW, Alleman M, Boekhout M. Infectious episodes in severely granulocytopenic patients. *Infection.* 1979;7:171-175.
6. Kimura AC, Pien FD. Head and neck cellulitis in hospitalized adults. *Am J Otolaryngol.* 1993;14:343-349.
7. Jackson K, Baker SR. Clinical implications of orbital cellulitis. *Laryngoscope.* 1986;96:568-574.
8. Ginsberg MB. Cellulitis: analysis of 101 cases and review of the literature. *South Med J.* 1981;74:530-533.
9. Weiss A, Friendly D, Eglin K, et al. Bacterial periorbital and orbital cellulitis in childhood. *Ophthalmology.* 1983;90:195.
10. Harris GJ, Will BR. Orbital aspergillosis. Conservative debridement and local amphotericin irrigation. *Ophthalm Plast Reconstr Surg.* 1989;5:207-211.
11. Rosenhoff SH, Wolf ML, Chabner BA. *Pseudomonas* blepharoconjunctivitis: a complication of combination chemotherapy. *Arch Ophthalmol.* 1974;91:490-491.
12. Atkins MC, Harrison GA, Lucas GS. *Pseudomonas aeruginosa* orbital cellulitis in four neutropenic patients. *J Hosp Infect.* 1990;16:343-349.
13. Smith OP, Prentice HG, Madden GM, et al. Lingual cellulitis causing upper airways obstruction in neutropenic patients. *BMJ.* 1990;300:24.
14. Liss HP, Rimland D. Asymptomatic cryptococcal meningitis. *Am Rev Respir Dis.* 1981;124:88-89.
15. Korvick J, Yu VL. *Cryptococcal* tonsillitis in a patient with chronic lymphocytic leukemia: an unusual manifestation of cryptococcal disease. *Am J Hematol.* 1987;25:475-478.
16. Doroghazi RM, Nadol JB Jr, Hyslop NE Jr, et al. Invasive external otitis. Report of 21 cases and review of the literature. *Am J Med.* 1981;71:603-614.
17. Chandler JR. Malignant external otitis. *Laryngoscope.* 1968;78:1257-1294.
18. Wolff LJ. Necrotizing otitis externa during induction therapy for acute lymphoblastic leukemia. *Pediatrics.* 1989;84:882-885.
19. Hunt JR. The sensory field of the facial nerve: a further contribution to the symptomatology of the geniculate ganglion. *Brain.* 1915;38:418-419.
20. Shivaprakash P, Deo RP, Raghavan A, et al. Ramsay Hunt syndrome in a patient of malignant granulosa cell tumour of ovary. *J Indian Med Assoc.* 1997;95:197-200.
21. Raad II, Sabbagh MF, Caranasos GJ. Acute bacterial sialadenitis: a study of 29 cases and review. *Rev Infect Dis.* 1990;12:591-601.
22. Brook I, Finegold SM. Acute suppurative parotitis caused by anaerobic bacteria: report of two cases. *Pediatrics.* 1978;62:1019-1020.
23. Pruett TL, Simmons RL. Nosocomial gram-negative bacillary parotitis. *JAMA.* 1984;251:252-253.
24. Sica S, Pagano L, Salutari P, et al. Acute parotitis during induction therapy including L-asparaginase in acute lymphoblastic leukemia. *Ann Hematol.* 1994;68:91-92.
25. Humphries JE, Lee JT. Acute bilateral parotitis during chemotherapy for acute lymphoblastic leukemia. *Acta Haematol.* 1992;88:55-56.
26. Shpilberg O, Ra'anani P, Ben-Bassat I, et al. Recurrent bilateral parotitis in acute myeloid leukemia. *Acta Haematol.* 1991;86:56.
27. Schimpff SC, Greene WH, Young VM, et al. Significance of *Pseudomonas aeruginosa* in the patient with leukemia or lymphoma. *J Infect Dis.* 1974;130:S24-S31.
28. Thall E, Grossniklaus H, Cappaert W, et al. Acute monocytic leukemia presenting in the eyelid: an immunohistochemical and electron microscopic study. *Ophthalmology.* 1986;93:1628-1631.