



Adrian Deckbar. *Café Interior*. Pastel over giclée, 27" × 40". Courtesy of the Hanson Gallery, New Orleans, Louisiana.

*Use of the sentinel lymph node procedure probably eliminates occurrence of the postmastectomy pain syndrome.*

# The Effect of Sentinel Node Selective Axillary Lymphadenectomy on the Incidence of Postmastectomy Pain Syndrome

*Rafael Miguel, MD, Ann M. Kuhn, MD, Alan R. Shons, MD, PhD, Patricia Dyches, RN, Mark D. Ebert, BS, Eric S. Peltz, BS, Keoni Nguyen, BS, and Charles E. Cox, MD*

**Background:** *Postmastectomy pain syndrome (PMPS) has been reported following procedures involving complete lymph node dissection (CLND). Since the triggering event is probably related to nerve injury, sentinel lymph node dissection (SLND) should decrease the incidence of PMPS. The purpose of this report is to determine the impact of SLND on the number of patients referred to the pain clinic for PMPS treatment.*

**Methods:** *The records of all breast surgical patients with a diagnosis of PMPS referred to the Moffitt Cancer Center pain clinic were reviewed. The criterion for diagnosis of PMPS was a history of postoperative pain in the upper anterior chest wall, upper extremity, axilla, and/or shoulder in the absence of recurrent disease.*

**Results:** *A total of 55 patients with a diagnosis of PMPS were seen in the pain clinic since 1991. Treatments included local anesthetics/corticosteroid injection, stellate ganglion block, and tricyclic antidepressants. A decrease from 15 patients in 1991 to 3 in 1998 was observed. All but one of the 55 patients with PMPS had CLND, and none referred to the pain clinic had undergone SLND.*

**Conclusions:** *PMPS is a complication of CLND. The increased use of SLND in our center has reduced the number of referrals to the pain clinic for treatment of PMPS. This benefit of SLND reduces suffering in the postoperative breast patient.*

*From the Departments of Anesthesiology (RM, PD) and Surgery (AMK, ARS, MDE, ESP, KN, CEC), at the H. Lee Moffitt Cancer Center & Research, Tampa, Florida.*

*Submitted July 1, 2001; accepted August 21, 2001.*

*Address reprint requests to Rafael Miguel, MD, Anesthesiology Service, H. Lee Moffitt Cancer Center & Research Institute, 12902*

*Magnolia Drive, Suite 2149, Tampa, FL 33612-9497. E-mail: miguel@moffitt.usf.edu*

*No significant relationship exists between the authors and the companies/organizations whose products or services may be referenced in this article.*

## Introduction

Post mastectomy pain syndrome (PMPS) is a neuropathic pain condition that can follow surgical treatment for breast cancer, including radical mastectomy, modified radical mastectomy, and segmental mastectomy (lumpectomy).<sup>1,2</sup> PMPS is thought to develop from surgical damage to the intercostobrachial nerve, the lateral cutaneous branch of the second intercostal nerve that is often resected at mastectomy.<sup>3</sup> This nerve is injured in 80%-100% of mastectomy patients who undergo axillary dissection.<sup>4,5</sup> Other possible causes of pain after breast surgery are the development of a traumatic neuroma and damage to nerves other than the intercostobrachial nerve, such as the lateral branches of the intercostal nerves. Radiation injury with secondary pain at the costochondral junctions may induce referred pain to the lateral intercostal nerve branches. The pain is a deafferentation-type pain syndrome and typically occurs in the regions innervated by damaged nerves such as the anterior thorax, axilla, and/or medial upper arm.<sup>3,6</sup> Tumor involvement or radiation fibrosis in the brachial plexus may also cause PMPS.<sup>3,5</sup>

Abnormal sensation in the axilla and medial aspect of the arm has been reported in 23%-100% of women presenting with PMPS.<sup>4,5</sup> Symptoms include an electric shock-like pain sensation overlying a continuous aching and burning associated with chronic dysesthesia.<sup>3</sup> Pain typically begins in the immediate postoperative period but may be delayed 6 or more months after surgery. The pain characteristically persists beyond the normal healing period. As a result, the ability to perform activities of daily living and occupational activities may be impaired.<sup>5</sup>

While PMPS has been described after simple mastectomy and lumpectomy and usually results from injury to the medial branches of the intercostal nerves, it is more commonly seen after procedures involving complete axillary lymph node dissection (CLND). Since the triggering event is related to nerve injury of the cutaneous branches of the intercostal nerves, identifying and dissecting only the nodes primarily responsible for lymphatic drainage (sentinel lymph node dissection, SLND) from the area of the lesion should decrease nerve trauma and PMPS incidence. In this study, we sought to evaluate the effect of SLND on the incidence of PMPS and the number of referrals to the pain management team for treatment.

## Background

Frequently misdiagnosed as brachial plexopathy, disease recurrence, or emotionally derived pain, PMPS

is the result of tissue or nerve injury.<sup>7</sup> While tissue injury is secondary to the surgical procedure, nerve injury can occur via several sources. Intercostobrachial nerve injury has been described in 80%-100% of mastectomy patients undergoing axillary dissection. This nerve injury has been implicated as the major cause of axillary and upper arm pain.<sup>5</sup>

The characteristics of PMPS, its location, and its timing in relation to the surgical procedure allow exclusion of other types of postmastectomy discomfort. Nonneuropathic pain, pain outside the distribution of the nerves affected, and pain directly related to the surgery or wound healing process may indicate other etiologies.<sup>1</sup> When defining pain after breast surgery based on these criteria, Smith et al<sup>1</sup> found that PMPS had a cumulative prevalence of 43% and a point prevalence of 29.2%.

PMPS appears to occur more commonly following breast-conserving treatment than following modified radical mastectomy.<sup>8,9</sup> In one study, approximately half of 467 women reported pain, paresthesia, or strange sensations more often after partial breast resection than after modified radical mastectomy.<sup>10</sup> Gerber et al<sup>11</sup> reported a higher incidence of pain at both 1 and 6 years post-surgery among women treated with lumpectomy and radiotherapy. This was attributed to the effects of radiation on the periosteum of the ribs. Stevens and colleagues<sup>12</sup> reported a 20% prevalence rate of PMPS in 95 women after breast surgery. These chronic treatment-related symptoms were more common after breast resection (breast-conserving therapy) than after modified radical mastectomy. Carpenter et al<sup>8</sup> reported similar findings of a higher incidence of PMPS with breast-conserving surgery when combined with axillary dissection, radiation, and chemotherapy.

Several factors can be hypothesized to increase the risk of developing PMPS after breast cancer surgery, including younger age at diagnosis, a larger tumor size, axillary node invasion, and use of chemotherapy and/or radiation therapy. Postoperative complications such as bleeding, infection, or seroma formation may increase the risk of developing PMPS. Further research is required to negate or validate these hypotheses. Surgical techniques also play an important role in PMPS, particularly those that routinely remove the intercostobrachial nerves.<sup>8</sup>

Description of the anatomic landmarks of SLND as described by Cox et al<sup>13</sup> indicate that the lateral branches of the third intercostal nerve are at risk for injury. Thus, while limiting the risk of nerve injury, SLND may still result in nerve damage unless care and attention are paid to nerve location.

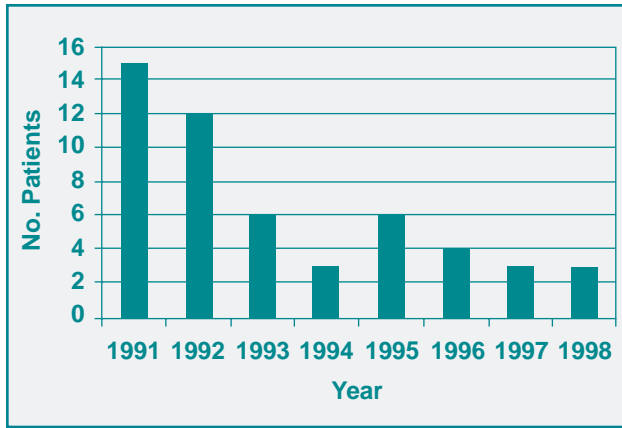


Fig 1. — The number of patients with a diagnosis of PMPS who were treated in the pain clinic from 1991 to 1998.

## Methods

The records of all breast surgical patients referred to the Interventional Pain Clinic at our center from 1991 to 1998 were reviewed after institutional approval for chart reviews was obtained. All patients evaluated for PMPS were included in the survey. Information extracted from the medical records included (1) type of breast surgery, (2) documentation of ipsilateral pain with a temporal association to the surgery developing postoperatively in the upper anterior chest wall, upper extremity, axilla, and/or shoulder in the absence of recurrent disease, and (3) types of therapeutic interventions.

The patients' pain was treated with with an established treatment algorithm. If the patient complained of pain only along the scar, intralesional local anesthetic/steroid injections and/or 0.075% capsaicin cream were used. Patients with pain occurring in the upper extremity, upper arm, lower arm, or hand received stellate ganglion injections. Medications such as tricyclic antidepressants were prescribed when patients complained of difficulty sleeping and/or required an adjuvant to neuropathic pain therapy.

## Results

From 1991 to 1998, a total of 1,009 breast cancer surgeries were performed at our institute. Within this time frame, 55 patients were treated in the pain clinic with a diagnosis of PMPS. A progressive decrease in referrals to the pain clinic for PMPS treatment from 15 patients in 1991 to 3 in 1998 was observed (Fig 1). During this period, there was an increase in the number of SLNDs performed compared to the number of CLNDs performed.

Stellate ganglion blocks were used as therapy in 46 (85%) of the 55 patients. Eleven patients (20%)

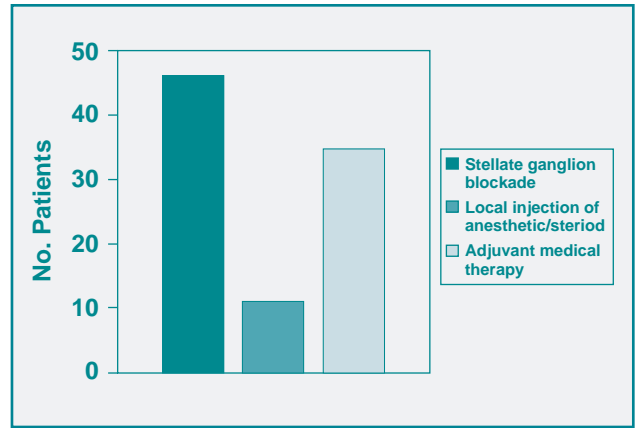


Fig 2. — Treatment of pain following breast cancer surgery as administered by the pain clinic.

required other blocks (local anesthetic/steroid, intercostal blocks) for pain control, and 35 (64%) required adjuvant medical therapy such as tricyclic antidepressants, opioids, nonsteroidal anti-inflammatory drugs (NSAIDs), and/or capsaicin (Fig 2). A total of 305 patient encounters for pretreatment were required. CLND had been performed in 54 of the 55 patients with PMPS; a simple mastectomy was performed in one patient. No patient with PMPS had received selective SLND.

## Discussion

The reported incidence of PMPS from 4%-31% suggests that many women suffer from this syndrome.<sup>4,6,8</sup> Our group found a similar incidence. In our review, 13% of the 1,009 women who were operated for breast cancer complained of pain 3 months after operation. When patients with intractable pain due to breast cancer were considered, 14% suffered from PMPS. Half had daily pain that ranged from mild to moderate. Half reported continuous pain that was worse with movement. Pain involved the axilla in 84%, the medial upper arm in 74%, the anterior chest wall in 58%, and the shoulder in 32%. Fifty percent of patients stated that the pain manifested itself with daily chores, and 50% reported a sleep disturbance.

The type of breast surgery performed may affect the incidence of PMPS, but this is not the only contributing factor.<sup>6,8</sup> Even though SLND may reduce the incidence of PMPS, many women will still experience significant pain secondary to breast cancer treatment, and quality of life will be notably impaired despite adequate treatment.<sup>4,5</sup>

The initial treatment of PMPS involves routine use of NSAIDs and analgesics. However, regional nerve blockade, adjuvant medications, and transcutaneous

electrical nerve stimulation occasionally are necessary for pain management.<sup>9</sup> The neuropathic pain of PMPS is often resistant to conventional modes of pain control.<sup>12,14</sup> Medications such as anticonvulsants and antidepressants are commonly used for the relief of neuropathic pain. Regional nerve blocks using a local anesthetic or neurolytic agent are recommended for otherwise intractable pain. However, the use of neurolytic agents are controversial in a patient with no recurrence. Nonpharmacologic interventions such as massage therapy and acupuncture may also be helpful in relieving pain.<sup>3</sup>

Another pain relief strategy commonly used for PMPS involves capsaicin, a topical analgesic.<sup>9,14</sup> This agent is believed to act by interrupting transmission of pain impulses through small-diameter nerve fibers by depleting substance P, the neurotransmitter. Capsaicin is effective in patients with neuromas.

PMPS is a common complication of CLND. This retrospective chart review suggests that selective SLND may have resulted in a reduction of referrals for PMPS treatment. The patients studied in this series were deliberately referred (ie, refractory to conservative measures such as NSAIDs and mild opioids) and therefore may not reflect the true incidence of PMPS. Similarly, other factors that may have affected pain clinic referrals and the incidence of PMPS include changes in breast surgeon personnel and preference and/or changes in surgical technique. While these factors were not found in this review, the possible impact of such factors underscores the limitations of a retrospective analysis. To determine if SLND significantly reduces the true incidence of PMPS, all patients treated for breast cancer will need to be evaluated during a prospective, controlled study. A questionnaire to report pain following surgery would allow analysis of whether SLND resulted in a decreased incidence of PMPS within the study population.

The occurrence and impact of PMPS have generally been overlooked in the breast cancer literature. In the pain literature, however, neuropathic pain has been described as agonizing, intractable, intense, and debilitating. While reports that attribute this caliber of neuropathic pain to women who have PMPS are rare, the intensity of the pain is often severe, with approximately half of these women experiencing continuous pain. In almost all cases, the pain was incapacitating to some degree and interfered with their performance of daily occupational and domestic activities.<sup>15</sup>

The increased use of selective SLND at our center may have reduced the need for pain clinic referrals for treatment of PMPS. This unexpected benefit of selec-

tive SLND has reduced suffering and costs in the postoperative breast cancer patient population and merits further study.

## References

1. Smith WC, Bourne D, Squair J, et al. A retrospective cohort study of post mastectomy pain syndrome. *Pain*. 1999;83:91-95.
2. Carpenter JS, Sloan P, Andrykowski MA, et al. Risk factors for pain after mastectomy/lumpectomy. *Cancer Pract*. 1999;7:66-70.
3. Kwekkeboom K. Postmastectomy pain syndromes. *Cancer Nurs*. 1996;19:37-43.
4. Wallace MS, Wallace AM, Lee J, et al. Pain after breast surgery: a survey of 282 women. *Pain*. 1996;66:195-205.
5. Wallace AM, Wallace MS. Postmastectomy and postthoracotomy pain. *Anesthesiol Clin North America*. 1997;15:353-370.
6. Assa J. The intercostobrachial nerve in radical mastectomy. *J Surg Oncol*. 1974;6:123-126.
7. Watson CP, Evans RJ. Intractable pain with breast cancer. *Can Med Assoc J*. 1982;126:263-266.
8. Carpenter JS, Andrykowski MA, Sloan P, et al. Postmastectomy/postlumpectomy pain in breast cancer survivors. *J Clin Epidemiol*. 1998;51:1285-1292.
9. Dini D, Bertelli G, Gozza A, et al. Treatment of the post-mastectomy pain syndrome with topical capsaicin. *Pain*. 1993;54:223-226.
10. Tasmuth T, von Smitten K, Kalso E. Pain and other symptoms during the first year after radical and conservative surgery for breast cancer. *Br J Cancer*. 1996;74:2024-2031.
11. Gerber L, Lampert M, Wood C, et al. Comparison of pain, motion, and edema after modified radical mastectomy vs. local excision with axillary dissection and radiation. *Breast Cancer Res Treat*. 1992;21:139-145.
12. Stevens PE, Dibble SL, Miaskowski C. Prevalence, characteristics, and impact of postmastectomy pain syndrome: an investigation of women's experiences. *Pain*. 1995;61:61-68.
13. Cox CE, Haddad F, Bass S, et al. Lymphatic mapping in the treatment of breast cancer. *Oncology (Huntingt)*. 1998;12:1283-1298.
14. Watson CP, Evans RJ, Watt VR. The post-mastectomy pain syndrome and the effect of topical capsaicin. *Pain*. 1989;38:177-186.
15. Griffith CD, Dowle CS, Hinton CP, et al. The breast pain clinic: a rational approach to classification and treatment of breast pain. *Postgrad Med J*. 1987;63:547-549.