



Lu Jian Jun. *The Dulcimer*, 2000. Oil on canvas, 36" × 48". Courtesy of Weinstein Gallery, San Francisco, California.

The indications and approach using CO₂ laser surgery in carcinomas of the upper aerodigestive tract are reviewed.

Transoral Laser Microsurgery in Carcinomas of the Oral Cavity, Pharynx, and Larynx

*Jochen A. Werner, MD, Anja A. Dünne, MD,
Benedikt J. Folz, MD, and Burkard M. Lippert, MD*

Background: *Since the introduction of laser technology in the 1960s, use of the technique in treating laryngeal diseases has demonstrated several advantages over conventional resections in selected cases.*

Methods: *The authors review the published data on oncologic laser surgery for the treatment of head and neck carcinomas, and they also describe their own clinical experience with transoral laser surgery for the treatment of carcinomas of the oral cavity, pharynx, and larynx.*

Results: *Laser surgery has achieved a key position in minimally invasive treatment concepts in the ears, nose, and throat area, especially for the treatment of malignancies of the upper aerodigestive tract. The CO₂ laser is the approach most commonly used.*

Conclusions: *New and improved applications of laser therapy in the treatment of cancer are being explored. As more surgeons become experienced in the use of lasers and as our knowledge of the capabilities and advantages of this tool expands, lasers may play a larger role in the management of head and neck cancers.*

Introduction

The word *laser* is an acronym for light amplification by stimulated emission of radiation. Since their development in 1960, lasers as surgical tools have evolved and now play an important role in the diagnosis and treatment of cancer. Laser treatment is more precise, decreases the change of infection, and reduces healing time, bleeding, swelling, and scarring. Several laser systems, such as the diode, ruby, Ho:YAG, Er:YAG, Nd:YAG, and yellow light lasers, as well as dye lasers for photodynamic therapy, have been used for treating var-

From the Department of Otolaryngology, Head and Neck Surgery, Philipps University of Marburg, Germany.

Submitted June 18, 2002; accepted August 5, 2002.

Address reprint requests to Jochen A. Werner, MD, Department of Otolaryngology, Head and Neck Surgery, Philipps University Marburg, Deutschhausstr. 3, 35037 Marburg, Germany. E-mail: j.a.werner@mail.uni-marburg.de

No significant relationship exists between the authors and the companies/organizations whose products or services may be referenced in this article.

Oral Carcinomas

The surgical approach and histologic confirmation of clear margins for early stages of oral cancer differ slightly from those for other regions within the upper aerodigestive tract. The areas involved by tumor are exposed with the aid of gags and tongue depressors. Special instruments can be used to optimize the access to the operative site. For instance, small carcinomas (1 or 1.5 cm in diameter) of the tongue are excised en bloc but with a relatively wide resection margin of 5 to 10 mm. When excising the tumor, care must be taken to maintain a uniform tumor margin in the deeper muscular layers. If the superficial extension

of the tumor is greater than 10 mm in diameter or if there are signs of deep infiltration, one or more incisions can be made through the tumor, depending on its localization and extent (Fig 1). Transecting the tumor may help to estimate more accurately the depth of tumor infiltration. These surgical steps are performed under the operation microscope and are designed to render a higher level of oncologic safety in the excision of these carcinomas.^{4,5}

Mobile Tongue and Floor of the Mouth

During laser microsurgical dissection, the tumor is traced into the surrounding healthy tissue regardless of the direction and degree of its extension. For carcinomas of the floor of the mouth, two conditions deserve a more detailed discussion (Fig 2). The first is the inclusion of excretory ducts of the sublingual and submandibular glands into the resection; the second is the modification of the procedure if the mandible is involved. The excretory ducts of the lesser salivary glands can be severed or partially resected. We rarely observe complications such as chronic inflammation with intermittent swelling of the gland, which may eventually necessitate the excision of the gland following laser microsurgical resection of oral carcinomas. This observation is explained by the fact that the main excretory duct is generally preserved in cases of super-

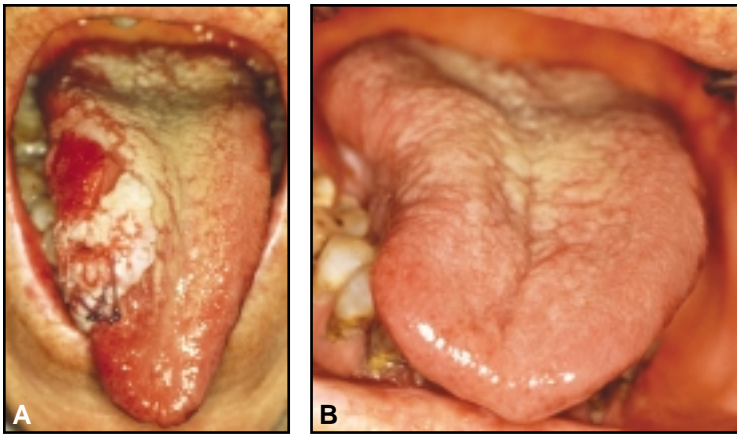


Fig 1. — (A) T2 carcinoma of the right margin of the mobile tongue before laser microsurgery. (B) Good functional results are seen 24 months following laser microsurgery.

ious diseases. However, the argon and CO₂ lasers were the first laser systems to be clinically used in the treatment of otorhinolaryngology. The CO₂ laser currently has the greatest significance in otorhinolaryngology, predominantly in the treatment of carcinomas of the upper aerodigestive tract.

Strong and Jako¹ introduced the CO₂ laser into microsurgery of the larynx in the early 1970s. The CO₂ laser was increasingly utilized in the 1980s in the treatment of benign lesions in the larynx, particularly recurrent laryngeal papillomatosis. However, lasers were introduced more slowly in the treatment of malignancies and were restricted to only a few centers throughout the world. Furthermore, the application of lasers was mostly limited to the excision of early vocal cord tumors. The first reports of the successful use of lasers in cancer surgery were published in 1975.² Their guidelines regarding the indications of laser tumor surgery were carefully followed, with few alterations. Burian and Höfler were the first in Europe to successfully treat a glottic carcinoma with the laser.³ As early as the beginning of the 1980s, Steiner¹ expanded the indications for curative laser treatment to all regions and all tumor types. This expansion was based on the excellent results obtained with both the microsurgical laser resection of early tumors and the palliation of advanced disease. Meanwhile, laser surgery achieved a key position in minimally invasive treatment concepts in the ears, nose, and throat (ENT) area, especially for the treatment of malignancies of the upper aerodigestive tract. In advanced cases, the primary aim of laser surgery is organ preservation.¹

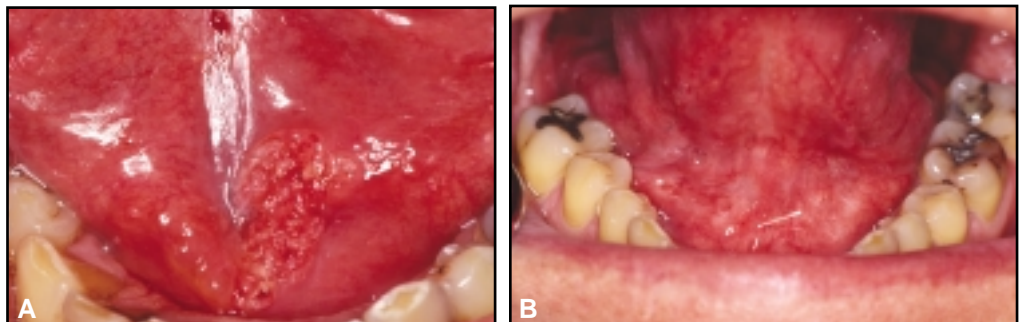


Fig 2. — (A) T1 carcinoma of the floor of the mouth before microsurgery and (B) 16 months after laser microsurgery.

ficial carcinomas. On the other hand, the pressure of the saliva is usually strong enough to keep the lumen open and prevent stenosis.

At our institute, we excise the tumor with a safety margin of at least 5 mm. The periosteum can be dissected with the laser or a rasp. The basal surface is marked with blue ink and is submitted for histologic examination. If infiltration into the mandible is suspected, the area in question is widely excised. In resections of the floor of the mouth and the inferior surface of the mobile tongue, we cover the resected area with split thickness skin grafts that are usually harvested from the groin. The size of the graft should be larger than the size of the laser wound to compensate for expected shrinkage of the graft. Before we applied this technique regularly, we occasionally observed considerable scarring and subsequent reduction of tongue mobility.

Buccal Mucosa and Oral Surface of the Soft Palate

Superficial and exophytic carcinomas of the buccal mucosa that do not break through the skin of the cheek or infiltrate the parotid gland can be resected completely with the CO₂ laser using a microsurgical technique. Laser microsurgical resection of small carcinomas of the buccal mucosa does not require coverage of the defect with grafts because these wounds usually heal spontaneously and without significant functional impairment.

Resection of carcinomas of the soft palate follows a similar pattern (Fig 3). The carcinomas are often larger than expected, which may lead to extensive defects of the soft palate with accompanying functional defects, including rhinophonia, which must be addressed. In palliative cases or in cases in which extensive surgical resections are not indicated, a palatal obturator can be utilized, or covering the defect with a flap might be considered. In these cases, reconstruction is best performed with the help of a free radial forearm flap.

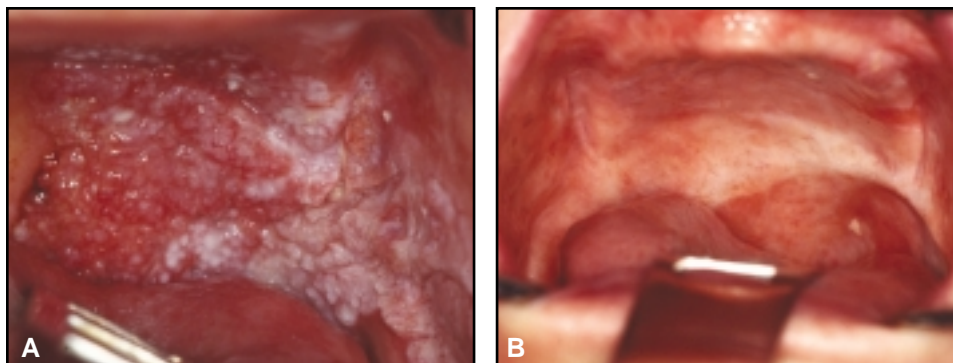


Fig 3. — (A) T3 verrucous carcinoma of the soft and hard palate in an 85-year-old woman before laser microsurgery and (B) 20 months after laser microsurgery.

In these cases, CO₂ laser surgery is well suited for the precise and hemostatic resection of carcinomas. The resulting defects, however, should be treated according to the same principles that are applied following conventional surgery.^{6,7} Depending on the site and extent of the primary tumor, the resulting defect can be covered using reconstructive flap surgery. In cases of relevant defects of the soft palate, we prefer reconstruction with the free radial forearm flap. The reconstruction is often key in preventing velar insufficiency and thus regurgitation of ingested food into the nasopharynx or the nose. Laterally based oropharyngeal tumors may require excision via partial resection of the mandible. In these cases, we cover the defect with the greater pectoralis muscle.

Posterior Wall of the Oropharynx

Most small tumors of the posterior pharyngeal wall can be completely resected without any difficulties. If tumor extension has occurred toward the hypopharynx or nasopharynx is present, the resection is extended accordingly. The superior border usually can be exposed adequately with the help of palatal retractors. The bivalved laryngoscope is used in cases with significant inferior extension. Tumors with deep infiltration of the posterior wall of the oropharynx are managed similarly to those of the hypopharynx. However, this technique has limitations. For example, laser surgical resection does not appear to be indicated if the carcinoma infiltrates the anterior longitudinal ligament of the spine. Therefore, preoperative imaging studies such as magnetic resonance imaging are mandatory in these cases. If tumor extension into the nasopharynx is evident, transitory division of the soft palate is sometimes required to achieve an adequate exposure.

Lateral Wall of the Oropharynx

The surgical and histologic procedures for carcinomas of the tonsil differ slightly from those of other regions. The different tissue structure and growth characteristics of tumors in this area necessitate a modification of the surgical approach and histologic confirmation of a complete resection. Well-circumscribed lesions that are up to 1 cm in diameter and have a more superficial growth pattern can be excised en bloc. We also utilize en bloc resection for a larger tonsillar carcinoma located on the surface of

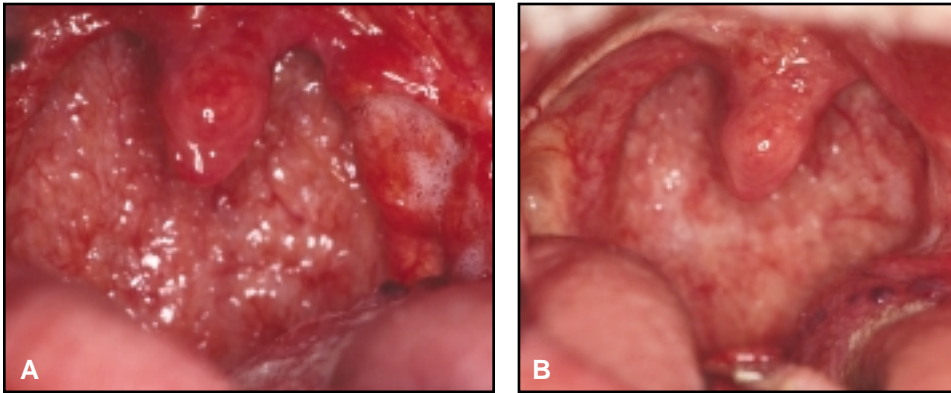


Fig 4. — (A) Small T2 carcinoma of the left tonsil before transoral laser microsurgery and (B) 22 months following surgery.

the submucosal space, are oncologically unfavorable characteristics of these cancers. Identification of the tumor borders is more difficult in the tongue than in the larynx. The more pronounced carbonization encountered during laser surgery of tongue tissue is a result of the increased vascularization and the glandular tissue present in the tongue.

the tonsil that still can be luxated. In these cases, transoral tumor tonsillectomy is performed (Fig 4). Larger tumors in the area of the tonsil are resected in several pieces as described by Steiner and Ambrosch.⁸ We perform at least three horizontal incisions — one superiorly, one through the middle, and one inferiorly. It is important to be aware of the depth of tumor extension during surgical procedures in the tonsillar area. Branches of the ascending palatine artery (from the facial artery) and the descending palatine artery (from the maxillary artery), as well as branches of the ascending pharyngeal artery, are ligated conventionally or with vascular clips.

The glossotonsillar sulcus is another high-risk area for deeper and more extensive resections involving larger arterial vessels such as the lingual artery and the external carotid artery. Other important structures in the immediate proximity are the hypoglossal and glosso-pharyngeal nerves. The same safety precautions apply here as in the area lateral to the tonsil. In these cases, we cover the defect with collagen mesh and fibrin glue. Patients with advanced oropharyngeal carcinomas are treated with neoadjuvant radiochemotherapy. Six to 8 weeks after radiochemotherapy, the tumor area is resected lasersurgically within the initial tumor border, and a unilateral or bilateral neck dissection is performed. To resect the tumor area properly, the tumor border is tattooed initially during panendoscopy. In our experience with a limited number of patients, laser surgical resection does not appear to be associated with delayed wound healing or an increase in the number of complications with regard to the functional outcome. Our results suggest that further investigation involving a larger number of patients is warranted.

Base of Tongue and Vallecula

A number of factors complicate the technically simple laser resection of carcinomas of the tongue. The relatively common tumor extensions, especially into

Laser surgical treatment of cancer of the base of the tongue presents a challenge even for experienced surgeons. Apart from the postcricoid region, the base of the tongue is the area of highest risk for endoscopic surgery, especially if exposure through the bivalved laryngoscope is not optimal. Also, differentiating between tumor and healthy tissue can be particularly difficult in the area of the tongue base due to obstruction by the lingual tonsil. In addition, achieving adequate access to this region to allow sufficient exposure to all areas involved by tumor can be difficult. In many cases, the surgeon can see only a particular segment and may lack any surrounding landmarks for orientation, such as the pyriform sinus or larynx.

Laser surgical removal of the lingual tonsil may be of oncologic relevance in the diagnostic workup of cancer of unknown primary (CUP syndrome). An occult primary tumor would more likely be revealed if the surgical specimen were processed during pathohistologic examination in serial sections rather than through random biopsies. In laser surgical resection of the lingual tonsil, care should be taken to avoid dissection into the lateral pharyngeal tissue or muscular layer, which may increase the risk of severe hemorrhage.

Laryngeal Carcinomas

The surgical, oncologic, and functional principles are the same for minimally invasive surgery as for more conventional resections. The primary objective is the complete resection of the tumor while preserving as much function as possible. The principle is to minimize surgical morbidity while adhering to long-standing oncologic standards.

During transoral laser microsurgery, decisions are made in accordance with the local spread of the tumor. The tumor extension is often clearly apparent under the microscope, and the lesion is resected until healthy

tissue is found and appropriate safety margins can be maintained. The goal of complete resection is achieved by variations in the surgical approach and dissection instrument. In general, a transoral approach is the primary choice, and the CO₂ laser under microscopic control is used as a dissecting instrument.

All tumor surgery should adhere to the principle of complete resection with clear surgical margins that are histologically documented. This involves the cooperation of both the surgeon and the pathologist. Using a small focal diameter of the laser beam results in minimal carbonization and is particularly suitable for this application. The histologic assessment of the resection margins is facilitated by this technique, despite relatively close margins.^{9,10}

The unconventional surgical technique of dissecting through larger tumors during the resection and removing the tumor in parts allows the surgeon to inspect the surface of the tissue under microscopic control. There are no indications that the incidence of late regional or distant metastases increases due to laser incisions through a tumor; this may be explained by the sealing effect of the lymph vessels, which has been observed in previous investigations.¹¹

Carcinoma In Situ, Microinvasive Carcinoma, and Small T1a Carcinomas

In cases of a biopsy-proven small carcinomas or carcinoma in situ, the entire lesion is excised with an appropriate resection margin (Fig 5). When tumor invade is found in the resection margin, two treatment strategies are possible: laser surgery or radiotherapy. We recommend repeating laser or conventional surgery because, in most cases where tissue is re-resected from the tumor margin, this tissue is tumor-free on histopathologic investigation, and radiotherapy would

have been unnecessary. Our experience indicates that, in general, vocal function is almost normal following such limited-excision biopsies.¹²

Large T1a and T1b Glottic Carcinomas

When a clearly superficial lesion infiltrates to a depth of only approximately 2 mm and does not cover the entire cord (ie, microcarcinoma), we excise the carcinoma en bloc. When the depth of infiltration is in doubt, a single incision through the center of the tumor may help to estimate the depth. The subsequent laser surgical treatment is the same as for small, well-circumscribed lesions. In cases of marginal involvement of the anterior commissure without subglottic extension, the anterior commissure is resected along with the bilateral cord lesion. The dissection is carried out along the thyroid cartilage under high magnification of the operating microscope. Laser surgical resections of carcinomas of the anterior commissure require a surgeon experienced in this technique because the risk of developing recurrent disease is more likely in the anterior commissure than in any other localization of the glottis.¹³⁻¹⁵

T2 Carcinomas

For all T2 carcinomas of the glottis, primary laser surgery is advocated regardless of the pattern of tumor spread. Steiner¹⁶ reported that it is of no significance whether the tumor is unilateral or bilateral, whether it extends to involve supraglottis or subglottis, or whether it infiltrates the anterior commissure. Again, a surgeon with wide experience in laser surgery is essential. Superficially spreading carcinomas are ideally suited for laser surgery. Even if they cover vast areas of the endolarynx, they can be resected completely with a partial mucosectomy of the larynx if the carcinoma can be exposed adequately.¹⁷ The excision can be performed in several

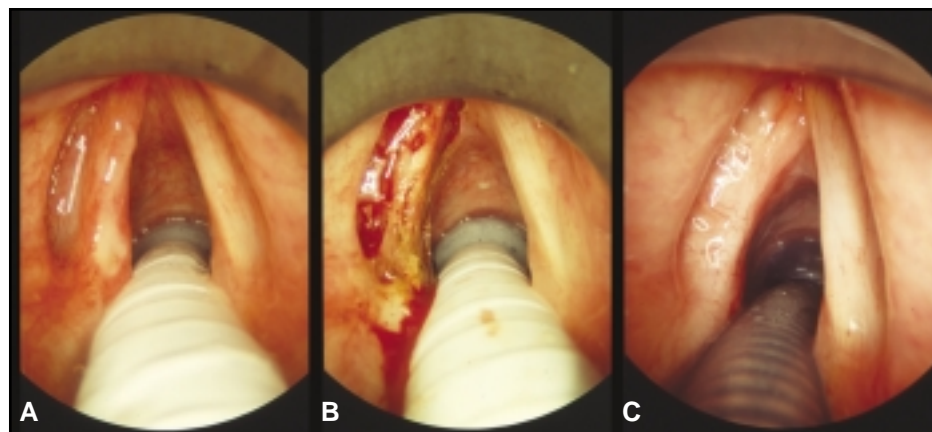


Fig 5. — (A) Intraoperative view of a T1a carcinoma of the left vocal cord before laser microsurgical resection and (B) immediately after resection. (C) Two years postoperatively, no recurrent disease can be observed and functional results are satisfactory.

pieces, and the basal surfaces should be stained with blue ink for better orientation of the pathologist. Exact topographic descriptions on the pathology request form are important and should be copied onto patient charts. Additionally, the exact origin of the individual specimen must be noted in a schematic drawing of the larynx.

T3 Carcinomas

Currently, the majority of resectable carcinomas are

treated with conventional surgery. However, laser surgical resection is feasible even for large tumors if they can be exposed adequately and if the surgeon has the required training in laser surgery. For these advanced tumors of the glottis, incisions are placed through the bulk of the tumor to divide it into smaller portions, laterally onto the thyroid cartilage and inferiorly onto the superior surface of the cricoid cartilage. Incisions follow the extensions of the tumor and are placed deeply into the musculature until a tissue layer is encountered that reacts normally to the laser light under the microscope. If the musculature is invaded up to the perichondrium, the tumor can be resected by dissecting along the inner table of the thyroid cartilage. Suspected infiltration of the thyroid cartilage or definite penetration through parts of the cartilage is included in the resection. A specimen resected from the neighboring prelaryngeal soft tissues can be used to verify the completeness of the resection. The resection of extended carcinomas should be performed by a surgeon experienced in laser surgery to avoid an incomplete resection that would adversely affect the patient's prognosis. Conventional surgery is preferred where an experienced surgeon is unavailable.

Supraglottic Carcinomas

Small, well-circumscribed tumors of the supraglottis can be resected in one piece, similar to small lesions on the vocal cord.¹²

Suprahyoid Epiglottis and False Cord Area: Technically, tumors in this location can be easily excised. Wide resection margins can be achieved without functional implications as in the case of glottic lesions.

Infracord Epiglottis: The depth of tumor infiltration in the area around the petiole is difficult to assess preoperatively. There may be considerable difficulty in distinguishing between a T1 tumor and a T3 lesion (infiltration of the pre-epiglottic space). To determine the extent of the carcinoma to the pre-epiglottic space, we usually split the suprahyoid epiglottis sagittally. The bivalved laryngoscope is subsequently advanced, thus revealing the surface of the dissection plane through the epiglottic cartilage as well as the pre-epiglottic fat and the laryngeal surface of the infracord epiglottis with the tumor. The tumor is then dissected in a sagittal plane. The dissection proceeds in an inferior direction. Depending on the extent of the tumor, horizontal cuts are placed through the bulk of the lesion. If the thyroid cartilage or one of the arytenoid cartilages is infiltrated by tumor, it is included in the resection. During the resection of parts of the thyroid cartilage, care is taken to avoid damage to the

extralaryngeal vessels. If the tumor has broken through the thyrohyoid membrane, it is followed as far into the neck as possible. The resection can reach all the way into the subcutaneous tissue of the neck. Persistent functional impairments are not anticipated with this surgery.

Resection of advanced carcinomas requires attention to postoperative function. Resection of one arytenoid cartilage is not associated with long-lasting functional impairment; however, if both arytenoids are resected, deglutition without aspiration is usually not possible. Additional difficulties may occur if further resections in the area of the base of the tongue are required.¹⁸ As already noted, the resection of extended carcinomas is reserved for surgeons with extensive experience with laser surgery.

Hypopharyngeal Carcinomas

The pretherapeutic assessment includes an endoscopic examination (under general anesthesia) and computed tomography imaging. The results of these investigations determine if a partial resection is possible and justified. Tumor extension on the mucosal surface as seen by the examiner is rarely a reflection of true tumor extent. Carcinomas of the pyriform sinus can invade the paraglottic and pre-epiglottic space, the area of the arytenoid cartilages, the thyroid cartilage, or the soft tissues of the neck without any evidence of such invasion on endoscopy. Only extensive infiltration (for example, into the cricoarytenoid joint) will clinically indicate the deep invasion of the tumor by impaired mobility or fixation of the arytenoid cartilage.

If laser surgical resection is indicated, a step-by-step resection of the tumor in a craniocaudal direction is generally recommended. The tumor is removed "blockwise" and layer by layer. The dissection proceeds inferiorly as far as good exposure and accessibility of the tissues in the dissection plane are assured. The tumor is divided into a mosaic-like pattern by horizontal and vertical cuts. The border between tumor and healthy tissue can be identified on the tissue section. The bivalved laryngoscope is generally positioned so that a margin of normal tissue of approximately 10 mm remains between the blade of the speculum and the edge of the visible tumor. The incision into the mucosa must be made under the highest possible magnification of the microscope.¹⁹

In summary, tumor and normal tissue can be particularly well differentiated in the hypopharynx. Relatively wide resection margins of 5 to 10 mm can be achieved in this area without major functional conse-

quences caused by additional loss of tissue, thus resulting in safer tumor resections. In all hypopharyngeal tumors, spontaneous healing with complete epithelialization of the wound occurs after their resection. Healing is usually complete within 6 weeks with good functional results.

Indications for Laser Applications in Tumor Resection

Similar to the decision-making process in conventional surgery, determining the appropriate laser application for surgical resection of carcinomas of the upper aerodigestive tract, especially advanced carcinomas, is based on thorough preoperative diagnostic criteria. When invasion of deeply located structures or extralaryngeal tumor spread is evident on computed tomography scans or magnetic resonance images, a laser surgical approach is appropriate, but only in the hands of experienced surgeons. Compared with the surgical skill needed to resect a tumor through an open approach with an open surgical field and excellent exposure, a higher level of expertise is required to achieve good oncologic results in resecting inaccessible carcinomas or advanced laryngeal and pharyngeal carcinomas through a progressively narrow endoscope. This skill level is particularly necessary if the tumor must be resected endoscopically in several portions. These cases illustrate the need for intensive training in endoscopic laser surgery in order to achieve sound oncologic results with laryngeal and pharyngeal laser microsurgery. The functional and oncologic outcomes obtained with this technique closely correlate to the experience of the surgeon. A conventional surgical approach should be chosen if the tumor is too difficult to expose or the surgeon has only limited experience with laser surgery in advanced carcinomas.

Therapeutic Concept Beyond Laser Surgery

With regard to the prognosis of patients with head and neck cancers, therapy of the lymphatic system is of primary importance. Adequate treatment of the clinically node-negative neck (N0 neck) is the central point of controversy. At present, there is no uniformly accepted standard for the surgical treatment of the N0 neck in carcinomas of the head and neck. Recommendations range from no surgical intervention but with strict follow-up control, to a limited selective neck dissection as a solitary therapeutic measure even with histologic proof of metastases, or to a modified radical neck dissection in N0 necks and localized primary tumors.

Given the variability in treatment concepts among oncologic centers, certain guidelines need to be recognized. From our viewpoint, adopting a “wait-and-see” strategy rather than selective neck dissection may be justified in patients with a reliable compliance and in centers with broad expertise in ultrasonography imaging of the neck. With regard to surgical treatment, we anticipate that selective neck dissection will gain more acceptance in treating the N0 neck than modified radical neck dissection. The extent of selective neck dissection is determined by the localization of the tumor — whether it is localized unilaterally or whether it reaches the midline or even expands over the midline. An exception to this strategy is T1 carcinoma of the vocal cord. A similar approach is currently supported in the literature for T2 glottic carcinoma.¹⁶ However, advanced T2 glottic carcinoma, a low grade of differentiation of the primary tumor, as well as lymphangitis carcinomatosa, may warrant selective neck dissection in certain cases (levels II-III and possibly even level IV) even in these selected T2 glottic carcinomas cases. For all other tumor locations of the oral cavity, pharynx, and larynx, we currently recommend selective neck dissection. This usually includes levels I-III in carcinomas of the oral cavity and levels II-IV in oropharyngeal, laryngeal, and hypopharyngeal carcinomas.

Optimal therapy of the clinical N1 neck is also a controversial issue. In cases of glottic or hypopharyngeal carcinomas, consideration should be given to altering the modified radical neck dissection to ensure that lymph nodes of level I remain intact. However, in the clinical N2 neck, there is general consensus that a modified radical neck dissection should be performed.

In cases of a representative node dissection with a histologically proven N0 neck or single, isolated lymph node metastasis without extranodal spread or lymphangitis carcinomatosa, we do not include adjuvant radio-chemotherapy in cases of total laser microsurgical resection of the primary.

Neck dissection is one technique that can be utilized within the context of the laser surgical primary resection or as a second-line approach. Steiner¹⁶ often used the second-line approach with an interval of approximately 1 week between tumor resection and neck dissection. As a result of intensive investigations on the role of the sentinel node concept for squamous cell carcinoma of the upper aerodigestive tract,^{20,21} we perform neck dissections as single-stage procedures parallel to laser surgical resections of the primary tumor in N0 neck cases because validity of the intraoperative proof of the initially draining lymph node correlates closely to the physiologic lymphatic drainage.

References

1. Strong MS, Jako GJ. Laser surgery in the larynx: early clinical experience with continuous CO₂ laser. *Ann Otol Rhinol Laryngol*. 1972;81:791-798.
2. Strong MS. Laser excision of carcinoma of the larynx. *Laryngoscope*. 1975;85:1286-1289.
3. Burian K, Höfler H. On microsurgical treatment of vocal cord carcinomas with CO₂ laser. *Laryngol Rhinol Otol (Stuttg)*. 1979;58:551-556.
4. Steiner W, Werner JA, eds. *Lasers in Otorhinolaryngology, Head and Neck Surgery*. Tuttlingen: Endo-Press; 2000.
5. Jäckel M, Steiner W. Ear, nose and throat techniques in endoluminal surgery. *Minim Invasive Ther*. 1998;7:9-14.
6. Steiner W, Aurbach G, Ambrosch P. Minimally invasive therapy in otorhinolaryngology head and neck surgery. *Minim Invasive Ther*. 1991;1:57-70.
7. Rudert H, Werner JA, Höft S. Transoral carbon dioxide laser resections of supraglottic carcinomas. *Ann Otol Rhinol Laryngol*. 1999;108:819-827.
8. Steiner W, Ambrosch P, eds. *Endoscopic Laser Surgery of the Upper Aerodigestive Tract: With Special Emphasis on Cancer Surgery*. Stuttgart, New York: Thieme; 2000.
9. Rudert H, Werner JA. Partial endoscopic resection with the CO₂ laser in laryngeal cancer. I. Resection techniques [German]. *Laryngorhinootologie*. 1994;73:71-77.
10. Rudert H, Werner JA. Partial endoscopic resection with the CO₂ laser in laryngeal carcinomas. II. Results [German]. *Laryngorhinootologie*. 1995;74:294-299.
11. Werner JA, Lippert BM, Schünke M, et al. Animal experiment studies of laser effects on lymphatic vessels: a contribution to the discussion of laser surgery segmental resection of carcinomas [German]. *Laryngorhinootologie*. 1995;74:748-755.
12. Rudert H, Werner JA. Endoscopic resections of glottic and supraglottic carcinomas with the CO₂ laser. *Eur Arch Otorhinolaryngol*. 1995;252:146-148.
13. Eckel HE, Schneider C, Jungehulsing M, et al. Potential role of transoral laser surgery for larynx carcinoma. *Lasers Surg Med*. 1998;23:79-86.
14. Eckel HE. Local recurrences following transoral laser surgery for early glottic carcinoma: frequency, management, and outcome. *Ann Otol Rhinol Laryngol*. 2001;110:7-15.
15. Puxeddu R, Argiolas F, Bielamowicz S, et al. Surgical therapy of T1 and selected cases of T2 glottic carcinoma: cordectomy, horizontal glottectomy and CO₂ laser endoscopic resection. *Tumori*. 2000;86:277-282.
16. Steiner W. Results of curative laser microsurgery of laryngeal carcinomas. *Am J Otolaryngol*. 1993;14:116-121.
17. Werner JA, Dünne AA, Folz BJ, et al. Laser surgery for T2 glottic carcinoma. *Otorhinolaryngol Nova*. 2002. In press.
18. Werner JA, Steiner W. Endoscopic laser treatment of laryngeal and tracheal diseases. In: Berlien HP, ed. *Applied Laser Medicine*. Berlin: Springer; 2002. In press.
19. Steiner W, Ambrosch P, Hess CF, et al. Organ Preservation by transoral laser microsurgery in pyriform sinus carcinoma. *Otolaryngol Head Neck Surg*. 2001;124:58-67.
20. Werner JA, Dünne AA, Ramaswamy A, et al. The sentinel node detection in N0 cancer of the pharynx and larynx. *Br J Cancer*. 2002. In press.
21. Werner JA, Dünne AA, Ramaswamy A, et al. Number and location of radiolabeled, intraoperatively identified sentinel nodes in 48 head and neck cancer patients with clinically staged N0 and N1 neck. *Eur Arch Otorhinolaryngol*. 2002;259:91-96.