



Kala Pohl. *Let's Stick Together*. Acrylic on canvas, 24" × 30".

*The prognostic factors, potential biomarkers, surgical strategies, and adjuvant therapy trials for patients with locally advanced renal cell carcinoma are reviewed.*

# Management of Locally Advanced Renal Cell Carcinoma

Alejandro Rodriguez, MD, and Wade J. Sexton, MD

**Background:** Renal cell carcinoma accounts for approximately 3% of adult malignancies and over 90% of primary renal tumors. Recurrence rates for patients with locally advanced renal cell carcinoma (LARCC) remain high.

**Methods:** The authors review literature regarding prognostic factors, potential biomarkers, surgical strategies, and adjuvant therapy trials for patients with LARCC.

**Results:** Molecular tumor markers may improve existing staging systems for predicting prognosis. Surgery is the best initial treatment for most patients with clinically localized renal tumors, although complete surgical resection can be challenging for patients with large tumors, bulky regional lymph node involvement, or inferior vena cava tumor thrombus. Significant recurrence rates for patients with LARCC undergoing nephrectomy indicate the presence of undetected micrometastases at the time of surgery. Adjuvant radiation, chemotherapy, and immunotherapy have been ineffective. Other trials of adjuvant therapy are ongoing.

**Conclusions:** Aggressive surgical resection alone for LARCC is not sufficient to prevent disease recurrence in a significant number of patients. Adjuvant therapies are needed to improve cancer-specific survival.

From the Genitourinary Oncology Program, H. Lee Moffitt Cancer Center & Research Institute, Tampa, Florida.

Address correspondence to Wade J. Sexton, MD, Genitourinary Oncology Program, H. Lee Moffitt Cancer Center & Research Institute, 12902 Magnolia Drive, Tampa, FL33612. E-mail: sextonwj@moffitt.usf.edu

Submitted March 1, 2006; accepted May 2, 2006.

No significant relationship exists between the authors and the companies/organizations whose products or services may be referenced in this article.

**Abbreviations used in this paper:** RCC = renal cell carcinoma, LARCC = locally advanced renal cell carcinoma, VHL = von Hippel-Lindau, HIF-1 $\alpha$  = hypoxia-inducible factor-1 alpha, VEGF = vascular endothelial growth factor, CAIX = carbonic anhydrase IX, IVC = inferior vena cava, ECOG = Eastern Cooperative Oncology Group, IL = interleukin, IFN = interferon.

## Introduction

Surgery is the most efficacious therapy for patients with nonmetastatic, localized renal cell carcinoma (RCC). Progression-free survival and overall survival following nephrectomy are dependent on factors such as pathologic T stage, tumor grade, lymph node status, and performance status.<sup>1,2</sup> Patients with low-stage, low-grade, and often incidentally detected renal tumors have a favorable long-term prognosis.<sup>1-3</sup> For patients with metastatic disease at presentation, nephrectomy followed by systemic immunotherapy increases overall survival by 3 to 10 months compared with patients

treated with immunotherapy alone.<sup>4,5</sup> Still, with multimodality therapy, the median survival for patients with metastatic disease is only 10 to 12 months, and just 2% of such patients survive long-term.<sup>6</sup> Centered between these two clinical extremes are many patients with locally advanced renal cell carcinoma (LARCC) at risk for progression and death from their renal tumors due to adverse clinical and pathologic variables determined at the time of presentation or following surgery. Given the almost uniformly fatal outcome for patients who develop metastatic disease, several factors are paramount to the successful treatment of these patients: a better understanding of the variables that influence disease recurrence and progression, an understanding of the surgical principals required to render a patient disease free, and the development of adjunctive therapies to extend recurrence and progression-free intervals of patients with locally advanced disease.

This article characterizes LARCC, reviews the markers associated with advanced disease, and examines the outcome for patients undergoing nephrectomy. Finally, different surgical options for managing LARCC are described, and the results of adjuvant therapy trials aimed at improving progression rates and survival are reviewed.

## Characteristics of LARCC

### *Diagnosis and Staging*

The preoperative assessment of patients with a renal lesion has three principal aims: to make the diagnosis of RCC, to assess the stage of disease, and to delineate the anatomic detail necessary for operative planning. Patients with LARCC can present with a myriad of signs and symptoms attributable to the primary tumor to include the classic triad of flank pain, hematuria, and a palpable mass. However, with the increasing use of cross-sectional imaging, the majority of RCCs are currently diagnosed incidentally during the investigation of unrelated complaints.<sup>7</sup>

RCCs comprise 85% to 90% of renal masses that are radiologically demonstrated to be solid. Therefore, they may be presumptively diagnosed on this basis. Differentiation of renal cysts exhibiting complex features such as thickness, nodularity, calcification of the cyst wall, internal septations, or heterogeneity is mandatory, and a systematic assessment using these objective criteria facilitates the estimation of the risk of malignancy.<sup>8</sup> Needle biopsy of renal masses is prone to inaccuracy.<sup>9,10</sup> Other than for suspected metastases<sup>11</sup> or lymphoma,<sup>12</sup> biopsy is not routinely recommended for making management decisions.

Once the diagnosis of RCC has been established, clinical staging requires radiologic assessment of the extent of local or distant disease. Imaging of the chest,

**Table 1. — Classification of RCC and Frequency of Histologic Subtypes**

Malignant Neoplasms	Frequency (%)
Clear cell RCC	70–80
Papillary RCC	15
Chromophobe RCC	5
Collecting duct carcinoma	< 1
RCC unclassified	< 5

abdomen, and pelvis should be performed with computed tomography (CT) or a combination of CT, magnetic resonance imaging, or standard chest radiography. Laboratory biochemical evaluation includes a routine complete blood count and a complete metabolic panel specifically evaluating the serum creatinine, blood urea nitrogen, liver function tests, serum calcium, and alkaline phosphatase. If the patient complains of atypical musculoskeletal discomfort or if the biochemical studies indicate possible bone metastases, a bone scan should be considered. Presently, positron-emission tomography is not considered part of the staging workup for the newly diagnosed renal mass when other diagnostic studies reveal no evidence for systemic disease. The advances in imaging technology have dramatically enhanced the visualization of anatomic detail, especially vascular anatomy. Such detail is crucial for nephron-sparing cases and in situations of venous tumor thrombus. In many such instances, the need for invasive imaging with arteriography or venography has been obviated by the reconstructive capability of modern cross-sectional imaging.

### *Pathologic Characteristics and Potential Markers of Advanced Disease*

The World Health Organization modernized the classification of renal tumors (Table 1). Although clear cell RCCs account for 80% of primary malignant renal tumors, 90% of tumors that metastasize come from the conventional clear cell carcinoma, with 10% originating from other histologic subtypes including papillary and chromophobe carcinomas.<sup>13</sup> Several pathologic features including primary tumor grade, tumor size, pathologic T stage, histologic tumor necrosis, and lymph node status are all well-accepted, independent prognostic factors for predicting progression-free and overall survival (Table 2).<sup>1,2,14</sup> The Fuhrman system is the most common histologic kidney cancer grading system in North America. Grade I (well differentiated) to grade IV (poorly differentiated) patterns are assigned based on nuclear and nucleolar size, shape, and content.<sup>15</sup> Sarcomatoid tumors are no longer considered a distinct histologic subtype of RCC. They are uncommon (occurring in less than 5% of RCCs), high-grade, aggressive forms of RCC with spindle cell patterns of differentiation and are associated with a poor prognosis.<sup>16</sup> While it is difficult to determine the full impact of each inde-

pendent variable alone on progression and survival (particularly for conventional clear cell histology), the prognostic significance of each variable becomes much more powerful when incorporated into multivariate models of survival.<sup>1,2,14</sup> Five-year rates of progression-free survival and overall survival range from 13% to 99% and 20% to 91%, respectively (including N+ M0 cases), depending on the presence and combination of these variables.<sup>1,2</sup>

The natural history of sporadic RCCs cannot always be predicted based on conventional pathologic parameters and patient performance status. To date, there are no widely accepted kidney cancer biomarkers that would stratify patients into high-risk groups, although research is ongoing and many potential markers have been described.<sup>17</sup> Some of the more promising markers examined in RCC involve the molecular mechanisms associated with the hypoxia-inducible pathway, cellular proliferation, cell-cycle regulation, and cellular adhesion (Table 3). The hypoxia-inducible pathway appears to play an important role in angiogenesis, pH control, cellular proliferation, and apoptosis of common cancers and also may be important for tumor adaptation to hypoxic environments.<sup>18</sup>

Researchers from the National Institutes of Health characterized the loss of the short arm of chromosome 3 (-3p) as the locus of the von Hippel-Lindau (VHL) gene.<sup>19</sup> Approximately 50% of patients with sporadic kidney cancer exhibit VHL gene deletions, and an addi-

**Table 2. — Pathologic Risk Factors for RCC Progression and Survival**

<b>Lower Risk</b>
TNM
pT1a tumors (≤ 4 cm, confined to kidney)
pT1b tumors (> 4 cm, but ≤ 7 cm, confined to kidney)
pT2 tumors (> 7 cm, limited to kidney) with low-grade (I or II) features
Furhman grade I and grade II
Histology
Chromophobe renal carcinomas
<b>Higher Risk</b>
TNM
pT2 tumors (> 7 cm, limited to kidney) with high-grade (III or IV) features
pT3a tumors (extension through renal capsule into perinephric or perisinuous fat or adrenal, not beyond Gerota's fascia)
pT3b tumors (gross extension into renal vein or segmental branches, or extension into infradiaphragmatic IVC)
pT3c tumors (extension into supradiaphragmatic IVC, or IVC wall invasion)
pT4 tumors (extension beyond Gerota's capsule, adjacent organ involvement)
pT any N+ tumors
Furhman grade III and grade IV
Histology
Sarcomatoid differentiation
Collecting duct carcinomas
Tumor necrosis

**Table 3. — Potential Markers for RCC**

<b>Hypoxia-inducible pathway</b>
HIF-1 $\alpha$
VEGF
CAIX
<b>Cell-cycle regulation</b>
p53
PTEN
<b>Cellular proliferation</b>
Ki-67
<b>Cellular adhesion</b>
EpCAM
Cadherins
Catenins
<b>Miscellaneous</b>
Vimentin
Gelsolin
Adapted from Lam JS, Leppert JT, Figlin RA, et al. Role of molecular markers in the diagnosis and therapy of renal cell carcinoma. <i>Urology</i> . 2005;66:1-9. Reprinted with permission by Elsevier.

tional 25% of patients have VHL gene silencing by DNA methylation.<sup>20</sup> Both events involving the VHL gene appear to be more common in patients with LARCC.<sup>21</sup> A functional VHL gene regulates expression of several proteins including hypoxia-inducible factor-1 alpha (HIF-1 $\alpha$ ) and vascular endothelial growth factor (VEGF). Under normoxic conditions, hydroxylated forms of HIF-1 $\alpha$  are bound to the VHL gene, which leads to rapid degradation of the HIF-1 $\alpha$  protein. Many tumors including RCC adapt to a hypoxic environment, and under such circumstances, unhydroxylated forms of HIF-1 $\alpha$  do not bind to VHL genes and thus escape degradation. Hypoxia as well as VHL mutations, VHL deletions, and VHL gene silencing by DNA methylation all have the capability of upregulating HIF-1 $\alpha$  in patients with RCC, leading to intracellular accumulation of this biomarker. Upregulation of HIF-1 $\alpha$  also leads to upregulation of VEGF, an important factor for angiogenesis.<sup>17</sup>

Carbonic anhydrase IX (CAIX) is another promising biomarker described for RCC. VHL gene mutations and hypoxia induce the expression of CAIX, which is a cancer-associated transmembrane enzyme that catalyzes the interconversion between carbon dioxide and bicarbonate and serves to regulate intracellular and extracellular pH during periods of hypoxia in tumor cells. CAIX is thought to play a role in regulating cellular proliferation and possibly cellular adhesion via the cadherin and catenin families of adhesion molecules.<sup>22</sup> CAIX is a tumor-associated antigen homologous to the G250 antigen found on chromosome 9p12-9p13. G250 monoclonal antibodies have been developed for adjuvant therapy trials and for trials in patients with metastatic disease.<sup>23</sup> CAIX is selectively expressed in greater than 80% to 90% of primary and metastatic RCCs, whereas little to no expression is detected in normal renal tissue.<sup>24-26</sup> Bui et al<sup>25</sup> found that decreased expression of CAIX resulted in a worse prognosis for

patients with metastatic clear cell RCC. This same group of researchers later reported that CAIX and Ki-67 on multivariate analysis were independent significant predictors of survival.<sup>27</sup> Ki-67 is a ubiquitous nuclear antigen in all cycling human cells and is a marker for cellular proliferation. Increased Ki-67 expression has been correlated with more aggressive cancers and has been described as a prognostic indicator of high-risk features in RCC.<sup>27-31</sup>

Advances in tissue microarray technologies have accelerated the identification of other potential prognostic biomarkers including gelsolin (an actin binding protein),<sup>31</sup> vimentin (an intermediate filament protein),<sup>32</sup> and p53.<sup>33</sup> Other potential prognostic markers include cellular adhesion molecules from the cadherin and integrin families, most notably cadherin-6,<sup>34</sup> E-cadherin,<sup>35</sup> N-cadherin, and various alpha-integrins.<sup>36</sup> Catenins are cytoplasmic proteins that modulate cadherin function and link cadherins to the cellular cytoskeleton. Decreased catenin expression might further destabilize cellular adhesion.<sup>26</sup>

Combining molecular markers with established clinical predictors of prognosis in patients with LARCC and metastatic RCC to predict disease-specific survival has been accomplished in nomogram format.<sup>17</sup> Such molecular profiling will facilitate the ability to accurately predict patients destined to experience disease recurrence and allow physicians to better target patients for adjuvant trials.

## Clinical Series of LARCC

Frank and associates<sup>14</sup> reported on 1,801 patients with unilateral clear cell RCC treated with radical nephrectomy from 1970 to 1998. The mean follow-up in this patient series was 9.7 years. The average patient age was 62.5 years (range 24–89 years) and the average size of the tumor was 7.3 cm (range 0.8–24 cm). Sixty-four percent of patients were men, 58% had a smoking history, 5.3% had recent onset of hypertension, and 72.4% were symptomatic at presentation. The estimated 1-, 3-, 5-, 7-, and 10-year cancer specific survival rates for all patients combined were 86.6%, 74%, 68.7%, 63.8%, and 60%, respectively. The average time from radical nephrectomy to death from clear cell RCC was 3.2 years (median 1.7 years, range 0–26 years). The authors concluded that the TNM stage, tumor size, grade, and histologic tumor necrosis were significantly associated with cancer-specific survival and designed a scoring system (SSIGN: stage, size, grade, necrosis) based on these features that can be used to predict outcome.

Recently, Kim and colleagues<sup>37</sup> reported on 1,191 patients treated for RCC between 1989 and 2001. A total of 226 patients (19%) had clinically localized RCC (N0 M0) and underwent a nephrectomy and tumor

thrombectomy. Of the 1,191 patients, 117 (10%) had renal vein only involvement, 109 (9%) had involvement of the inferior vena cava (IVC), and 207 (17%) had only invasion of the perinephric fat (T3a) without thrombus. This cohort of 226 patients with tumor thrombus was compared to 654 patients (N0 M0) without tumor thrombus who underwent nephrectomy alone. In a univariate analysis, venous thrombus was a significant predictor for recurrence (hazard ratio 2.16,  $P < .001$ ). However, venous involvement was not a predictor for recurrence in a multivariate analysis controlling for Fuhrman grade, pT stage, and Eastern Cooperative Oncology Group (ECOG) performance status. A comparison of the risk of recurrence based on level of venous involvement (renal vein thrombus, IVC thrombus below the diaphragm, IVC thrombus above the diaphragm) did not reveal a significant difference. In patients with localized RCC, disease-specific survival (DSS) was similar for patients with extracapsular (pT3a), renal vein (T3b), and IVC involvement below the diaphragm (T3b) ( $P = .536$ ). DSS rates for T3b and T2 were significantly different ( $P = .017$ ), and DSS rates for IVC thrombus below the diaphragm (T3b) and venous thrombus above the diaphragm (T3c) were significantly different ( $P = .009$ ). Patients with T3c IVC involvement had a significantly worse survival rate even after controlling for Fuhrman grade and ECOG performance status in a multivariate analysis ( $P = .020$ ). For patients with metastatic RCC, the overall 2-year DSS rate was 43%. Venous involvement, regardless of the level of the thrombus, did not significantly affect DSS ( $P = .834$ ) in patients with metastatic disease. A separate report from the same institution revealed that most patients with tumor thrombus presented with advanced stages of cancer. Sixty-three percent of patients with venous involvement presented with metastases to regional lymph nodes or distant sites. In N0 M0 cases with IVC tumor thrombus, capsular penetration, collecting system invasion, and extension into the hepatic veins were more important prognostic variables than the level of IVC thrombus.<sup>38</sup>

The importance of primary tumor histology on the presence of renal vein and IVC tumor thrombus extension was reported by Rabbani and colleagues<sup>39</sup> in a study of 1,082 patients with nonmetastatic RCC or oncocytoma. Renal vein extension was present in 60 patients (5.4%) and IVC extension was present in 31 (2.8%) (subhepatic in 25, suprahepatic in 5, and intra-atrial in 1). The histologic type associated with an increased risk of renal vein/IVC extension was conventional clear cell RCC (80 of 702 cases,  $P < .0001$ ), and histologic types associated with a decreased risk were oncocytoma (0 of 117 cases,  $P < .0001$ ) and papillary histology (0 of 146,  $P < .0001$ ). Chromophobe, collecting duct, unclassified, and mixed histologies were demonstrated in 117 patients and accounted for 11

**Table 4. — Five-Year Disease-Specific Survival (DSS) for Patients With RCC and IVC Tumor Thrombus**

Study	Year	No. of Patients	5-Year DSS (%)	
			M(-)	M(+)
Skinner et al <sup>46</sup>	1989	56	47	0
Novick et al <sup>47*</sup>	1990	43	64	11
Thrasher and Paulson <sup>48</sup>	1993	44	69	0
Swierzewski et al <sup>49</sup>	1994	100	64	20
Zisman et al <sup>38**</sup>	2003	207	72	41
Parekh et al <sup>50</sup>	2005	49	42	20

M = metastases  
 \* 3-year DDS reported  
 \*\* 5-year DSS for M(-) patients, 2-year DSS for M(+) patients

cases of renal vein (8) and IVC (3) tumor thrombus. They concluded that renal vein or IVC extension alone did not impart a worse prognosis independent of tumor size, nodal status, and histology.<sup>39</sup>

In most studies, the presence of lymph node or distant metastases reflects an inferior prognosis that is not appreciably altered by radical surgery. However, there may be a therapeutic role for surgery in some patients with metastases as well as a palliative role for patients who experience severe disability from intractable edema, ascites, cardiac dysfunction, or associated local symptoms such as abdominal pain or hematuria. Recently, Naitoh and associates<sup>40</sup> identified 31 patients with metastatic RCC whose primary tumor extended into the IVC. At a mean follow-up of 18 months, 26% of the patients were alive. The overall 5-year survival rate of the group was 17%. Tumor thrombus level did not correlate with survival. In patients with isolated pulmonary metastases, the 5-year survival rate was 43%, while it was 52% in those with low-grade tumors. In contrast to poorer results of surgery only in patients with RCC and concurrent IVC tumor thrombus, reasonable 5-year survival may be achieved after combined aggressive surgery and immunotherapy. Patients in whom diagnosis was limited to lungs and those with grade 1 to 2 tumors had improved outcomes.<sup>40</sup>

## Surgery and Surgical Adjuncts for LARCC

### Renal Vein and Inferior Vena Cava Tumor Thrombus

Historically, LARCC with IVC tumor thrombus was uniformly lethal, with a 5-year survival rate of only 15% in patients who underwent radical nephrectomy for clinically localized tumors.<sup>41-43</sup> However, improvements in perioperative monitoring, intraoperative management, and vascular bypass techniques have allowed progressively more difficult thrombus cases to be managed with lower complication rates.<sup>44,45</sup> Furthermore, it has been demonstrated that patients with venous tumor thrombus but without nodal or distant metastases have good oncologic outcomes and therefore merit aggressive surgical treatment (Table 4).<sup>38,46-50</sup> The feasibility of venous tumor thrombectomy for RCC arising in a solitary kidney has also been demonstrated.<sup>51,52</sup>

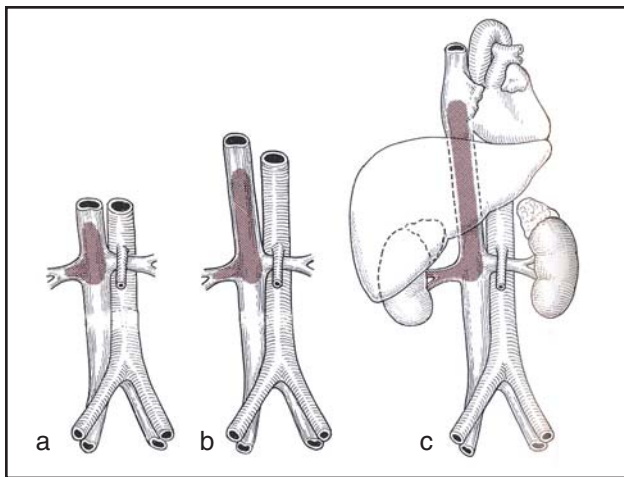
The surgical approach for patients with tumor thrombus depends on the level of the thrombus (Table 5). Patients with supradiaphragmatic tumor thrombus present greater technical challenges for the surgical team. Thus, it is imperative to determine and classify how much of the IVC is involved by thrombus. Pritchett et al<sup>53</sup> identified three groups: subhepatic thrombus, thrombus extending into the intrahepatic or retrohepatic vena cava below the diaphragm, and supradiaphragmatic thrombus (Figure).

Traditionally, a right thoracoabdominal incision was the incision of choice. Thereafter, surgeons discovered the advantages of a chevron incision with or without a midline abdominal cephalad T extension and liver mobilization via the Lagenbuch maneuver when the thrombus is infradiaphragmatic and when exposure of the retrohepatic vena cava is necessary.<sup>54</sup> Abdominal incisions and liver mobilization allow for earlier recovery, cause less pain, and eliminate the need for thoracic drains. If the tumor thrombus extends above the diaphragm, a thoracoabdominal incision or a midline sternotomy combined with an abdominal incision may be required.

**Table 5. — Level of IVC Tumor Thrombus and Surgical Approach**

Thrombus Level	Incision Type	Technique	CPB or Venovenous Bypass
Infrahepatic	subcostal midline chevron chevron + xiphisternal	IVC isolation thrombectomy	no
Intrahepatic	chevron chevron + xiphisternal midline thoracoabdominal	IVC isolation control hepatic veins Pringle maneuver thrombectomy	usually no
Supradiaphragmatic	sternotomy + abdominal chevron + xiphisternal thoracoabdominal	IVC isolation control hepatic veins Pringle maneuver thrombectomy milk/extract tumor from atrium	usually yes

CPB = cardiopulmonary bypass



Level of IVC thrombus (a = infrahepatic, b = intrahepatic or retrohepatic, c = suprahepatic). From Dubernard J-M, Abbou C, eds. *Chirurgie Urologique*. Paris, France: Masson SA; 2001. Reprinted with permission from Elsevier.

Other advancements in surgical techniques have been described for managing IVC tumor thrombus following reports of improved patient survival after aggressive surgical resection of these tumors.<sup>55</sup> Cardiopulmonary bypass has been utilized as an adjunct to removing cavoatrial tumor thrombus with<sup>56,57</sup> and without<sup>58,59</sup> hypothermic circulatory arrest. The advantages of bypass and circulatory arrest include careful, controlled dissection in essentially bloodless surgical fields. However, there are associated risks of solid organ ischemia, neurologic sequelae, and coagulopathy with these techniques. For tumors with minimal thrombus in the supradiaphragmatic location or just below the diaphragm, venovenous bypass via a shunt created between the femoral or saphenous vein to the axillary vein can be a useful technique to allow the surgical team to avoid cardiopulmonary bypass. This technique can decrease perioperative morbidity and, in some instances, enable hepatic decompression with a reversed portal shunt. When control of the vena cava needs to be established above the hepatic veins, the Pringle maneuver can be utilized. The liver can usually tolerate 30 to 45 minutes of warm ischemia. This amount of time should be adequate for cavotomy, tumor thrombus extraction, and caval repair below the level of the hepatic veins where vascular control can be re-established. Other useful intraoperative techniques for caval thrombus include hypotensive anesthesia with vasodilation and colloid administration<sup>60</sup> and transesophageal echocardiography, which provides real-time diagnostic capabilities to determine the presence of thrombus and to monitor the extent of the thrombus within the cava or within the atrial chamber.<sup>61</sup>

### Inferior Vena Cava Invasion

Few renal tumors extend into the IVC, and it is uncommon for the tumor thrombus to invade the wall of the

IVC. It is reported that when the IVC is chronically obstructed by a tumor thrombus, caval resection produces minimal postoperative morbidity.<sup>62</sup> If collateral circulation is not present, resecting the IVC can be associated with severe edema of the lower extremities.<sup>63</sup> In this setting, reconstructing the IVC should be considered and can be done with a polytetrafluoroethylene graft, but the main concern with prosthetic grafts for vein replacement is their tendency to thrombose or become infected, and therefore autologous vein graft and pericardium are the preferred graft materials.<sup>64,65</sup> When the tumor thrombus is extensively invading or is densely adherent to the cava, or when there is an IVC filter that cannot be safely removed, caval resection with no replacement seems to be a reasonable approach.<sup>66</sup>

### Regional Lymph Node Dissection

The exact role of lymphadenectomy in the surgical treatment of RCC remains controversial. A description of radical nephrectomy by Robson et al<sup>67</sup> included a dissection of the para-aortic and paracaval lymph nodes from the bifurcation of the aorta to the crus of the diaphragm as a necessary component of a radical nephrectomy. They suggested that the improved survival of patients undergoing radical nephrectomy was due in part to the retroperitoneal lymph node dissection. In this classic report written before adequate preoperative imaging, 22.7% of patients undergoing radical nephrectomy had positive lymph nodes, and yet survival was equivalent to that in patients with renal vein involvement only. In a randomized, controlled trial conducted by the European Organization for Research and Treatment of Cancer Genitourinary Tract Cancer Group, the prevalence of lymph nodes involved by tumor was low, reflecting the preponderance of low-risk disease.<sup>68</sup> This is similar to reports of single-institution experiences, although specific subgroups can be identified that have a higher risk of nodal involvement.<sup>69,70</sup> Although lymphadenectomy adds minimal morbidity to nephrectomy for clinically localized RCC, to date a benefit in terms of oncologic outcomes has not been demonstrated when a routine lymphadenectomy has been performed.<sup>68</sup>

The published literature is scant and contradictory in its conclusions regarding the benefits of lymphadenectomy. Some reports promote the value of a lymphadenectomy, while other surgical series fail to show any conclusive benefit.<sup>68,71</sup> Positive lymph nodes are commonly associated with metastatic disease, yet data to support a lymph node dissection in patients with known distant metastases are limited.<sup>72</sup> Whether “debulking” the retroperitoneum adds any survival advantage different from nephrectomy alone in patients with clinical metastases remains to be determined.<sup>4,5</sup> Johnsen and Hellsten<sup>73</sup> studied 554 cases of RCC diagnosed at autopsy. Only 5 patients had lymph

node metastases confined to the retroperitoneum. Theoretically, less than 1% of patients (5 of 554) might have been cured by nephrectomy and lymph node dissection alone.

Minervini et al<sup>71</sup> evaluated a series of 167 patients, including 108 who were treated with nephrectomy only and 59 who underwent nephrectomy with regional lymph node dissection limited to the anterior, posterior, and lateral sides of the ipsilateral great vessel from the level of the renal vessels down to the inferior mesenteric artery. The 5-year survival rate for the 108 patients who underwent nephrectomy alone was 79%, while for those who also underwent lymph node dissection the rate was 78%, suggesting no clinical benefit.<sup>71</sup>

In the only randomized phase III trial to address the benefits of lymph node dissection during radical nephrectomy for patients with resectable nonmetastatic RCC, the incidence of unsuspected lymph nodes after proper preoperative staging was only 3.3%, and complication rates were similar between the two groups.<sup>68</sup>

Pantuck et al<sup>74</sup> recently reported retrospective data regarding the outcome for patients undergoing lymph node dissection for RCC. Despite the addition of no significant morbidity in patients undergoing lymphadenectomy, those with clinically negative lymph nodes experienced no measurable overall or recurrence-free survival benefit. Furthermore, in this series of 900 patients, the incidence of regional nodal metastases in the absence of distant disease was less than 5% (43 of 900 cases). It is likely that many of these patients were identified preoperatively by computed tomography scans or intraoperatively by surgical exploration. In the remainder in whom disease is unrecognized, it is just as likely that lymph nodes may be found in the perirenal fat and surrounding the pedicle as along the great vessels. Less than 8% of node positive cases in this study were discovered incidentally in the sense that nodes were found in the pathologic specimen without a clinical impression of nodal involvement. Clearly, the majority of node-positive cases are identified prior to lymph node dissection.

A more recent experience presented by investigators at the National Cancer Institute described 154 patients with metastatic RCC who underwent cytoreductive nephrectomy prior to systemic therapy.<sup>72</sup> They found an 8.5-month median survival in patients with positive nodes, which was inferior to the 15-month median survival in patients without node-positive disease. Furthermore, median survival in patients with a complete lymphadenectomy (8.6 months) was identical to survival in those with an incomplete resection (8.5 months). Survival was poor for patients determined to be unresectable at the time of surgery (3.3 months).

Canfield and colleagues<sup>75</sup> evaluated a series of 54 patients with clinical N+ M0 disease and concluded that these patients should be targeted for aggressive

surgical resection, followed by clinical trials of adjuvant therapy to improve outcome. These recommendations were based on an extended median overall survival of 20.3 months for patients with node-positive disease in the absence of distant metastases. Patients with only 1 positive lymph node survived significantly longer than patients with greater than 1 positive lymph node (median 35.7 vs 14.5 months). Recurrences appeared rapidly (median 4.9 months), supporting the need for an effective adjuvant therapy. This helps to define the value of a lymphadenectomy as a therapeutic procedure in patients with clinical node-positive disease, although a true survival benefit cannot be confirmed in the absence of a prospective, randomized trial.

In patients with no distant metastases, the incidence of regional lymph node-positive disease is low.<sup>68,73,74</sup> Available survival data do not support performing a routine lymphadenectomy in patients with no clinical or radiographic evidence of nodal involvement.<sup>76</sup> In patients with clinically positive regional lymph nodes and no evidence for distant metastases, a lymph node dissection theoretically could render a patient without evidence for residual disease and should be considered in carefully selected patients. As the experience with newer targeted therapies becomes more readily available, patients with completely resected node-positive disease and no evidence for distant metastases could be considered for adjuvant therapy trials.

### **LARCC With Adjacent Organ Involvement**

Few patients present with adjacent organ involvement from direct tumor extension (T4). Such patients present with pain, generally from invasion of the posterior abdominal wall, nerve roots, and paraspinous muscles. Liver extension is uncommon, and intrahepatic metastases occur more often than local extension. The capsules of large tumors may indent and compress adjacent organ parenchyma but seldom actually grow by direct extension into the liver or spleen. Duodenal and pancreatic invasion is uncommon, but when present, it heralds a poor prognosis. The propensity for tumors to parasitize vessels may account for extension into the large bowel, mesentery, and colon.

Because surgical therapy is the only effective management for this type of tumor, extended operations are sometimes indicated. Complete excision of the tumor, including excision of the involved bowel, spleen, or abdominal wall muscles, is the aim of therapy. En bloc partial hepatectomy is rarely curative but occasionally can be worthwhile. Partial excision of the large primary tumor, or debulking, is rarely indicated. In one study, only 12% of patients who underwent incomplete excision of locally extensive tumor were alive at 1 year.<sup>77</sup> Most reports suggest that less than 5% of patients with extension into adjacent viscera survive 5 years after surgery.

### Early Renal Artery Ligation vs Embolization

Significant bleeding during radical nephrectomy can occur for several reasons. The kidney is extremely vascular and when tumor is present, neovasculature can augment the baseline vascularity, and engorged veins readily bleed. In addition, exposure and ligation of the renal hilum and particularly the renal arterial blood supply can be impeded by vascular collateralization, retroperitoneal lymphadenopathy, and large kidney tumors. Although the potential for blood loss seems more common in patients with an IVC thrombus, patients with large hypervascular tumors with no IVC extension share similar clinical characteristics in terms of neovasculature, venous engorgement, and difficult exposure of the renal hilum.

Transcatheter arterial embolization (TAE) of the renal blood supply is a method for collapsing the collateral circulation and has been utilized for therapeutic and palliative purposes in the management of LARCC.<sup>78</sup> TAE has been advocated for some patients with LARCC prior to undergoing radical nephrectomy. In fact, Zielinski and associates<sup>79</sup> reported overall 5- and 10-year survival rates of 62% and 47%, respectively, for 118 patients embolized before nephrectomy compared with 35% and 23%, respectively, for the matched group of 116 patients treated with surgery alone ( $P = .01$ ). Reasons for the survival advantage in the group of patients managed with preoperative embolization from this nonrandomized study are not clearly understood, and the results have not been confirmed in larger prospective randomized trials. Regardless, there continues to be debate on the advantages of preoperative embolization of the renal artery to facilitate surgery. The rationale for embolization includes decreasing the size of the primary tumor, decreasing the size and the extent of a tumor thrombus, and decreasing the number and extent of venous collaterals. Potentially, TAE leads to increased edema within tissue planes, thereby facilitating surgical dissection, and TAE allows for arterial control when dissection of the renal hilum is compromised by the previously mentioned clinical characteristics of tumors in some patients with LARCC.

Preoperative embolization is not without risks, including a systemic reaction to embolization consisting of pain, fever, and leukocytosis, embolization of organs other than the target organ (eg, bowel, spinal cord, or the contralateral kidney), and tumor embolization from the devascularized IVC thrombus.<sup>80-82</sup> Tubular necrosis, renal abscess, and altered blood pressure have also been reported.<sup>83</sup> In addition, a significant period of time may be required to achieve any measurable retraction of the tumor thrombus to a more favorable location within the IVC prior to surgery. For these reasons, early ligation of the renal artery appears to be the preferred method for most surgeons caring for patients with LARCC undergoing nephrectomy.<sup>84</sup>

### Adjuvant Therapies for LARCC

The postoperative period following nephrectomy is the ideal setting for adjuvant therapy since the macroscopic tumor burden is minimized and also the immunodysfunction attributed to the in situ primary tumor is alleviated. For an adjuvant therapy to be widely accepted, it must be efficacious and well tolerated, with few local or systemic side effects. Adjuvant therapies have been more widely explored in various other cancers including breast, lung, and colon. Accrual of patients to large randomized trials has been difficult due to the relative infrequency of patients with LARCC compared with other malignancies. To date, the success of adjuvant therapy for RCC in terms of trial experience as well as clinical outcome has been disappointing.

### Radiation, Hormonal Agents, Chemotherapy, and Inhibitors of Angiogenesis

Initial results with adjuvant radiation seemed favorable in terms of decreasing local recurrence rates.<sup>85</sup> However, longer follow-up as well as other randomized, prospective studies of adjuvant radiation compared to observation following nephrectomy for LARCC revealed no differences in survival and possibly significant added morbidity to abdominal organs.<sup>86,87</sup> Likewise, a randomized, prospective trial of adjuvant medroxyprogesterone acetate compared to observation for patients following nephrectomy revealed similar relapse rates of 33% and 34%, respectively, after a median follow-up of 5 years.<sup>88</sup> The cumulative objective response rate for cytotoxic chemotherapy in the metastatic setting was 6%, and individual trial response rates rarely exceeded 10%.<sup>89,90</sup> The poor response rate for most chemotherapy regimens has been attributed to P-glycoprotein, which is a product of the multidrug-resistance gene (MDR1) uniformly expressed in RCCs and which functions as an energy-dependent drug efflux pump.<sup>91</sup> Chemotherapy-related toxicity and, more importantly, limited efficacy of chemotherapies for RCC dampens the enthusiasm for these drugs as options for adjuvant treatment.

Theoretically, angiogenesis inhibitors should have measurable effects in patients with kidney cancer because most patients with clear cell RCC have a mutation in the VHL gene that stabilizes VEGF.<sup>92</sup> A consequence of the loss of the VHL gene is upregulation of VEGF via a pathway involving accumulation of hypoxia-inducible factor. VEGF is a potent angiogenic factor and is secreted by many human cancers, but clear cell RCC as a group produces particularly high levels. Several antiangiogenics have been studied in the metastatic setting with limited to modest response.<sup>93-95</sup> Presently, angiogenesis inhibitors have an undefined role in the adjuvant setting.



## Immunotherapy

Patients with RCC may be immunocompromised at the time of diagnosis. Evidence from animal studies suggests that the primary tumor acts as an immunologic sink that results in the suppression of cell-mediated immunity.<sup>96,97</sup> T cells appear to be more sensitive to tumor-induced apoptosis, and they have impaired interleukin 2 (IL-2) production and IL-2 receptor signaling.<sup>98</sup> Furthermore, defective tumor antigen presentation and recognition might contribute to tumor progression and compromised survival. Nephrectomy can reverse some of the immune suppression as evidenced by rare cases of spontaneous metastatic tumor regression following primary surgery. Exogenously administered cytokines might augment tumor-specific immune responses and have been the basis for the treatment of patients with metastatic RCC.

Two cytokines that have been extensively studied and which are currently available for patients with RCC include IL-2 and interferon (IFN). Response rates to IL-2 and IFN for patients with metastatic RCC range from 15% to 20%.<sup>90,99,100</sup> Four recently conducted randomized, prospective trials of patients at high risk for cancer recurrence addressed the role of adjuvant immunotherapy compared to observation following nephrectomy.<sup>101-104</sup> Two of the trials employed different regimens of adjuvant IFN- $\alpha$ , and another smaller trial assessed high-dose bolus IL-2. The fourth trial incorporated a combination of outpatient IL-2, outpatient IFN- $\alpha$ 2a, and intravenous 5-fluorouracil in the treatment arm compared to observation. None of the four prospective studies demonstrated improved disease-free survival or improved overall survival with adjuvant cytokine therapy compared to observation following nephrectomy. Toxicity with adjuvant immunotherapy was substantial. In two of the trials, there was a trend towards improved survival in the observation arms of the studies.<sup>101,104</sup>

## Cell-Based Therapies and Vaccine Therapies

Many cell-based adoptive immunotherapy regimens have been evaluated in patients with metastatic RCC including lymphokine-activated killer (LAK) cells, tumor-infiltrating lymphocytes (TILs), and autolymphocyte therapies. These therapies are usually administered together with IL-2, but the results have been no more favorable compared to IL-2 therapy alone.<sup>98</sup> Only one small study revealed a significant difference in progression-free survival for patients who received adjuvant adoptive immunotherapy following nephrectomy. These patients were treated with autologous lymphocytes activated *ex vivo* by anti-CD3 monoclonal antibody and autologous cytokines.<sup>105</sup> Prospective, randomized studies will be required to determine whether

cell-based therapies have a definitive role as an adjunct to nephrectomy in the locally advanced setting.

A poor response to immunotherapy could be associated with faulty presentation or recognition of tumor antigens. Cancer cells have unique tumor-specific antigens, such as the G250 antigen, that are not typically expressed on the cell surface of normal renal tissue. T lymphocytes are the effector cells of the immune system and recognize antigen through the T-cell receptor (TCR)-CD3 complex. The binding of the TCR-CD3 complex to the tumor antigen/major histocompatibility complex (MHC) expressed on the cell surface of antigen-presenting cells such as macrophages and dendritic cells is necessary for T-cell function. Appropriate T-cell function results in tumor-cell lysis, T-cell proliferation, and cytokine secretion. Impaired T-cell function may impart a higher risk of cancer progression.

Vaccine-based strategies are on the forefront of therapies for locally advanced kidney cancers. The biological goal of vaccine therapy is to bypass the indirect stimulation of the immune system and instead generate tumor-specific B cells and natural killer cells, as well as cytotoxic T lymphocytes and T-helper cells that recognize specific immunoreactive tumor antigen targets in context with the MHC complex of antigen-presenting cells. Many approaches have been used to generate tumor-specific vaccines.<sup>98</sup> Most of these strategies have been evaluated in patients with metastatic disease. However, several vaccine constructs are being evaluated as adjuvant therapies.

One prospective, randomized study evaluated 120 patients who received either autologous irradiated tumor cells admixed with bacillus Calmette-Guérin or who were observed after nephrectomy for RCC (pT1-3b, N0 or N+). The median follow-up was 61 months, and there was no significant difference in 5-year disease-free survival rates (63% for the vaccine group vs 72% for observed patients) or 5-year overall survival rates (69% vs 78%, respectively).<sup>106</sup> Schwab and associates<sup>107</sup> reported the effects of an adjuvant vaccine consisting of irradiated autologous tumor cells admixed with human recombinant granulocyte macrophage-colony stimulating factor (GM-CSF) administered to a small number of patients with nonmetastatic RCC. Patient numbers were too small to draw conclusions regarding cancer progression or survival. However, there was a significant increase in peripheral blood CD4 and CD8 T-cell precursors measured on the conclusion of therapy compared to levels detected 2 weeks prior to the start of vaccine therapy.

Tumor lysate has been used as an adjuvant vaccine in a randomized, prospective phase III trial for patients with pT2-3b pN0-3 M0 RCC according to the 1993 UICC classification system.<sup>108</sup> In this study, RCC cells were harvested following nephrectomy and were incubated with IFN prior to cell devitalization to improve

the antigenicity of the cells. Only 4% of the patients had regional node-positive disease, and only 1% of the patients experienced vaccine-related toxicity. Following nephrectomy, many patients were lost after randomization (174 of 553 patients, 32%), including 99 patients who were randomized to the vaccine arm of the study. Although the imbalance of the loss creates postrandomization bias, the results of the trial were nevertheless impressive. At 70 months of follow-up, the hazard ratio for tumor progression was 1.59 (1.07-2.36) in favor of the vaccine group ( $P = .0204$ , log-rank test), and the 70-month progression-free survival rate was 72% in the vaccine group and 59.3% in the control group. A subset analysis found no significant difference in the 5-year progression-free survival for patients with pT2 tumors. However, patients in the vaccine group with pT3 disease experienced nearly an 18% improvement in 5-year progression-free survival. Although overall survival was not an endpoint for the trial, the results are encouraging and provide a concrete step towards implementing an effective adjuvant therapy for patients with RCC.<sup>108</sup>

An ongoing multicenter randomized phase III trial for patients with a high risk of recurrence following nephrectomy for RCC<sup>109</sup> is investigating the use of heat-shock protein peptide-complex 96 (HSPPC-96; Antigenics Inc, New York, NY) as an autologous vaccine compared to observation. HSPPC-96 has shown some efficacy in patients with metastatic RCC.<sup>110</sup> Animal studies suggest that HSPs may have a greater benefit in an adjuvant setting.<sup>111</sup> HSPs are highly conserved proteins that chaperone vital peptides through various intracellular compartments without being degraded. The combination of HSPs and their "protected" peptides are highly immunogenic and have been noted to activate CD8 and CD4 lymphocytes, activate natural killer cells, induce cytokine secretion, and stimulate dendritic cell maturation.<sup>111</sup>

### Targeted Therapies

G250 is a tumor-associated antigen homologous to CAIX that is found in greater than 90% of clear cell RCCs but is absent on normal renal tissue. WX-G250 (cG250, Rencarex) is a chimeric IgG1 antibody that binds to CAIX. WX-G250 has demonstrated activity in metastatic RCC as a single-agent therapy and when combined with other biological response modifiers such as IL-2. Interest in cG250 as an adjuvant therapy for LARCC is based not only on the response rates in patients with metastatic RCC ranging from 25% to 42%, but also on its favorable toxicity profile.<sup>112</sup> The ARISER trial (Adjuvant Rencarex Immunotherapy Phase III Trial to Study Efficacy in Nonmetastatic Renal Cell Carcinoma) is an ongoing phase III randomized, double-blind, placebo-controlled trial for patients with ECOG performance status of 0 with completely resected primary

clear cell RCC and no evidence of remaining local or distant disease.

The US Food and Drug Administration recently approved two oral multi-kinase inhibitors that target several receptor tyrosine kinases including VEGF receptor and platelet-derived growth factor receptor. Both sunitinib (Sutent) and sorafenib (Nexavar) have demonstrated significant activity in pretreated metastatic RCC patients.<sup>113,114</sup> Toxicity of both agents appears acceptable in the metastatic setting. As clinical experience evolves with these targeted therapies, adjuvant therapy trials will most certainly be accomplished and thus may extend progression-free survival and overall survival for patients with locally advanced nonmetastatic disease.

## Conclusions

There have been significant advances in the perioperative and intraoperative management of patients with LARCC, particularly in the evaluation and treatment of patients with IVC tumor thrombus. Patients with LARCC have an elevated risk for disease recurrence, and complete resection of the primary tumor is critical for long-term survival. Nevertheless, traditional clinical and pathologic characteristics of patients' primary tumors do not always predict the biological behavior of their malignancies or their expected disease-specific survival. The last few years have witnessed a tremendous surge in the identification of molecular markers (eg, CAIX, vimentin, p53, gelsolin, Ki-67, HIF-1 $\alpha$ , VEGF) that can be incorporated into models alongside pTNM stage, ECOG status, Fuhrman grade, and tumor necrosis, to enhance our ability to target patients at risk for disease recurrence. Randomized trials of adjuvant radiation, hormonal therapy and, more recently, immunotherapy have shown no clinical benefit. Autologous tumor vaccines may decrease recurrence rates for patients with LARCC, but additional prospective, randomized studies need to be undertaken. The results of two ongoing adjuvant therapy trials (HSPPC-96 and WX-G250) are eagerly awaited. Future treatment strategies for patients with LARCC will likely incorporate aggressive surgical resection followed by combinations of therapies to include cytokines, vaccines, inhibitors of angiogenesis, and possibly some of the newer small molecule-targeted therapies currently being evaluated in patients with metastatic RCC.

## References

1. Zisman A, Pantuck AJ, Wieder J, et al. Risk group assessment and clinical outcome algorithm to predict the natural history of patients with surgically resected renal cell carcinoma. *J Clin Oncol*. 2002;20:4559-4566.
2. Leibovich BC, Blute ML, Cheville JC, et al. Prediction of progression after radical nephrectomy for patients with clear cell renal cell carcinoma. *Cancer*. 2003;97:1663-1671.
3. Cheville JC, Blute ML, Zincke H, et al. Stage pT1 conventional (clear cell) renal cell carcinoma: pathological features associated with cancer specific survival. *J Urol*. 2001;166:453-456.
4. Flanigan RC, Salmon SE, Blumenstein BA, et al. Nephrectomy fol-

- lowed by interferon alfa-2b compared with interferon alfa-2b alone for metastatic renal-cell cancer. *N Engl J Med.* 2001;345:1655-1659.
5. Mickisch GH, Garin A, van Poppel H, et al. European Organization for Research and Treatment of Cancer (EORTC) Genitourinary Group. Radical nephrectomy plus interferon-alfa-based immunotherapy compared with interferon alfa alone in metastatic renal-cell carcinoma: a randomised trial. *Lancet.* 2001;358:966-970.
  6. Motzer RJ, Mazumdar M, Bacik J, et al. Survival and prognostic stratification of 670 patients with advanced renal cell carcinoma. *J Clin Oncol.* 1999;17:2530-2540.
  7. Jayson M, Sanders H. Increased incidence of serendipitously discovered renal cell carcinoma. *Urology.* 1998;51:203-205.
  8. Bosniak MA. The current radiological approach to renal cysts. *Radiology.* 1986;158:1-10.
  9. Dechet CB, Sebo T, Farrow G, et al. Prospective analysis of intraoperative frozen needle biopsy of solid renal masses in adults. *J Urol.* 1999;162:1282-1284.
  10. Dechet CB, Zincke H, Sebo TJ, et al. Prospective analysis of computerized tomography and needle biopsy with permanent sectioning to determine the nature of solid renal masses in adults. *J Urol.* 2003;169:71-74.
  11. Sanchez-Ortiz RF, Madsen LT, Bermejo CE, et al. A renal mass in the setting of a nonrenal malignancy: when is a renal tumor biopsy appropriate? *Cancer.* 2004;101:2195-2201.
  12. Fernandez-Acenero MJ, Galindo M, Bengoechea O, et al. Primary malignant lymphoma of the kidney: case report and literature review. *Gen Diagn Pathol.* 1998;143:317-320.
  13. Motzer RJ, Bacik J, Mariani T, et al. Treatment outcome and survival associated with metastatic renal cell carcinoma of non-clear-cell histology. *J Clin Oncol.* 2002;20:2376-2381.
  14. Frank I, Blute ML, Cheville JC, et al. An outcome prediction model for patients with clear cell renal cell carcinoma treated with radical nephrectomy based, on tumor stage, size, grade and necrosis: the SSIGN score. *J Urol.* 2002;168:2395-2400.
  15. Fuhrman SA, Lasky LC, Limas C. Prognostic significance of morphologic parameters in renal cell carcinoma. *Am J Surg Pathol.* 1982;6:655-663.
  16. Mian BM, Bhadkamkar N, Slaton JW, et al. Prognostic factors and survival of patients with sarcomatoid renal cell carcinoma. *J Urol.* 2002;167:65-70.
  17. Lam JS, Leppert JT, Figlin RA, et al. Role of molecular markers in the diagnosis and therapy of renal cell carcinoma. *Urology.* 2005;66(5 suppl):1-9.
  18. Harris AL. Hypoxia: a key regulatory factor in tumour growth. *Nat Rev Cancer.* 2002;2:38-47.
  19. Zbar B, Brauch H, Talmadge C, et al. Loss of alleles of loci on the short arm of chromosome 3 in renal cell carcinoma. *Nature.* 1987;327:721-724.
  20. Iliopoulos O, Eng C. Genetic and clinical aspects of familial renal neoplasms. *Semin Oncol.* 2000;27:138-149.
  21. Brauch H, Weirich G, Brieger J, et al. VHL alterations in human clear cell renal cell carcinoma: association with advanced tumor stage and a novel hot spot mutation. *Cancer Res.* 2000;60:1942-1948.
  22. Svastova E, Zilka N, Zat'ovicova M, et al. Carbonic anhydrase IX reduces E-cadherin-mediated adhesion of MDCK cells via interaction with beta-catenin. *Exp Cell Res.* 2003;290:332-345.
  23. Oosterwijk E, Divigi CR, Brouwers A, et al. Monoclonal antibody-based therapy for renal cell carcinoma. *Urol Clin North Am.* 2003;30:623-631.
  24. Grabmaier K, Vissers JL, De Weijert MC, et al. Molecular cloning and immunogenicity of renal cell carcinoma-associated antigen G250. *Int J Cancer.* 2000;85:865-870.
  25. Bui MH, Seligson D, Han KR, et al. Carbonic anhydrase IX is an independent predictor of survival in advanced renal clear cell carcinoma: implications for prognosis and therapy. *Clin Cancer Res.* 2003;9:802-811.
  26. Mulders PF, De Mulder PH. The role of adjuvant immunotherapy in renal cell carcinoma. *Curr Urol Rep.* 2002;3:44-49.
  27. Bui MH, Visapaa H, Seligson D, et al. Prognostic value of carbonic anhydrase IX and Ki67 as predictors of survival for renal clear cell carcinoma. *J Urol.* 2004;171(6 pt 1):2461-2466.
  28. Yildiz E, Gokce G, Kilicaslan H, et al. Prognostic value of the expression of Ki-67, CD44 and vascular endothelial growth factor, and microvessel invasion, in renal cell carcinoma. *BJU Int.* 2004;93:1087-1093.
  29. Brown DC, Gatter KC. Monoclonal antibody Ki-67: its use in histopathology. *Histopathology.* 1990;17:489-503.
  30. Rioux-Leclercq N, Turlin B, Bansard J, et al. Value of immunohistochemical Ki-67 and p53 determinations as predictive factors of outcome in renal cell carcinoma. *Urology.* 2000;55:501-505.
  31. Visapaa H, Bui M, Huang Y, et al. Correlation of Ki-67 and gelsolin expression to clinical outcome in renal clear cell carcinoma. *Urology.* 2003;61:845-850.
  32. Moch H, Schraml P, Bubendorf L, et al. High-throughput tissue microarray analysis to evaluate genes uncovered by cDNA microarray screening in renal cell carcinoma. *Am J Pathol.* 1999;154:981-986.
  33. Shvarts O, Seligson D, Lam J, et al. p53 is an independent predictor of tumor recurrence and progression after nephrectomy in patients with localized renal cell carcinoma. *J Urol.* 2005;173:725-728.
  34. Paul R, Necknig U, Busch R, et al. Cadherin-6: a new prognostic marker for renal cell carcinoma. *J Urol.* 2004;171:97-101.
  35. Morell-Quadreny L, Rubio J, Lopez-Guerrero JA, et al. Disruption of basement membrane, extracellular matrix metalloproteinases and E-cadherin in renal-cell carcinoma. *Anticancer Res.* 2003;23:5005-5010.
  36. Markovic-Lipkovski J, Brasanac D, Muller GA, et al. Cadherins and integrins in renal cell carcinoma: an immunohistochemical study. *Tumori.* 2001;87:173-178.
  37. Kim HL, Zisman A, Han KR, et al. Prognostic significance of venous thrombus in renal cell carcinoma: are renal vein and inferior vena cava involvement different? *J Urol.* 2004;171(2 pt 1):588-591.
  38. Zisman A, Wieder JA, Pantuck AJ, et al. Renal cell carcinoma with tumor thrombus extension: biology, role of nephrectomy and response to immunotherapy. *J Urol.* 2003;169:909-916.
  39. Rabbani F, Hakimian P, Reuter VE, et al. Renal vein or inferior vena caval extension in patients with renal cortical tumors: impact of tumor histology. *J Urol.* 2004;171:1057-1061.
  40. Naitoh J, Kaplan A, Dorey F, et al. Metastatic renal cell carcinoma with concurrent inferior vena caval invasion: long-term survival after combination therapy with radical nephrectomy, vena caval thrombectomy and post-operative immunotherapy. *J Urol.* 1999;162:46-50.
  41. Hatcher PA, Anderson EE, Paulson DF, et al. Surgical management and prognosis of renal cell carcinoma invading the vena cava. *J Urol.* 1991;145:20-23.
  42. Montie JE, El Ammar R, Pontes JE, et al. Renal cell carcinoma with inferior vena cava tumor thrombi. *Surg Gynecol Obstet.* 1991;173:107.
  43. Neves RJ, Zincke H. Surgical treatment of renal cancer with vena cava extension. *Br J Urol.* 1987;59:390-395.
  44. Blute ML, Leibovich BC, Lohse CM, et al. The Mayo Clinic experience with surgical management, complications and outcome for patients with renal cell carcinoma and venous tumour thrombus. *BJU Int.* 2004;94:33-41.
  45. Quek ML, Stein JP, Skinner DG. Surgical approaches to venous tumor thrombus. *Semin Urol Oncol.* 2001;19:88-97.
  46. Skinner DG, Pritchett JR, Lieskovsky G, et al. Vena caval involvement by renal cell carcinoma. Surgical resection provides meaningful long-term survival. *Ann Surg.* 1989;210:387-392.
  47. Novick AC, Kaye MC, Cosgrove DM, et al. Experience with cardiopulmonary bypass and deep hypothermia circulatory arrest in the management of retroperitoneal tumors with a large vena caval thrombus. *Ann Surg.* 1990;212:472-477.
  48. Thrasher JB, Paulson DF. Prognostic factors in renal cancer. *Urol Clin North Am.* 1993;20:247-262.
  49. Swierzewski DJ, Swierzewski MJ, Libertino JA. Radical nephrectomy in patients with renal cell carcinoma with venous, vena, caval, and atrial extension. *Am J Surg.* 1994;168:205-209.
  50. Parekh DJ, Cookson MS, Chapman W, et al. Renal cell carcinoma with renal vein and inferior vena caval involvement: clinicopathological features, surgical techniques and outcomes. *J Urol.* 2005;173:1897-1902.
  51. Angermeier KW, Novick AC, Strem SB, et al. Nephron-sparing surgery for renal cell carcinoma with venous involvement. *J Urol.* 1990;144:1352-1355.
  52. Sengupta S, Zincke H, Leibovich BC, et al. Surgical treatment of stage pT3b renal cell carcinoma in solitary kidneys: a case series. *BJU Int.* 2005;96:54-57.
  53. Pritchett TR, Lieskovsky G, Skinner DG. Extension of renal cell carcinoma into the vena cava: clinical review and surgical approach. *J Urol.* 1986;135:460-464.
  54. Langenbuch C. Chirurgie der leber und gallenblase [in German]. *Dtsche Chir.* 1894;45C:1.
  55. Skinner DG, Pfister RF, Colvin R. Extension of renal cell carcinoma into the vena cava: the rationale for aggressive surgical management. *J Urol.* 1972;107:711-716.
  56. Vaislic C, Puel P, Grondin P, et al. Cancer of the kidney invading the vena cava and the heart. Results after 11 years of treatment. *J Thorac Cardiovasc Surg.* 1986;91:604-609.
  57. Marshall FF, Reitz BA, Diamond DA. A new technique for management of renal cell carcinoma involving the right atrium: hypothermia and cardiac arrest. *J Urol.* 1984;131:103-107.
  58. Marshall VF, Middleton RG, Holswade GR, et al. Surgery for renal cell carcinoma in the vena cava. *J Urol.* 1970;103:414-420.
  59. Stewart JR, Carey JA, McDougal WS, et al. Cavoatrial tumor thrombectomy using cardiopulmonary bypass without circulatory arrest. *Ann Thorac Surg.* 1991;51:717-721.
  60. Viljoen JF, Thangathurai D. Anesthetic management in radical surgery for urologic malignancies. In: Skinner DJ, Lieskovsky G, eds. *Diagnosis and Management of Genitourinary Cancer.* Philadelphia, Pa: WB Saunders Co; 1988:595-600.
  61. Treiger BF, Humphrey LS, Peterson CV Jr, et al. Transesophageal echocardiography in renal cell carcinoma: an accurate diagnostic technique for intracaval neoplastic extension. *J Urol.* 1991;145:1138-1140.
  62. Kearney GP, Waters WB, Klein LA, et al. Results of inferior vena cava resection for renal cell carcinoma. *J Urol.* 1981;125:769-773.

63. Montie JE, el Ammar R, Pontes JE, et al. Renal cell carcinoma with inferior vena cava thrombi. *Surg Gynecol Obstet.* 1991;173:107-115.
64. Caldarelli G, Minervini A, Guerra M, et al. Prosthetic replacement of the inferior vena cava and the iliofemoral vein for urologically related malignancies. *BJU Int.* 2002;90:368-374.
65. Marshall FF, Reitz BA. Supradiaphragmatic renal cell carcinoma tumor thrombus: indications for vena caval reconstruction with pericardium. *J Urol.* 1985;133:266-268.
66. Ciancio G, Soloway M. Resection of the abdominal inferior vena cava for complicated renal cell carcinoma with tumour thrombus. *BJU Int.* 2005;96:815-818.
67. Robson CJ, Churchill BM, Anderson W. The results of radical nephrectomy for renal cell carcinoma. *J Urol.* 1969;101:297-301.
68. Blom JH, van Poppel H, Marechal JM, et al. The EORTC Genitourinary Group. Radical nephrectomy with and without lymph node dissection: preliminary results of the EORTC randomized phase III protocol 30881. *Eur Urol.* 1999;36:570-575.
69. Blute ML, Leibovich BC, Cheville JC, et al. A protocol for performing extended lymph node dissection using primary tumor pathological features for patients treated with radical nephrectomy for clear cell renal cell carcinoma. *J Urol.* 2004;172:465-469.
70. Studer UE, Scherz S, Scheidegger J, et al. Enlargement of regional lymph nodes in renal cell carcinoma is often not due to metastases. *J Urol.* 1990;144(2 pt 1):243-245.
71. Minervini A, Lilas L, Morelli G, et al. Regional lymph node dissection in the treatment of renal cell carcinoma: is it useful in patients with no suspected adenopathy before or during surgery? *BJU Int.* 2001;88:169-172.
72. Vasselli JR, Yang JC, Linehan WM, et al. Lack of retroperitoneal lymphadenectomy predicts survival of patients with metastatic renal cell carcinoma. *J Urol.* 2001;166:68-72.
73. Johnsen JA, Hellsten S. Lymphogenous spread of renal cell carcinoma: an autopsy study. *J Urol.* 1997;157:450-453.
74. Pantuck AJ, Zisman A, Dorey F, et al. Renal cell carcinoma with retroperitoneal lymph nodes: role of lymph node dissection. *J Urol.* 2003;169:2076-2083.
75. Canfield SE, Kamat AM, Sanchez-Ortiz RF, et al. Renal cell carcinoma with nodal metastases in the absence of distant metastatic disease (clinical stage TxN1-2M0): the impact of aggressive surgical resection on patient outcome. *J Urol.* 2006;175(3 pt 1):864-869.
76. Ward JF, Blute ML, Cheville JC, et al. The influence of pNx/pN0 grouping in a multivariate setting for outcome modeling in patients with clear cell renal cell carcinoma. *J Urol.* 2002;168:56-60.
77. deKernion JB, Ramming KP, Smith RB. Natural history of metastatic renal cell carcinoma: a computer analysis. *J Urol.* 1978;120:148-152.
78. Almgard LE, Fernstrom I, Haverling M, et al. Treatment of renal adenocarcinoma by embolic occlusion of the renal circulation. *Br J Urol.* 1973;45:474-479.
79. Zielinski H, Szmigielski S, Petrovich Z. Comparison of preoperative embolization followed by radical nephrectomy with radical nephrectomy alone for renal cell carcinoma. *Am J Clin Oncol.* 2000;23:6-12.
80. Bono AV, Caresano A. The role of embolization in the treatment of kidney carcinoma. *Eur Urol.* 1983;9:334-337.
81. Mebust WK, Weigel JW, Lee KR, et al. Renal cell carcinoma: angiinfarction. *J Urol.* 1984;131:231-235.
82. Jennings SB, Austenfeld MS, Basham K. Fatal pulmonary embolus from ischemic necrosis of intra-caval tumor thrombus: a case report. *J Urol.* 1993;150(5 pt 1):1492-1495.
83. Lammer J, Justich E, Schreyer H, et al. Complications of renal tumor embolization. *Cardiovasc Intervent Radiol.* 1985;8:31-35.
84. Ciancio G, Vaidya A, Soloway M. Early ligation of the renal artery using the posterior approach: a basic surgical concept reinforced during resection of large hypervascular renal cell carcinoma with or without inferior vena cava thrombus. *BJU Int.* 2003;92:488-489.
85. Stein M, Kuten A, Halpern J, et al. The value of postoperative irradiation in renal cell cancer. *Radiother Oncol.* 1992;24:41-44.
86. Gez E, Libes M, Bar-Deroma R, et al. Postoperative irradiation in localized renal cell carcinoma: the Rambam Medical Center experience. *Tumori.* 2002;88:500-502.
87. Kjaer M, Frederiksen PL, Engelholm SA. Postoperative radiotherapy in stage II and III renal adenocarcinoma: a randomized trial by the Copenhagen Renal Cancer Study Group. *Int J Radiat Oncol Biol Phys.* 1987;13:665-672.
88. Pizzocaro G, Piva L, Di Fronzo G, et al. Adjuvant medroxyprogesterone acetate to radical nephrectomy in renal cancer: 5-year results of a prospective randomized study. *J Urol.* 1987;138:1379-1381.
89. Yagoda A, Petrylak D, Thompson S. Cytotoxic chemotherapy for advanced renal cell carcinoma. *Urol Clin North Am.* 1993;20:303-321.
90. Motzer RJ, Russo P. Systemic therapy for renal cell carcinoma. *J Urol.* 2000;163:408-417.
91. Chapman AE, Goldstein LJ. Multiple drug resistance: biologic basis and clinical significance in renal-cell carcinoma. *Semin Oncol.* 1995;22:17-28.
92. Motzer RJ, Berg W, Ginsberg M, et al. Phase II trial of thalidomide for patients with advanced renal cell carcinoma. *J Clin Oncol.* 2002;20:302-306.
93. Stadler WM, Kuzel T, Shapiro C, et al. Multi-institutional study of the angiogenesis inhibitor TNP-470 in metastatic renal carcinoma. *J Clin Oncol.* 1999;17:2541-2545.
94. Braybrooke JP, O'Byrne KJ, Propper DJ, et al. A phase II study of razoxane, an antiangiogenic topoisomerase II inhibitor, in renal cell cancer with assessment of potential surrogate markers of angiogenesis. *Clin Cancer Res.* 2000;6:4697-4704.
95. Lee CP, Patel PM, Selby PJ, et al. Randomized phase II study comparing thalidomide with medroxyprogesterone acetate in patients with metastatic renal cell carcinoma. *J Clin Oncol.* 2006;24:898-903.
96. Le Francois D, Youn JK, Belehradek J Jr, et al. Evolution of cell-mediated immunity in mice bearing tumors produced by a mammary carcinoma cell line: influence of tumor growth, surgical removal, and treatment with irradiated tumor cells. *J Natl Cancer Inst.* 1971;46:981-987.
97. Whitney RB, Levy JG, Smith AG. Influence of tumor size and surgical resection on cell-mediated immunity in mice. *J Natl Cancer Inst.* 1974;53:111-116.
98. Gitlitz BJ, Figlin RA. Cell, gene and vaccine based strategies in kidney cancer. In: Figlin RA, ed. *Kidney Cancer: Cancer Treatment and Research.* Boston, Mass: Kluwer Academic Publishers; 2003:183-198.
99. Margolin K, Gordon MS, Holmgren E, et al. Phase Ib trial of intravenous recombinant humanized monoclonal antibody to vascular endothelial growth factor in combination with chemotherapy in patients with advanced cancer: pharmacologic and long-term safety data. *J Clin Oncol.* 2001;19:851-856.
100. Bukowski RM. Cytokine combinations: therapeutic use in patients with advanced renal cell carcinoma. *Semin Oncol.* 2000;27:204-212.
101. Messing EM, Manola J, Wilding G, et al. Eastern Cooperative Oncology Group/Intergroup trial. Phase III study of interferon alpha-NL as adjuvant treatment for resectable renal cell carcinoma: an Eastern Cooperative Oncology Group/Intergroup trial. *J Clin Oncol.* 2003;21:1214-1222.
102. Pizzocaro G, Piva L, Colavita M, et al. Interferon adjuvant to radical nephrectomy in Robson stages II and III renal cell carcinoma: a multicentric randomized study. *J Clin Oncol.* 2001;19:425-431.
103. Clark JI, Atkins MB, Urba WJ, et al. Adjuvant high-dose bolus interleukin-2 for patients with high-risk renal cell carcinoma: a cytokine working group randomized trial. *J Clin Oncol.* 2003;21:3133-3140.
104. Atzpodien J, Schmitt E, Gertenbach P, et al. Adjuvant treatment with interleukin-2 and interferon alpha-2-based chemioimmunotherapy in renal cell carcinoma post tumor nephrectomy: results of a prospectively randomized trial of the German Cooperative Renal Cell Carcinoma Chemioimmunotherapy Group (DGCIN). *Br J Cancer.* 2005;92:843-846.
105. Sawczuk IS, Graham SD Jr, Miesowicz F, et al. Randomized controlled trial of adjuvant therapy with ex vivo activated T cells (ALT) in T1-3a,b,c or T4N + M renal cell carcinoma. *Proc Annu Meet Am Soc Clin Oncol.* 1997;16:326a. Abstract.
106. Galligioni E, Quai M, Merlo A, et al. Adjuvant immunotherapy treatment of renal carcinoma patients with autologous tumor cells and bacillus Calmette-Guérin: five-year results of a prospective randomized study. *Cancer.* 1996;77:2560-2566.
107. Schwaab T, Tretter CP, Gibson JJ, et al. Immunological effects of granulocyte-macrophage colony-stimulating factor and autologous tumor vaccine in patients with renal cell carcinoma. *J Urol.* 2004;171:1036-1042.
108. Jocham D, Richter A, Hoffmann L, et al. Adjuvant autologous renal tumour cell vaccine and risk of tumour progression in patients with renal-cell carcinoma after radical nephrectomy: phase III, randomised controlled trial. *Lancet.* 2004;363:594-599.
109. Wood CG, Escudier B, Gorelov S, et al. A multicenter randomized study of adjuvant heat-shock protein peptide-complex 96 (HSPPC-96) vaccine in patients with high-risk of recurrence after nephrectomy for renal cell carcinoma (RCC): a preliminary report. *J Clin Oncol.* 2004;22(suppl):192S.
110. Assikis VJ, Daliani D, Pagliaro L, et al. Phase II study of an autologous tumor derived heat shock protein-peptide complex vaccine (HSPPC-96) for patients with metastatic renal cell carcinoma (mRCC). *Proc Annu Meet Am Soc Clin Oncol.* 2003;22:386s. Abstract.
111. Hoos A, Levey DL. Vaccination with heat shock protein-peptide complexes: from basic science to clinical applications. *Expert Rev Vaccines.* 2003;2:369-379.
112. Lam JS, Leppert JT, Belldegrun AS, et al. Adjuvant therapy of renal cell carcinoma: patient selection and therapeutic options. *BJU Int.* 2005;96:483-488.
113. Motzer RJ, Michaelson MD, Redman BG, et al. Activity of SU11248, a multitargeted inhibitor of vascular endothelial growth factor receptor and platelet-derived growth factor receptor, in patients with metastatic renal cell carcinoma. *J Clin Oncol.* 2006;24:16-24.
114. Ratain MJ, Eisen T, Stadler WM, et al. Phase II placebo-controlled randomized discontinuation trial of sorafenib in patients with metastatic renal cell carcinoma. *J Clin Oncol.* 2006;Apr 24. [Epub ahead of print].